

G. B.

g.

STONES & DISEASES
OF THE BILE-DUCTS

BLAND-SUTTON



22101733308

GALL-STONES AND DISEASES OF THE BILE-DUCTS

BY

J. BLAND-SUTTON, F.R.C.S.ENG.

SURGEON AND LECTURER ON SURGERY TO THE MIDDLESEX
HOSPITAL, AND MEMBER OF THE CANCER
INVESTIGATION COMMITTEE

WITH FIFTY-THREE ILLUSTRATIONS

NEW AND REVISED EDITION



London

JAMES NISBET & CO., LIMITED
22, BERNERS STREET, W.

1910

PRINTED BY ADLARD AND SON,
LONDON AND DORKING.



WELLCOME INSTITUTE LIBRARY	
Coll.	welMOmec
Call	
No.	WI 750
	1910
	B64g

PREFACE TO THE NEW EDITION

DURING the last five years our knowledge of the diseases of the gall-bladder and bile-ducts has undergone a complete change. Observations in the *post-mortem* room and in the operating theatre have led physicians and surgeons astray. The opinion that many diseases associated with gall-stones are due to infections ascending the bile-ducts from the alimentary canal has proved to be wide of the mark. Experimental pathology teaches that the liver is an organic filter as well as a laboratory. Many serious diseases of the bile-ducts are caused by infection from contaminating elements eliminated from the blood of the portal circulation and discharged into the outflowing bile. The majority of the disturbances which come under the surgeon's cognisance in connection with the canal-system of the liver are "descending infections."

The colonisation of the gall-bladder by the *Bacillus typhosus* is a frequent sequel of typhoid fever, and the discovery of "typhoid-carriers" has served to widen our view in regard to the origin of gall-stone disease.

Ten years ago primary cancer of the gall-bladder

was regarded as an uncommon disease, but the routine examination of gall-bladders removed during life appals us by revealing its frequency. Critical analysis of the clinical and pathological observations bearing on the association of cancer and gall-stones indicates that these two conditions are manifestations of a common cause. It strengthens the position of men who believe that cancer is due to a micro-parasite, and especially those who suspect that the infecting agent is admitted into the alimentary canal with food and water. So far as the excretory apparatus of the liver is concerned, the micro-parasite in the alimentary canal is conveyed to the liver by the portal circulation ; it is then excreted and carried by the bile to the gall-bladder, where it infects and stimulates the epithelium to unnatural growth. This new knowledge is set forth in this new edition.

JOHN BLAND-SUTTON.

47, BROOK STREET,
LONDON, 1910.

PREFACE TO THE FIRST EDITION

THIS little book consists of a series of lectures delivered at the Middlesex Hospital. I venture to publish them because I am under the impression that cholelithiasis is inadequately considered in textbooks of surgery, and the available English monographs on this subject have grown too big to be useful for students.

Since Tait's pioneer operation (1876) the literature relating to the operative treatment of gall-stones has become bewildering in its magnitude: in spite of this activity many sufferers from cholelithiasis find their way into the deadhouse with their disease unrecognised and unrelieved. I do not contend that surgery is unerring in relieving "gall-stone patients," for in the last chapter will be found a statistical record (gathered from returns kindly furnished me by the Registrars) of operations performed for the relief of gall-stones in the general hospitals of London during 1905. This record shows that, even with the assistance of "asepsis," operations on the gall-bladder and bile-ducts cannot be described as free from risk.

1907.



Digitized by the Internet Archive
in 2019 with funding from
Wellcome Library

<https://archive.org/details/b31346959>

CONTENTS

CHAPTER	PAGE
I. THE BILE-DUCTS AND THE BILE	1
II. TYPHOID INFECTION OF THE GALL-BLADDER	17
III. INFECTIONS OF THE BILE-DUCTS AND GALL- BLADDER (CHOLANGITIS AND CHOLE- CYSTITIS)	23
IV. CONGENITAL OBLITERATION OF THE EX- CRETORY APPARATUS OF THE LIVER .	41
V. GALL-STONES : THEIR FORM, STRUCTURE, COMPOSITION, AND MODE OF FORMATION	50
VI. THE PATHOLOGIC CONSEQUENCES OF GALL- STONES	67
VII. THE CHANGES GALL-STONES PRODUCE IN THE BILE-DUCTS	90
VIII. INTESTINAL OBSTRUCTION FROM GALL- STONES (GALL-STONE ILEUS)	107
IX. CYSTS ARISING FROM THE INTRAHEPATIC BILE-DUCTS	121
X. EPITHELIAL TUMOURS OF THE GALL- BLADDER AND BILE-DUCTS	130

CHAPTER	PAGE
XI. THE EFFECTS OF SOME FORMS OF PANCREATIC DISEASE ON THE EXCRETORY APPARATUS OF THE LIVER	149
XII. THE SYMPTOMS, SIGNS, AND DIAGNOSIS OF CHOLELITHIASIS	164
XIII. DIFFERENTIAL DIAGNOSIS OF CHOLELITHIASIS	182
XIV. TREATMENT OF CHOLELITHIASIS	192
XV. OPERATIONS ON THE EXCRETORY APPARATUS OF THE LIVER	201
XVI. OPERATIONS ON THE EXCRETORY APPARATUS OF THE LIVER (<i>continued</i>)	212
XVII. OPERATIONS ON THE COMMON BILE-DUCT	224
XVIII. AFTER-TREATMENT, RISKS; AND SEQUELÆ OF GALL-STONE OPERATIONS	232
XIX. INJURIES OF THE GALL-BLADDER AND BILE-DUCTS	242
XX. THE MORTALITY OF OPERATIONS PERFORMED FOR THE RELIEF OF GALL-STONE DISEASE	247
INDEX	251

ON GALL-STONES AND DISEASES OF THE BILE-DUCTS

CHAPTER I

THE BILE-DUCTS AND THE BILE

IN every chemical industry there are waste products, and great ingenuity is often exercised in order that they may be disposed of easily, economically, and, as a rule, with a minimum amount of annoyance to those engaged in the manufactory. Every organ in the body of an animal may be regarded as a chemical factory, and the waste product may be a gas (carbon dioxide), or a fluid (urine), or solid matter (fæces). The greatest of all the laboratories in the bodies of vertebrata is the liver, for it receives the blood conveyed to it by the portal vein, which is charged with the products of digestion, such as carbohydrates, and various proteids which it obtains from the gastro-intestinal tract. The portal vein is

also the channel by which micro-parasites (such as amœbæ, echinococcus-embryos and flukes), bacteria and their toxins from the intestines, are conveyed to the liver.

Experimental physiology has taught us that the chief function of the liver is the production of a peculiar substance termed "glycogen," whilst bile appears as a waste or excrementitious product.

As surgeons we are not particularly concerned with glycogen, although it is a substance of the most profound interest to the physician in regard to the disease known as diabetes ; but physicians and surgeons are often concerned with irregularities connected with the escape of the bile, which takes place by means of an elaborate system of passages in the recesses of the liver, and convey the bile from its source in the hepatic cells to be discharged into the duodenum.

A large amount of ingenious histologic investigation has been expended with the hope of determining the exact manner in which the bile-passages come into relation with the hepatic cells : although the matter has not been precisely determined, it is quite certain that they arise in the most intimate association with the hepatic cells, and become obvious to the microscope as minute intercellular passages (bile canaliculi), which communicate with the bile-ducts ramifying in the interlobular connective tissue. The bile-ducts around the lobules possess connective-

tissue walls and are lined with short columnar epithelium, but in the portal canals the ducts are larger and the coats contain areolar tissue and plain muscle-fibres ; the epithelium is columnar (Fig. 1). The bile-ducts converge to the portal fissure, and, enlarging as they become confluent, issue as the right and the left hepatic duct respectively : these

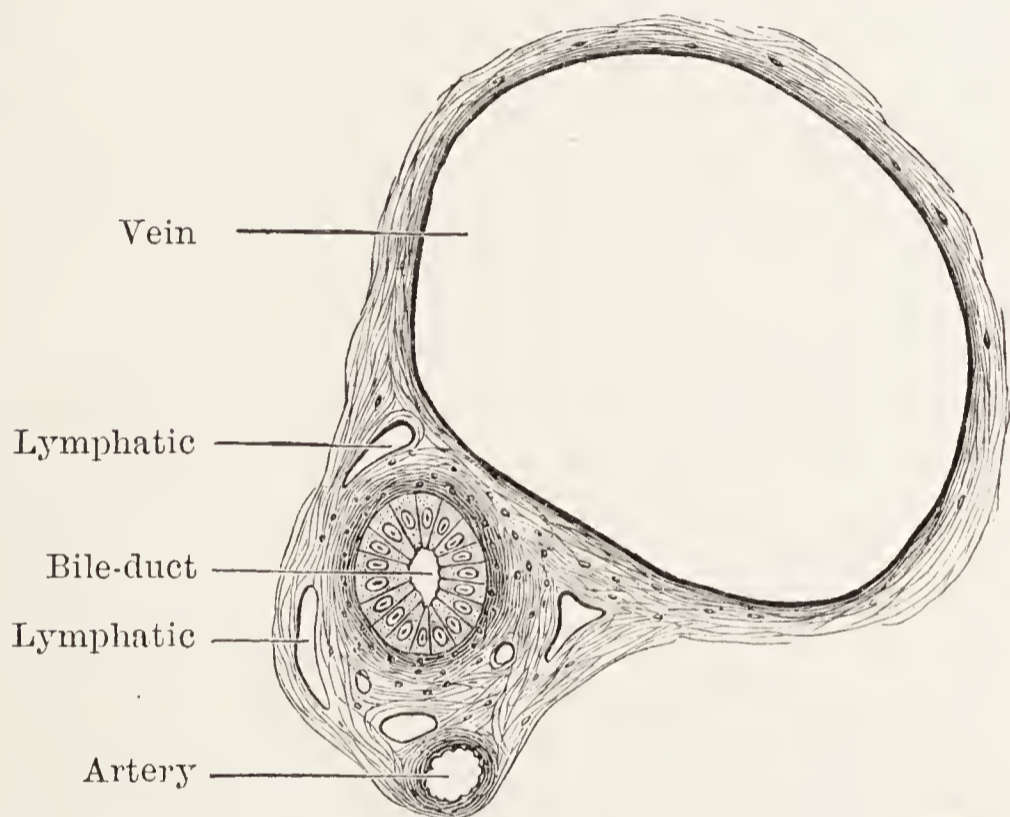


FIG. 1.—Transverse section of a portal canal. (After Schäfer.)

conjoin to form the hepatic duct which issues from the transverse fissure of the liver and receives the cystic duct descending from the gall-bladder ; together they form the common bile-duct which opens into the second part of the duodenum. The large ducts and the gall-bladder constitute the excretory apparatus of the liver and are of such importance that each will require detailed description.

The excretory apparatus of the liver.—This consists

of the hepatic duct, the cystic duct, the gall-bladder, and the common bile-duct (Fig. 2).

The hepatic duct, formed by the union of the

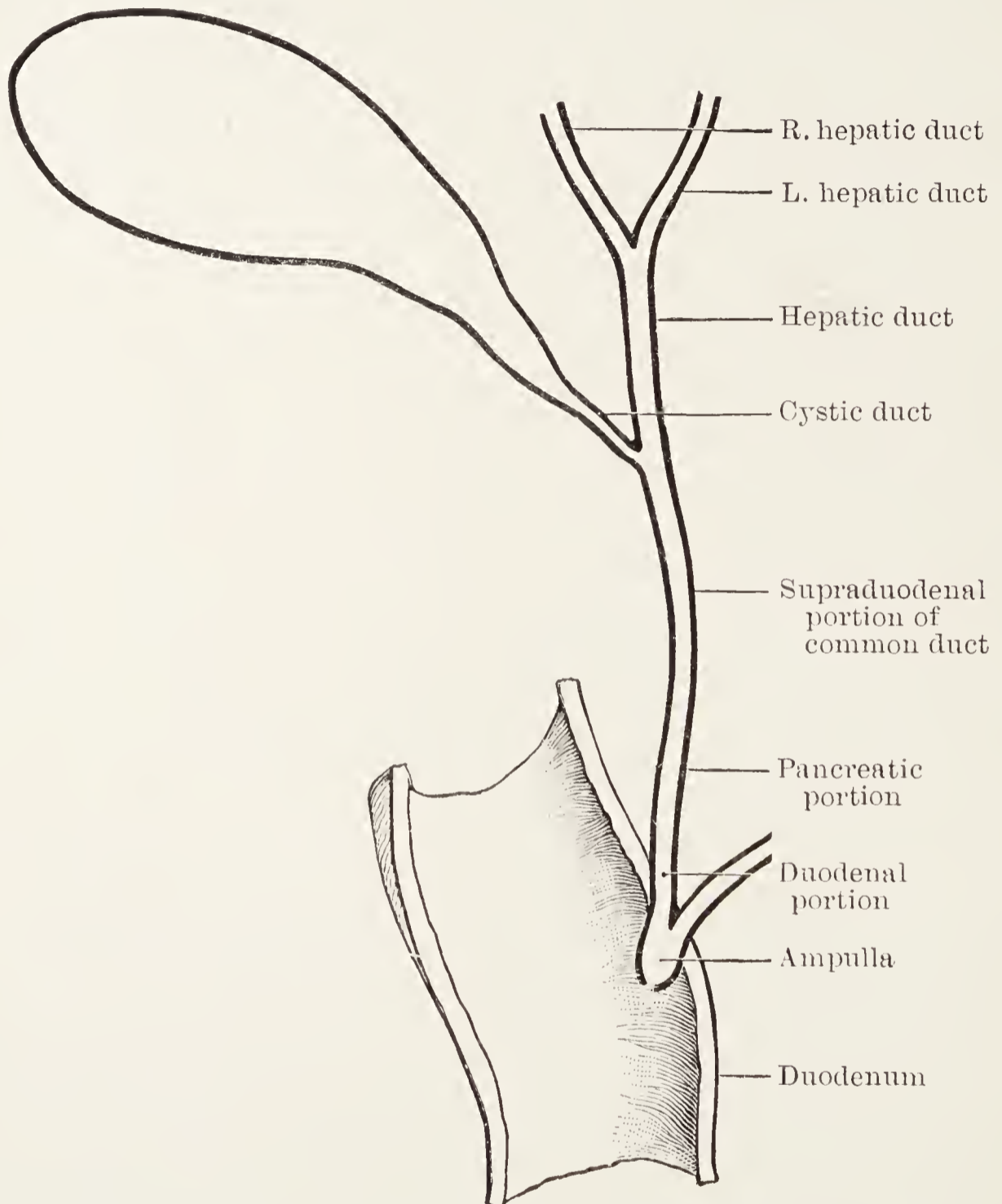


FIG. 2.—A diagram representing the relationship of the ducts which constitute the excretory apparatus of the liver.

right and left hepatic duct, has an average diameter of 4 mm., and in length varies from 3 to 5 cm. It lies in front of the portal vein between the folds of the gastro-hepatic omentum.

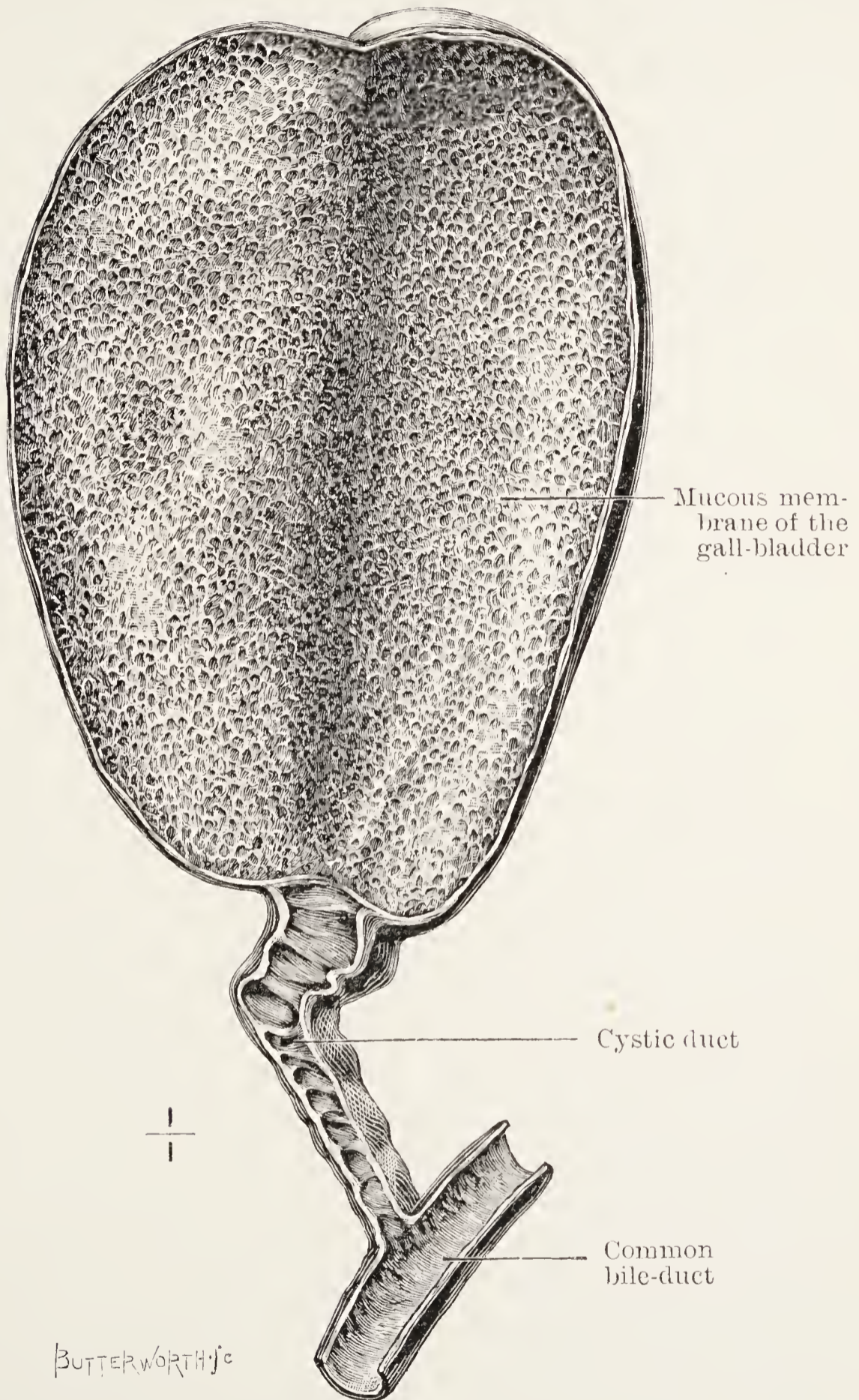


FIG. 3.—The gall-bladder opened to show the depressions in its mucous membrane and the valvular folds in the cystic duct. (After Kehr.)

The gall-bladder.—The gall-bladder is a pyriform sac lodged in a fossa on the under surface of the right lobe of the liver, and holds under normal conditions about an ounce and a half (40 c.c.) of fluid. When distended its fundus projects beyond the anterior border of the liver, whilst its narrow end or neck is directed towards the transverse fissure. The under surface of the gall-bladder is covered by the peritoneum which invests the under surface of the liver, and its fundus is covered completely with peritoneum. The extent to which the gall-bladder is invested by peritoneum varies, and in some instances the greater part of it is covered and the organ slung to the under surface of the liver by a mesentery.

The gall-bladder is supplied by the cystic artery, a branch of the right division of the hepatic artery: the cystic veins open into the portal vein. Its nerves are derived from the cœliac plexus.

The gall-bladder possesses a muscular and connective-tissue coat: the muscular fibres in the main run a longitudinal course but some have a circular or transverse direction. It is lined with mucous membrane which presents numerous depressions or alveoli, and on the floor of the larger alveoli the orifices of mucous recesses may be seen (Fig. 3). The epithelium lining the gall-bladder is columnar. The narrow portion or neck of the gall-bladder forms an **S**-shaped curve as it joins the cystic duct (Fig. 5). The termination of the gall-bladder and the begin-

ning of the cystic duct is indicated by a well-marked fold or valve of mucous membrane.

The cystic duct.—This duct, 3 cm. long and 2–3 mm. in diameter, intervenes between the neck of the gall-bladder and the hepatic duct. It is structurally a continuation of the neck of the gall-bladder, and contains valvular folds of mucous membrane (valves of Heister). The cystic joins the hepatic duct at an acute angle, and their confluence marks the beginning of the common bile-duct.

*The common bile-duct (ductus communis chole-
dochus).*—The common bile-duct (practically a continuation of the hepatic duct beyond the point of entrance of the cystic duct) is about 7.5 cm. (3 in.) in length, and 5 mm. wide, and passes between the layers of the gastro-hepatic omentum in front of the portal vein and to the right of the hepatic artery. It passes behind the first part of the duodenum, and descending behind the second part of the duodenum comes into close relation with the head of the pancreas to form a junction with the pancreatic duct. The confluent, but not inosculating ducts together pierce the duodenal wall, and after running obliquely through its coats for nearly 2 cm. and forming a low ridge beneath the mucous membrane, terminate in an ampulla (or diverticulum of Vater). The common bile-duct is an elongated funnel, with its mouth at the junction of the cystic and hepatic ducts and the narrow end at the ampulla.

The ampulla.—This diverticulum (of Vater) as it is often called, occupies the base of a papilla situated in the mucous membrane on the posterior aspect of the second part of the duodenum, 8 cm. from the pyloric orifice of the stomach. This papilla projects

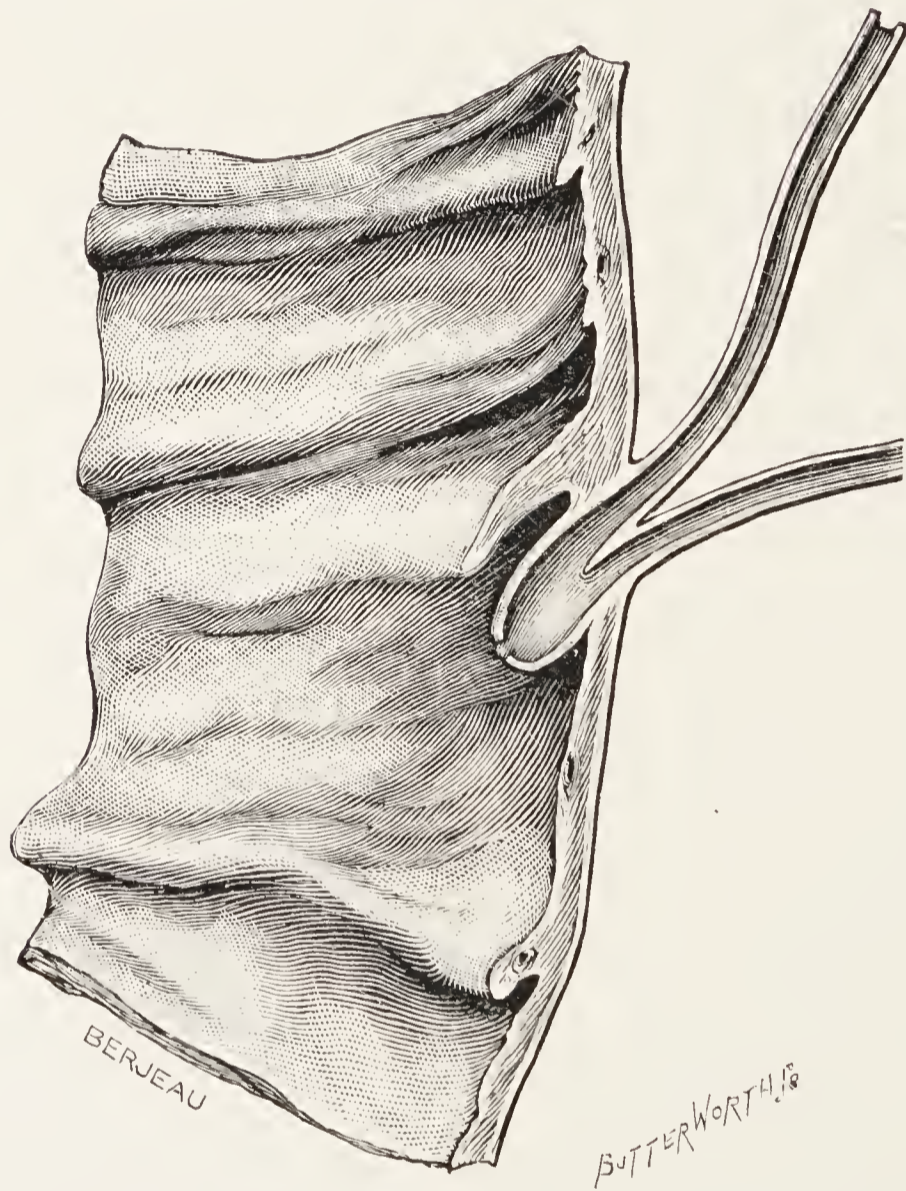


FIG. 4.—The ampulla with the termination of the common bile-duct and the pancreatic duct. (After Tuffier.)

from the duodenal mucous membrane, and resembles very much the lacrimal caruncle; it is sheltered by an eyelid-like valvula of mucous membrane (Fig. 4), and opens into the duodenum by an orifice about 3 mm. in diameter. This terminal orifice is the narrowest part of the excretory apparatus. When

distended the ampulla is ovoid, and about 6 mm. long and 4 mm. wide.

The chief variations connected with the terminal section of the duct are these :

The common bile-duct and the pancreatic duct may terminate independently. The papilla indicating the ampulla may be absent and the ducts open at the bottom of a depression in the mucous membrane. Even when the ducts open separately the papilla may be present, the ducts opening independently near its base.

An interesting morphologic anomaly consists in the pancreatic duct opening on the papilla in the normal position, but the bile-duct associates itself with the duct of an accessory pancreas (Santorini's).

The relations of the common bile-duct to the adjacent organs are of great practical importance to the surgeon. Quénu suggested that it is convenient to divide it for descriptive purposes and clinical reference into three portions :

(1) The supraduodenal portion (3·5 cm.).

(2) The pancreatic (or retroduodenal) portion (2·5 cm.).

(3) The duodenal (infraduodenal) or terminal portion (1·5 cm.).

The supraduodenal portion extends from the junction of the cystic duct to the point where the common duct comes into relation with the pancreas. This part lies in the gastro-hepatic omentum and is in relation with the foramen of Winslow. It re-

10 DISEASES OF THE BILE-DUCTS

presents nearly half the total length of the duct, and is crossed near its termination by a twig of the pancreatico-duodenal artery; occasionally this is a large vessel (Quénu).

The pancreatic portion usually occupies a tunnel in the head of the pancreas: in some cases it is merely a groove.

The terminal segment lies in the wall of the

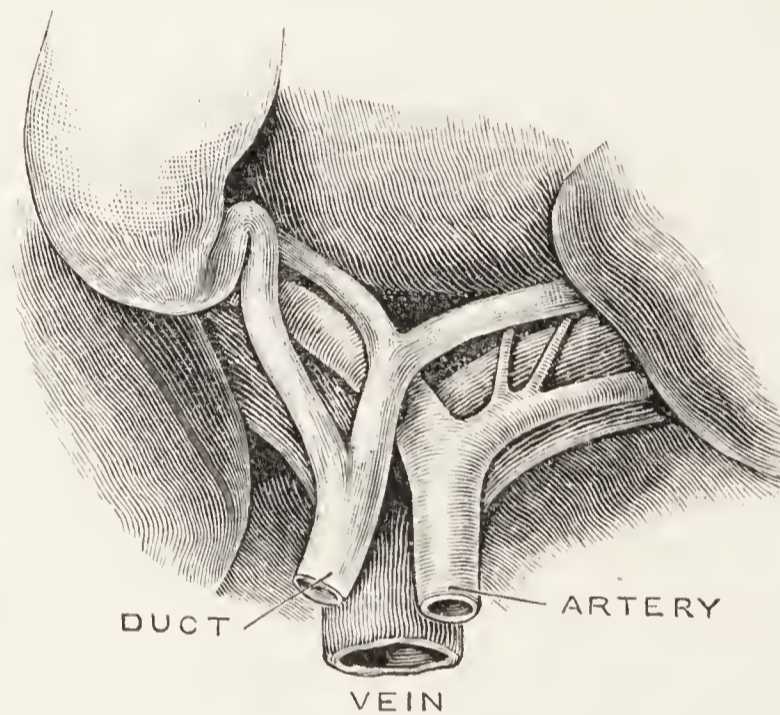


FIG. 5.—The relations of the bile-ducts, portal vein, and hepatic artery at the porta hepatica.

duodenum and opens into the ampulla, save in the instances when this diverticulum is absent, then it may open on the free surface of the duodenal mucous membrane: it is the shortest segment.

It will be seen on reference to the diagram (Fig. 2) that the cystic duct with the gall-bladder may be regarded from the anatomic point of view as a diverticulum from the main bile-duct.

In considering the anatomy of these ducts it is

important to remember that they are imbedded in areolar tissue, which often contains a large amount of fat, and they are in close relation with the main trunk of the portal vein and the hepatic artery; numerous small blood-vessels ramify on the walls of the ducts, as well as sympathetic nerve-twigs of some size derived from the cœliac plexus, including the terminal twigs of the left vagus nerve. The fat in which these ducts, nerves, and blood-vessels are imbedded also contains several lymph-nodes.

Abnormalities of the gall-bladder.—The chief of these are connected with complete transposition of viscera. In this condition the liver lies mainly in the left hypochondrium; the left lobe is then larger than the right, and lodges the gall-bladder; the duodenum and stomach are also reversed. I have met with transposition of the viscera once in the course of 3000 cœliotomies performed during the last twenty years. In one case of transposition of viscera the patient suffered from gall-stones and cholecystotomy was performed on the left side. The abnormal arrangement of the viscera was recognised before operation (Beck).

Absence of the gall-bladder.—It is curious, seeing that this receptacle is very inconstant in mammals and birds, that it should be so constant in man, for absence of the gall-bladder is a very rare anomaly. It is absent in the horse, ass, and deer: its variability is well expressed among birds, for many of the class

Aves lack it, and even in the same family—as, for example, the parrots—some members possess and others lack a gall-bladder.

The fundus of the gall-bladder may be bifid, and this variation may be so marked that the gall-bladder has been found duplicated.

In one case each gall-bladder possessed a separate cystic duct; one opened into the hepatic duct (Purser). Apart from cases of transposition of viscera the gall-bladder has been found on the under surface of the left lobe of the liver (Kehr, Rolleston).

The gall-bladder is sometimes constricted in the middle and assumes an hour-glass shape. This is not uncommon when it is occupied by gall-stones, and the anomaly is probably rarely seen independently of chronic calculous cholecystitis.

BILE.

The colour of healthy human bile in the common duct as seen in the course of an operation is a bright golden red; after retention in the gall-bladder it becomes green. The sojourn of the bile in the gall-bladder alters its quality as well as its colour, mainly by the admixture of mucus. The reaction of bile is neutral or faintly alkaline.

Foster gives the average composition of bile taken from the gall-bladder as :

Water in 1000 parts	859·2
Bile-salts	91·4
Fats	9·2
Cholesterin	2·6
Mucus and pigment	29·8
Inorganic salts	7·8
	——— 140·8

The most marked feature is the absence of proteids.

Among the solid constituents of bile, surgeons are particularly interested in cholesterin and the bile-pigments.

Cholesterin ($C_{26}H_{44}O$) or ($C_{26}H_{43}OH$).—This peculiar substance, sometimes called “bile-fat,” a monatomic alcohol, forms the greater part of most gall-stones. Insoluble in water and cold alcohol, soluble in hot alcohol, ether, and chloroform, it is dissolved by the bile-salts (*sodium glycocholate and taurocholate*), hence it is present in solution in bile. A solution of cholesterin in chloroform gently shaken with an equal amount of concentrated sulphuric acid, turns red and ultimately purple; the subjacent acid acquires a green fluorescence (*Salkowski's reaction*).

Pigments of bile.—The golden red of normal human bile is due to *bilirubin*: it may be obtained from the urine of jaundiced persons as an amorphous orange-coloured powder, or in well-formed rhombic tablets and prisms. Insoluble in water, it is readily soluble in chloroform and alkaline fluids.

When treated with oxidising agents, such as nitric acid yellow with nitrous acid, it displays a succession of colours in the order of the spectrum. Thus from red it becomes green, blue, violet, and finally yellow. This is the basis of the familiar Gmelin's test for bile-pigment. An alkaline solution of bilirubin exposed in a shallow vessel to air becomes green from conversion into biliverdin. This is probably the body which gives to bile which has been exposed to the action of the gastric juice its characteristic green hue.

Functions of the bile.—These are few and unimportant: bile, like urine, is excrementitious. Bile being in the main alkaline, it tends to neutralise the acid contents of the stomach as they pass into the duodenum. It renders, when in sufficient quantity, gastric juice inert towards proteids. Bile has a slight solvent action on fat, and it seems to have greater emulsive action when mixed with pancreatic juice than when acting alone: it probably has some antiseptic property, for when bile is hindered from flowing into the intestine the colon becomes loaded with clay-coloured fæces which yield very offensive gases. The opinion that bile is merely excrementitious is supported by the observation that the whole of the bile may escape through an external fistula and the person's health in no way suffers, though the fistula persists for several years.

The secretion and discharge of bile.—The secretion

of bile appears to be continuous but not uniform, and this applies to its discharge into the duodenum.

The rate of secretion is influenced by food, and appears to rise rapidly after food. When the stomach is empty the bile passes along the hepatic duct and enters the cystic duct, to be stored in the gall-bladder. During fasting the gall-bladder fills. When the contents of the stomach enter the duodenum and run over the bile papilla, bile gushes out: this rush is due to the contraction of the muscular walls of the gall-bladder accompanied by a relaxation of the sphincter at the orifice of the common duct: after the gall-bladder has discharged its contents for a time the bile from the liver runs a direct course from the hepatic through the common duct to the duodenum. When the digestive excitement subsides bile may drip into the duodenum, but the main current runs through the cystic duct to the gall-bladder. About a litre (1.76 pints) is secreted in twenty-four hours.

The pressure under which bile is secreted is lower than the arterial pressure: this may be attributed to the fact that it is secreted from the venous blood in the portal system, so it is probable that the pressure exerted by the secretion is higher than that in the blood-vessels feeding the secreting cells. When from any cause, such as gall-stones, tumours, stricture, etc., the main duct is obstructed, the pressure in the bile-ducts will rise until resorption takes place,

and the bile finds its way into the blood, causing jaundice. The bile under such pressure finds its way into the portal lymphatics and is carried into the thoracic duct and thence enters the bloodstream.

When carmine gelatine is injected into the bile-ducts at a pressure not exceeding the maximum pressure of the bile, the injected material appears in the lymphatics of the liver. The bile probably escapes through the intra-cellular plasmatic cells described by Schäfer, and these channels may be regarded as an intermediate system linking the blood-vessels of the liver with the lymphatics at the periphery of the lobules (Herring and Simpson).

REFERENCES.

- Beck, C.**, "A Case of Transposed Viscera, with Cholelithiasis, relieved by a Left-sided Cholecystotomy."—*Annals of Surgery*, 1899, xxix, p. 593.
- Herring, P. T.**, and **Simpson, S.**, "The Pressure of Bile-secretion and the Mechanism of Bile-absorption in Obstruction of the Bile-duct."—*Proc. Roy. Soc.*, 1907, Series B, lxxix, p. 517.
- Purser, J. M.**, "Case of a Liver with two Gall-bladders."—*Trans. Acad. Med.*, Ireland, 1887, v, p. 243.
- Quénu**, "Note sur l'Anatomie du Cholédoque, à un Point de vue Chirurgical."—*Revue de Chirurgie*, 1895, xv, p. 568.

CHAPTER II

TYPHOID INFECTION OF THE GALL- BLADDER

THE liver, in addition to its glycogenic function, may be regarded as a great organic filter, which separates not only toxins from the blood conveyed to it by the portal vein, but also micro-organisms which enter the portal circulation from the gastro-intestinal tract.

The elimination of micro-organisms by the liver is capable of experimental proof. Welch (1891) found that when a culture of the typhoid bacillus was injected into the venous circulation of a rabbit, the bacilli appeared in the bile five days later. The bacilli have been found in the bile of a rabbit one hundred and twenty-eight days after an intra-venous injection. These results have been confirmed by subsequent investigators (Lemierre and Abrami).

Pathogenic micro-organisms conveyed by the portal circulation into the liver are discharged with the bile, but in the process of elimination they infect the bile-ducts and especially the gall-bladder.

Ulceration of the mucous membrane of the gall-bladder unaccompanied by gall-stones as a complica-

tion of, and a sequel to, typhoid fever has been long recognised. Murchison (1862) drew attention to the occurrence of fatal peritonitis in the course of typhoid fever, set up by the perforation of a typhoid ulcer in the gall-bladder.

The museum of the Middlesex Hospital contains a gall-bladder (obtained by Voelcker) in which the mucous membrane is ulcerated in several places, and one of the ulcers has perforated the whole thickness of the wall of the gall-bladder and its base is formed by the liver. It was obtained from a man, who died in consequence of the perforation of a typhoid ulcer in the lower part of the ileum. The colon and ileum were extensively ulcerated.

In some instances the aid of surgery has been invoked for the relief of patients when an ulcer in the gall-bladder has perforated in the course of typhoid fever.

Monier-Williams and Sheild in 1895 reported a successful case of this kind in a woman aged 31. The operation was undertaken under the idea that an ulcer of the intestine had perforated, but in the course of the operation the trouble was traced to the gall-bladder.

Dr. Ashhurst operated on a boy, aged 12, on account of symptoms indicating perforation of a typhoid ulcer of the intestine. He failed to find a perforation and drained the abdominal cavity. The boy died: at the autopsy evidence of general

peritonitis and perforation of the gall-bladder were found. He was more fortunate with another patient, a youth, aged 20. In this instance there were symptoms of perforation in the course of typhoid fever. An operation was performed, and a hole measuring $1\frac{3}{4}$ by $1\frac{1}{2}$ inches was found in the wall of the gall-bladder. Fortunately this organ was buried in deep adhesions between the liver and colon. Cholecystectomy was performed and the youth made an uneventful recovery. The pus yielded typhoid bacilli in pure culture. Dr. Ashhurst collected the records of 19 operations performed on the gall-bladder during typhoid fever. Of these twenty-one operations performed on patients whilst suffering from typhoid fever, in four the operation was abandoned before the gall-bladder lesion was discovered. These died. Of the remaining seventeen, nine patients died and eight recovered: a gratifying measure of success when the gravity of the condition is properly considered.

The presence of the typhoid bacillus in bile assumed a new importance when Kayser, in 1906, showed that after an attack of typhoid fever the bacilli may persist in the gall-bladder, and travel with the bile into the alimentary canal to escape with the fæces. Typhoid bacilli discharged in this way retain their pathogenic properties. An individual with a gall-bladder harbouring typhoid bacilli in this way is known as "a typhoid-carrier,"

for the bacilli they spread about are capable of producing local epidemics of typhoid fever.

The Strassburg female baker observed by Kayser had had typhoid fever ten years previously, yet her fæces contained typhoid bacilli in large numbers.

When this woman died the gall-bladder contained a calculus the size of two beans. Typhoid bacilli were found in cultures from her gall-bladder, and in the gall-stone, as well as in the bile, the spleen, and liver. She died from typhoid sepsis.

This matter has been investigated by Drs. A. Ledingham and J. C. G. Ledingham, and they confirmed the German observers and added a series of valuable cases worked out with great care and thoroughness. The inmates of lunatic asylums furnished a large proportion of the cases. The study of typhoid carriers has led to a new conception of the pathology of typhoid fever, and the facts have been admirably summarised by Dean in a communication based on the investigation of a man who had probably been a typhoid carrier for twenty-nine years.

It was formerly believed that the typhoid bacillus after its conveyance into the alimentary canal multiplied there, invaded the lymphoid tissue of the small intestine and spleen, and fairly late in the disease found its way into the blood-stream.

The new conception, which we owe chiefly to Förster, maintains that the bacilli are present in the blood during the incubation period, and appear in the

fæces during the first and second week of the disease. The bacilli, therefore, do not multiply in the gut.

At a very early stage the bacilli find their way into the liver and bile, and their presence gives rise to inflammatory changes in the bile-ducts and gall-bladder. According to Förster, normal bile is not a very suitable medium for the typhoid bacillus, but when albuminous material is added to it the bacillus finds it an excellent pabulum. In typhoid fever the albuminous material is supplied by the inflammatory exudate from the ducts and gall-bladder: the bacilli grow freely under these conditions in the gall-bladder, and pass out through the bile-duct into the small intestine and are thrown out in the fæces.

In most cases recovery is accompanied by a cessation of the inflammatory process in the liver, its ducts, and the gall-bladder; in a certain number of cases (2 per cent.) this cholecystitis typhosa becomes a chronic process, and patients so affected constitute the group of typhoid-carriers.

The chain of evidence is complete that the typhoid bacillus has a remarkable predilection for the gall-bladder, and that it may flourish therein for eight, ten, seventeen, and even thirty years, and large numbers of the bacilli may pass almost daily with the bile into the alimentary canal during these long periods and the infected persons suffer no inconvenience. There is, however, evidence that they are sources of infection to other persons who live in the same house.

It has been suggested as a prophylactic measure, that gall-bladders, wherein the typhoid bacillus is known to lead a saprophytic existence, should be drained. Dehler (1907) has performed cholecystotomy and drainage of the gall-bladder in two asylum typhoid carriers, though neither of the patients presented symptoms of gall-bladder disease.

The relation of the typhoid bacillus to cholelithiasis is discussed in Chap. V.

REFERENCES.

- Ashhurst, A. P. C.**, "Perforation of the Gall-bladder during Typhoid Fever."—*American Journal of Medical Sciences*, 1908, i, p. 541.
- Dean, G.**, "A Typhoid Carrier of Twenty-nine Years' Standing."—*Brit. Med. Journ.*, 1908, i, p. 562.
- Dehler**, "Zur Behandlung der Typhus bazillenträger."—*Münch. med. Wochenschr.*, 1907, No. 16, u. No. 43.
- Ledingham, A.**, and **Ledingham, J. C. G.**, "Typhoid Carrier," with Bibliography 1906 and 1907.—*Brit. Med. Journ.*, 1908, i, p. 15.
- Lemierre, A.**, and **Abrami, P.**, "Fievre Typhoide et infection descendante des voies biliaires."—*La Presse Medicale*, 1907, p. 705.
- Levy, E.**, and **Kayser, H.**, "Bakteriologischer Befund bei der Autopsie eines Typhus bazillenträgers."—*Münch. med. Wochenschr.*, 1906, p. 2434.
- Monier-Williams, M. S. F.**, and **Sheild, M.**, "A Case of Perforation of the Gall-bladder following Typhoid Fever Successfully Treated by Abdominal Section."—*Lancet*, 1895, i, p. 534.
- Murchison, C.**—*Continued Fevers of Great Britain*. London, 1862, p. 508.
- Voelcker, A. F.**, "Ulceration of the Gall-bladder in Typhoid Fever."—*Trans. Path. Soc.*, 1895, xlvi, p. 79.
- Welch, Professor**, "Additional Note concerning the Intra-venous Inoculation of the *Bacillus typhi abdominalis*."—*Bulletin of Johns Hopkins Hospital*, 1891, xi, p. 121.

CHAPTER III

INFECTIONS OF THE BILE-DUCTS AND GALL-BLADDER (CHOLANGITIS AND CHOLECYSTITIS)

Cholangitis.—It was formerly taught that inflammatory conditions of the bile-ducts are in nearly all instances due to infection from the gastro-intestinal tract. Modern investigations teach that although the essential cause of cholangitis is invasion of the bile-ducts by pathogenic micro-organisms, these infecting agents are derived from the blood, either from the general or the portal circulation.

Infection by the blood-stream has been especially studied in connection with typhoid fever (see Chap. II).

The effects of infective micro-organisms on the bile-ducts depend in a large measure on their virulence, on certain favouring conditions in the excretory ducts of the liver, and especially on the presence of gall-stones. It will be convenient to consider these changes under the following headings.

(1) Subacute cholangitis ; (2) acute cholangitis ;

(3) suppurative cholangitis; (4) tuberculous cholangitis.

(1) *Subacute cholangitis*.—This is the mildest form of cholangitis, and is known to physicians as catarrhal jaundice. The belief that it is caused by the implication of the papilla and common bile-duct in a mild infection of the mucous membrane of the duodenum rests on no pathological base. Modern investigations teach that infection of the main bile-ducts is with greater probability caused directly by bacteria, or their toxins, in the bile which flows along them (descending infections). The bile obtains these pathogenic agents either from the portal or the systemic systems, as described in the preceding chapter.

Jaundice sometimes arises independently of obstruction in the main excretory ducts, as a complication of general septic infection, but the bile swarms with streptococci or similar pathogenic organisms.

(2) *Acute cholangitis*.—In this disease the large ducts are involved and the infection implicates the mucous membrane of the gall-bladder (cholecystitis). In some cases, especially those associated with gall-stones, the intra-hepatic ducts are infected with very direful consequences (see Chap. VII).

It will be convenient to discuss the effects of cholangitis according to the portion of the excretory apparatus chiefly involved in the infection. Many of the consequences are of great pathological and clinical interest.

An acute cholangitis of the large ducts may subside and leave no trace, or it may become chronic and lead to changes in the walls of the ducts, thickening them, causing desquamation of the epithelium or actual ulceration. Such changes not only lead to thickening of the walls of the ducts, but the inflammatory products will ultimately organise into fibrous tissue and the duct becomes converted into an impervious cord. This obliterating process is sometimes described as sclerosis, and it occurs in its most familiar form in the male urethra, as a sequel of chronic (infective) urethritis.

This change certainly occurs in the bile-ducts and in the gall-bladder, for all these structures may sometimes be found reduced to withered cords, and occasionally the obliterative process is so complete that it is extremely difficult to distinguish them in the course of an operation, or even by dissection after death.

This slow fibrous conversion of the main bile-duct into an impervious cord is very serious, for it may lead to death. Sidney Phillips has published an example and collected some recorded cases where a stricture of the common, or the hepatic duct has caused intractable jaundice, ending fatally without any history of colic, vomiting, or anything pointing to the passage or impaction of gall-stones. His patient was a man aged sixty years, and an ulcer as large as a shilling existed at the lesser curvature of

the stomach on the posterior wall three inches from the pylorus. The gall-bladder was distended to the size of a very large pear and filled with colourless mucus.

In reference to this condition Murchison (1868), writing on "stricture or obliteration of the common bile-duct," states that a gall-stone after causing ulceration may escape, and a stricture form during the cicatrization of the ulcer, and that occasionally ulceration of the bile-duct, with subsequent cicatrization, appears to be independent of gall-stones, and states that ulceration of the biliary passages, independent of gall-stones, is occasionally found after death from enteric fever. It is also certain that stricture of the common bile-duct occurs independently of both causes, for it is occasionally found in new-born children, and in some of these little patients it obliterates the main excretory conduits of the liver in antenatal life far more extensively than in any other period (see Chap. IV).

Among the few recorded cases of stricture of the main bile-duct the example recorded by Moxon is the most remarkable, for in his patient the "hepatic duct at the junction of the two divisions was swollen from the presence in it of a tough matter, making a little soft knot of the size of an almond around and in its walls. The length of the stricture was one inch, and its cause simple connective tissue in the form of a scar, the state resembling that seen in ordinary simple stricture of the urethra."

It is noteworthy that nearly all the writers make the comparison with a urethral stricture, and definitely state the dilated ducts behind the stricture contain mucus. In a case recorded by Bristowe the stricture occurred in the left hepatic duct.

There is a suspicion in the minds of some writers (and which I consider is well founded) that some of the cases reported as fibrous stricture of the hepatic and common ducts may have been examples of primary cancer (See Chap. X).

Complete obliteration of the cystic duct is common, and, as a rule, due to traumatism from gall-stones, and the gall-bladder becomes a large retention cyst or mucocele in consequence ; obliteration of this duct also occurs apart from gall-stones, and from the same cause that leads to partial obliteration of the common and hepatic ducts in adults. In rare instances a syphilitic lesion of the liver may involve and obstruct the common duct (Lazarus-Barlow).

(3) *Suppurative cholangitis*.—When the bile-ducts are infected by a virulent pus-producing micro-organism, the changes which result are akin to those produced in similar circumstances in other mucous canals. The mucous membranes of the ducts are swollen with inflammatory exudation, and their lumina become blocked with shed epithelium and pus stained with bile : the ducts themselves fill with pus, and in very severe conditions the intrahepatic ducts become pus-containing canals dilated at

intervals into larger collections of pus or abscesses. Occasionally some of these collections of pus become confluent and form a liver abscess of large size. The liver is always enlarged in suppurative cholangitis, and the lymph-glands in the portal fissure become infected and increase in size.

The infection sometimes extends to the portal vein, which may become thrombosed (pylephlebitis), or even filled with purulent clot (suppurative pylephlebitis).

The peritoneum covering the liver becomes implicated in the inflammation, and this may lead to fatal peritonitis. Occasionally fatal peritonitis is due to the bursting of an abscess which has made its way to the surface of the liver. This sequel is considered in connection with calculous cholangitis (Chap. VII).

(4) *Tuberculous cholangitis*.—Tubercle bacilli derived from tuberculous foci in the intestines are conveyed to the liver by the portal vein and produce miliary tubercles in the portal spaces. These give rise to masses of granulation-tissue which soften, break down, and discharge into a neighbouring duct, and give rise to an extensive infection of the ducts (tuberculous cholangitis). Even though the ducts are extensively involved, there is no jaundice. As a rule the disease occurs as a sequel of pulmonary and intestinal tuberculosis, and its subjects are generally children. The disease has no special symptoma-

tology, and does not come within the scope of surgery.

A careful account of tuberculous cholangitis, with some excellent illustrations and references to the literature, is furnished by H. Morley Fletcher. Serjent, Gilbert, and Claude have published evidence of an experimental kind which supports the view that tuberculous cholangitis may be due to microbic invasion of the ducts from the blood-stream.

Tuberculous disease of the duodenum may extend into the common bile-duct, cystic duct, and gall-bladder. Lancereaux has described such a condition in a woman aged thirty-two years.

Cholecystitis (inflammation of the gall-bladder).—

Cholecystitis may be part and parcel of a general infection of the bile-duct system of the liver ; it is, however, necessary to consider it separately, not only on account of the important consequences sometimes associated with it, but more especially in its relation to the formation of gall-stones.

From the anatomical point of view the gall-bladder is a diverticulum from the main bile-duct, and pathological processes often proceed in an insidious and unsuspecting way in this receptacle without in any way interfering with the flow of bile along the common duct, until, without any warning—indeed, often with the suddenness of an explosion—severe changes occur in connection with it which place the patient's life in the gravest possible

peril and not infrequently terminate it in a few days.

It is necessary to point out that the infection of the gall-bladder in the first instance formed part of a general infection of the excretory apparatus, but the free communion of the common duct with the duodenum affords it an easy drainage-track which is denied the gall-bladder. If the cystic duct is blocked by swollen mucous membrane or gall-stones, and whilst the main ducts return to a fairly normal state, the infection, though largely deprived of its virulence, retains a certain amount of potency in the gall-bladder, or, to express it in clinical terms, remains chronic. This aspect of the matter will be more fully considered in connection with gall-stones.

The occurrence of cholecystitis as a sequel to general septic infection of the excretory apparatus of the liver is like chronic salpingitis persisting after the acute septic endometritis which established it has subsided.

An infected gall-bladder may suppurate, ulcerate or slough: its walls may calcify or undergo sclerosis. Rarely it is attacked by actinomycosis and tuberculosis.

(1) *Cholecystitis*.—This may form part of a general mild infection of the whole excretory apparatus, or be a residue of an acute infection; it is a very important affection because careful investigations have established the fact that one of

the chief consequences of subacute and chronic cholecystitis is to produce changes in the epithelial elements of the gall-bladder which lead to the production of an excessive quantity of cholesterin and to the formation of gall-stones (see Chap. V). It is on this account that nearly all the serious diseases which affect the gall-bladder, including cancer, are complicated with gall-stones. In truth, the milder forms of cholecystitis may be called the gall-stone-forming disease.

When the inflammatory changes are sufficient to occlude or obliterate the cystic duct, the accumulation of mucus secreted by the glands in the mucous membrane will distend the gall-bladder and form a **mucocele**; gall-stones may or may not be present. A gall-bladder distended in this way is sometimes termed *hydrops vesicæ felleæ*: occasionally the inflammatory changes may be sufficiently severe to destroy the epithelium and thicken its walls in the way described in connection with cholangitis, and the gall-bladder will become reduced to a thin impervious band of fibrous tissue.

(2) *Suppurative cholecystitis*.—Not infrequently when gall-stones are present pathogenic micro-organisms gain access to the gall-bladder and establish suppuration. The presence of calculi in the gall-bladder is a predisposing factor in acute cholecystitis.

In these circumstances the gall-bladder becomes distended with pus, a condition often termed em-

pyema of the gall-bladder. It is preferable to restrict this term to a collection of pus in the pleura and speak of this purulent condition of the gall-bladder as suppurative cholecystitis.

In severe septic infection of the gall-bladder its walls may become gangrenous and slough. This is called phlegmonous or, better, gangrenous cholecystitis.

The gall-bladder, like an ovarian cyst or a hydronephrotic cyst, will occasionally implicate an adjacent coil of bowel, and the parts in contact may become thin enough to allow of the osmosis of intestinal fluid with micro-organisms which will set up suppuration.

The appearance of the gall-bladder when acutely inflamed differs according to the virulence of the infecting micro-organism. In its ordinary condition the gall-bladder has thin walls, but when distended with mucus in the condition commonly called "hydrops" the fluid it contains is sterile; the walls may be very thin and translucent, but in acute infective cholecystitis due to such microbes as the *Bacillus coli*, streptococcus, or the pneumococcus, its walls become thick, œdematous, and livid or plum-coloured, sometimes green and occasionally black (gangrenous). These changes are similar to those seen in sections of intestine when infected secondarily to strangulation in a hernial sac or a volvulus.

Acute infective conditions arise in the gall-bladder with the same suddenness as an acute (fulminating)

appendicitis, or intestinal obstruction, and often in patients who a few hours previously appeared to be

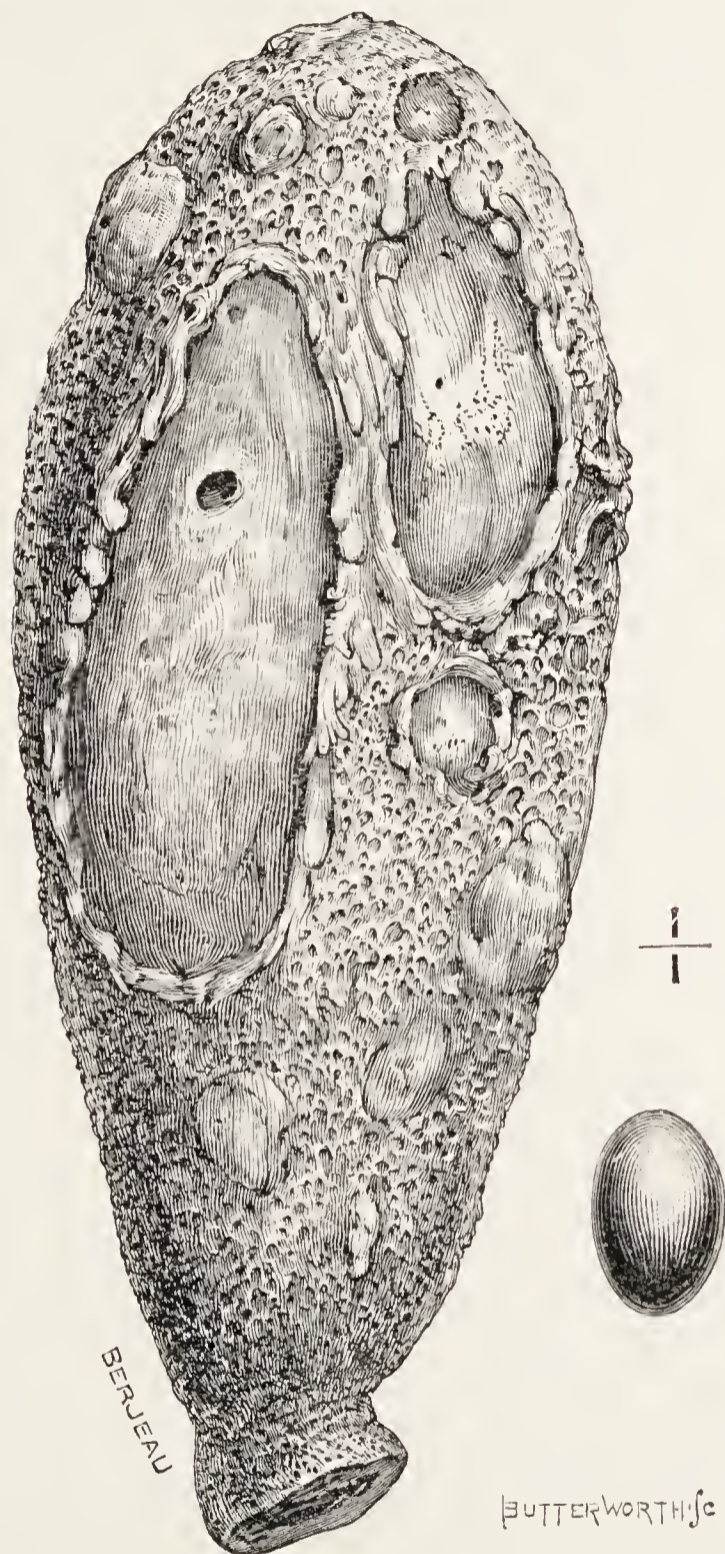


FIG. 6.—An inverted gall-bladder, the seat of acute cholecystitis, showing ulcers in the mucous membrane, one of which perforated into the general peritoneal cavity.

in their normal condition of health. Death in these circumstances is caused by infective peritonitis, due to perforation of the wall of the gall-bladder, which

allows the infective material to escape into the general peritoneal cavity (Fig. 6).

(3) *Ulcerative cholecystitis*.—The only specific infection of the gall-bladder to which the adjective “ulcerative” strictly applies is that due to the typhoid bacillus (see Chap. II).

Cholecystitis associated with gall-stones is often complicated by ulceration of the mucous membrane, and some of the most dangerous consequences arising from gall-stones are brought about by the ulceration; for it leads to perforation of the walls of the gall-bladder, and it will involve adjacent hollow viscera, leading to events which may terminate in a lucky manner for the patients, but, on the other hand, often place their lives in the greatest peril.

(4) *Gangrenous cholecystitis*.—The destructive effects of acute cholecystitis are illustrated by the specimen Fig. 7; in this instance the whole of the mucous membrane was found lying as a slough in the gall-bladder. There were two perforations in the wall of the gall-bladder, one opening into the transverse colon and the other into the general peritoneal cavity. The man was fifty-eight years of age, and he died in the Middlesex Hospital after an illness of ten days. The pancreas contained several small abscesses.

(5) *Membranous cholecystitis*.—This term is applied to an acute and usually calculous cholecystitis in which a membrane forms on the inner surface of

the gall-bladder. This membrane may be present in patches, or it may be so extensive as to produce a complete cast of the gall-bladder.

Cases have been reported in which such membranes

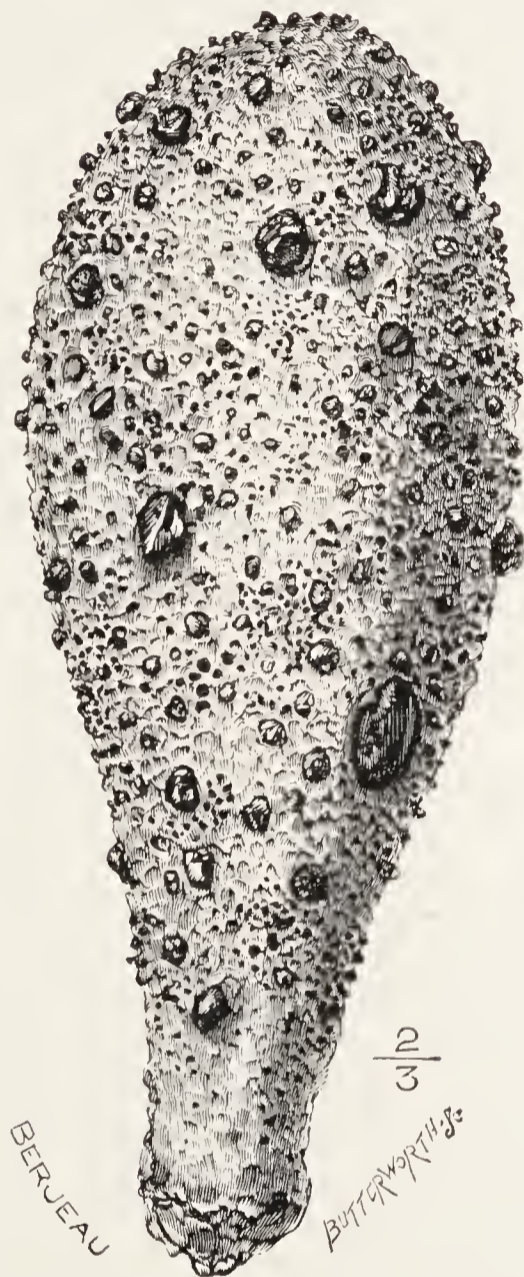

FIG. 7.—The mucous membrane of a gall-bladder which had completely sloughed; it is represented inverted with the minute calculi dotted over it.

have been shed in patches or more or less entire, and their passage through the ducts was accompanied by attacks of pain (biliary colic) and the membrane has been recognised in the fæces.

I have removed a calculous gall-bladder with

success from a woman aged seventy-six years on account of gangrenous cholecystitis; patches of membrane like that seen in diphtheria were present on its mucous membrane.

Calcification of the gall-bladder.—Many museums contain examples of calcified gall-bladders. It is rare to find the whole of the organ calcified, but in many examples the process is very extensive, and the gall-bladder looks like a damaged egg-shell.

This condition is probably a sequel of chronic or subacute cholecystitis. It is well to bear in mind that echinococcus cysts in the liver are liable to calcify, and in the course of an operation it might be somewhat embarrassing to meet with a calcified gall-bladder.

Sclerosis of the gall-bladder (cholecystitis obliterans).—As a consequence of long-continued inflammation the walls of the gall-bladder thicken and slowly undergo conversion (or metaplasia) into fibrous tissue, and if free from calculi they will, in the course of years, be reduced to the condition of a mere fibrous cord, and can only be recognised by its situation in the fossa for the gall-bladder.

Actinomycosis of the gall-bladder.—The only example of this disease at present recorded is a case described by Mayo Robson. The patient was a man, aged forty-seven years, who came under observation with the usual symptoms of cholecystitis. At the operation a large gall-bladder was found adherent to the

abdominal wall, to the liver, and the omentum; all these parts were intimately adherent and invaded with granulation-tissue. This morbid tissue was thoroughly scraped out, and in the laboratory furnished the microscopic features of actinomycosis. The patient was treated with iodide of potassium, and three years later his condition of health was reported to be satisfactory. The route of infection was not determined.

Tuberculous cholecystitis.—Tuberculous cholecystitis is a rare disease; it may be localised to the gall-bladder or occur in association with tuberculosis in other parts of the abdomen. Körte met with an example, and furnishes a drawing of the gall-bladder and references to six other cases which have been described.

Simmonds has published some observations on this condition, and comes to the conclusion that it is an "excretion tuberculosis," and that the bile-ducts and gall-bladder are infected by tubercle bacilli contained in the bile, just as tuberculous infection of the renal pelvis may be induced by bacilli excreted with the urine.

Aneurysm of the hepatic artery.—This artery, in common with those supplying viscera, is liable to become the seat of an aneurysm, sometimes from embolism and very rarely as a result of injury; it is also probable that some aneurysms of the hepatic artery or its branches may be due to ulceration

starting in the walls of the gall-bladder or the bile-ducts and eroding the wall of the artery (Rolleston), and rarely the ulceration may be due to gall-stones.

That ulcerative cholecystitis may produce an extra-hepatic aneurysm of the hepatic artery is of interest in connection with an observation of Kehr, who operated on a case (and with success) in which an aneurysm of this artery opened into the gall-bladder. Riedel encountered in the course of an operation an aneurysm of this artery as big as an apple which opened into the cystic duct. Other examples have been recorded, and Kehr made his case the basis of an interesting and valuable paper.

In an instance recorded by Ross an aneurysm of the hepatic artery became septic and emboli were distributed in the liver, giving rise to multiple abscesses.

An intra-hepatic aneurysm may be the cause of puzzling symptoms. In one recorded instance a man, forty-five years of age, had attacks of severe hæmatemesis, and he died in Charing Cross Hospital; at the *post-mortem* examination an abscess as large as an orange was found projecting from the under-surface of the liver; its walls were in one part adherent to, and its cavity communicated with, the interior of the stomach. An aneurysm as large as an almond was found on a branch of the left hepatic artery; it had burst into the cavity of the abscess,

and the blood had leaked through the perforation into the stomach and was vomited. In reporting this case Pearson Irvine states that the relation of the aneurysm to the abscess was similar to an aneurysm of the pulmonary artery projecting into a vomica. Murchison suggested that the free bleeding which often accompanies the opening of an abscess in the liver may occasionally be due to an intra-hepatic aneurysm.

An aneurysm of the extra-hepatic part of the hepatic artery causes symptoms of such a definite character that its diagnosis may in some cases be a clinical possibility, although the symptoms are similar to those of an aneurysm of the superior mesenteric artery.

In 1861 Frerichs summarised the symptoms of an aneurysm of the hepatic artery: There is a tumour which is sometimes remarkably large and displaces the liver; neuralgic pain from pressure on the hepatic plexus of nerves; and jaundice from pressure on the bile-ducts. The fatal termination in most cases takes place with symptoms of internal hæmorrhage. It is very easy to mistake such a case for the colic arising from gall-stones.

REFERENCES.

Bristowe, J. S., "Obstruction of the Common Duct by a Calculus; Dilatation, Suppuration, and Destruction of Hepatic Ducts; Communication with Branches of Portal Vein and Lung."—*Path. Soc. Trans.*, 1858, ix, p. 285.

- Fletcher, H. Morley**, "Tuberculous Cavities in the Liver."—*Path. Soc. Trans.*, 1899, 1, p. 160.
- Gilbert, A., and Claude, H.**, "Tuberculose Expérimentale du foie par l'Arterie Hepatique."—*Comptes Rendus Soc. de Biologie*, 1896, tenth series, iii, p. 483.
- Irvine, Pearson**, "Aneurysm of the Hepatic Artery in the Cavity of an Abscess of the Liver; Perforation of the Stomach, and Rupture of the Aneurysm into it."—*Path. Soc. Trans.*, 1878, xxix, p. 128.
- Kehr, Prof. H.**, "Der erste Fall von Erfolgreichen Unterbindung der Art. Hepatica Propria wegen Aneurysma."—*Münch. med. Wochenschr.*, 1903, L. 1861.
- Körte, Prof. W.**—*Beiträge zur Chirurgie der Gallenwege und der Leber*, Berlin, 1905.
- Lazarus-Barlow, W. S.**, "Syphilitic Stricture of Bile-ducts."—*Path. Soc. Trans.*, 1899, 1, p. 158.
- Moxon, W.**, "Simple Stricture of the Hepatic Duct causing Chronic Jaundice and Xanthelasma."—*Path. Soc. Trans.*, 1873, xxiv, p. 129.
- Phillips, S.**, "A Case of Stricture of the Bile-duct."—*Clin. Soc. Trans.*, 1888, xxi, p. 26.
- Robson, A. W. Mayo**, "Actinomycosis of the Gall-Bladder."—*Medico-Chirurg. Trans.*, 1905, lxxxviii, p. 225.
- Serjent, E.**, "La Tuberculose des Voies Biliaires."—*Comptes Rendus Soc. de Biologie*, 1896, tenth series, ii, p. 336.
- Simmonds, M.**, "Ueber Gallenblasen tuberculose."—*Centralb. f. Allg. Path. Anat.*, 1908.

CHAPTER IV

CONGENITAL OBLITERATION OF THE EXCRETORY APPARATUS OF THE LIVER

THIS is a rare anomaly and consists, as the name indicates, in the obliteration of the main excretory ducts of the liver and sometimes the gall-bladder. The disease originates in late foetal life, and is accompanied by cirrhosis of the liver and jaundice. In 1892 Dr. John Thomson tabulated forty-nine recorded cases of the disease, and Rolleston has added twelve more (1903).

There is no definite part of the excretory apparatus to which the obliterative process limits itself, and the manner in which the obliterating process picks out various parts is remarkable. It is more frequent in the common duct than elsewhere.

In a specimen preserved in the museum of the Royal College of Surgeons the terminal two inches of the common duct are represented by a fine imperious fibrous thread, but the papilla in the duodenum is normal and a thin bristle can be passed into the pancreatic duct.

The museum of St. Mary's Hospital, London, contains a specimen in which the external excretory apparatus of the liver is represented by solid cords. The museum of the Westminster Hospital possesses an infant's liver in which the hepatic and common bile-ducts appear as solid cords, and the gall-bladder is represented merely by some loose connective tissue.

In contrast to this extensive obliteration of the main ducts it is curious to find descriptions of specimens in which the process limits itself to the very termination of the common duct, the duct behind the obstruction becoming distended into a cyst containing 36 oz. of bile (Oxley). In some examples the duct is obliterated up to and including its termination, but the bile-papilla is preserved. A careful consideration of the reported cases serves to show that when the obliterating process is limited to a small portion of the terminal segment of the common duct, the part above the stricture is apt to dilate and become a large cyst (Fig. 9).

Frerichs refers to observations relating to this condition in infants as early as 1723, and mentions particularly an example dissected by Abraham Vater. Associated with congenital obliteration of the bile-duct is enlargement of the liver, with cirrhotic changes in its tissue. In many instances the spleen is also enlarged. In some instances several examples of this anomaly have occurred in the same family.

Emanuel has described with great care a specimen of congenital obliteration of the bile-ducts in which there was fibrosis of the pancreas and of the spleen. In this instance, though the pancreas was in the process of becoming fibrosed, its main ducts were well formed and opened in the usual way into the duodenum.

The chief signs of the disease are deep jaundice, hæmorrhages, with enlargement of the liver and spleen in infancy. Many of the children die within a few days of birth, but some have survived for six months. The usual cause of death is hæmorrhage from mucous surfaces, such as stomach, intestine, nose, or from the umbilicus.

Concerning the cause of the condition there is much speculation. In the early writings on this disease the primary factor was believed to be a congenital malformation of the ducts, and the biliary cirrhosis was secondary to their obliteration. Now, the prevailing opinion regards the process as independent of any congenital malformation, and attributes it to toxic bodies in the bile, causing a descending cholangitis.

Rolleston has described a specimen of congenital obstruction of the common bile-duct, which he attributed to syphilis. He also points out that some of the reported cases of stricture of the common bile-duct in early life may be a later result of this process. The value of this observation lies in the support it gives to the opinion, that several

different conditions may cause obstruction or obliteration of the excretory apparatus of the liver in newborn children.

Most of those who have considered this anomaly have devoted their attention mainly to the ducts, without considering it in relation to other examples of ante-natal obliteration of the excretory ducts. Any important passage, duct, or orifice in the body may be found congenitally obliterated—for example, the pharynx, œsophagus, duodenum, ileum, rectum, urethra, vagina, auditory meatus, nasal duct, even the aorta itself (coarctation of the aorta).

Nearly all the writers who have interested themselves in this question of congenital obliteration of ducts and passages have remarked that they occur almost exclusively in the situation of what I have termed embryologic events. This is particularly true in relation to the duodenum. The point at which the common bile-duct enters the duodenum is the spot at which the diverticulum buds out from the embryonic gut to form the liver. The duodenum is apt to be constricted immediately above the bile-papilla; occasionally it is intercepted by a perforated diaphragm, and several specimens have been carefully described in which the second part of the duodenum has ended in a *cul-de-sac*; but in all the descriptions I have read the bile-duct entered the distal extremity of the imperforate duodenum.

These facts show that the primitive gut in the

immediate neighbourhood of the bile-papilla is the seat of much activity during foetal life, and I am decidedly of opinion that the factors which lead to obliteration of the main bile-duct in ante-natal life are those which are responsible for imperforations of the pharynx, duodenum, ileum, anus, etc.

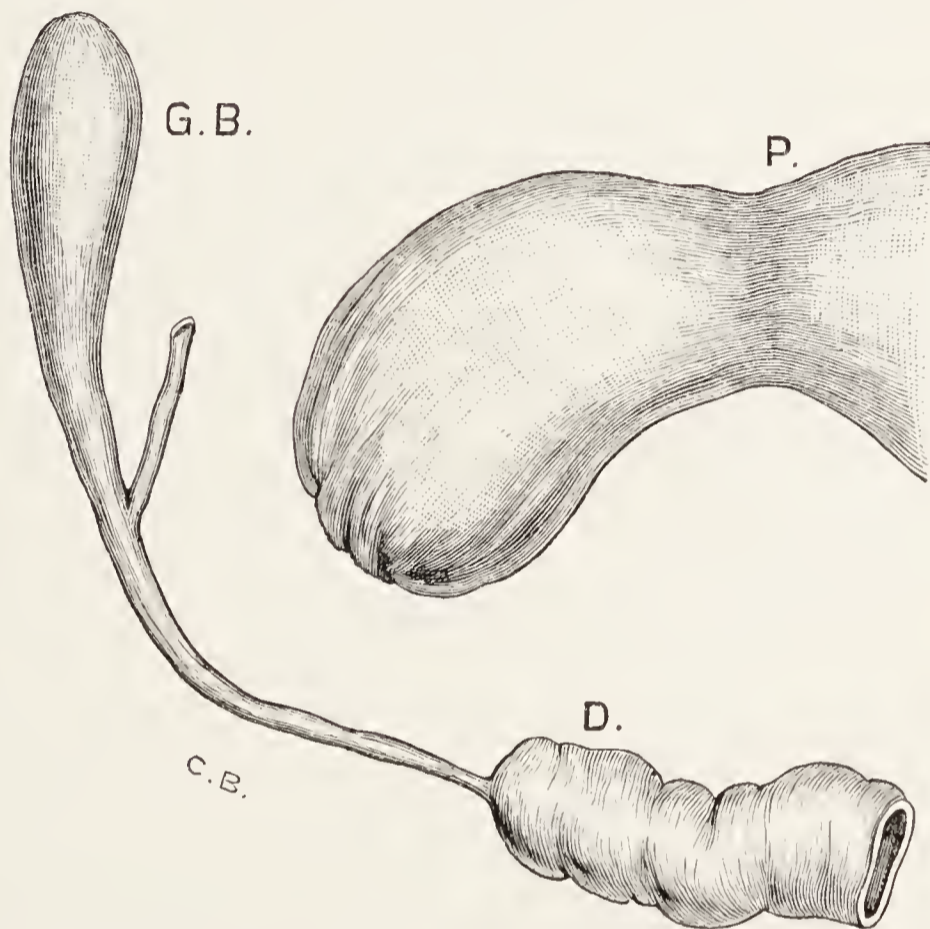


FIG. 8.—Parts concerned in an imperforate duodenum. P. pylorus and first half of the duodenum. D. second half of the duodenum with the common duct and gall-bladder, G. B.

From what we know of congenital obliteration of the ileum it is fair to assume that there are degrees of narrowing or stenosis connected with the common bile-duct, and that a morbid process beginning in ante-natal life need not necessarily be complete at birth, but continues in post-natal life. This is borne out by a case reported by Ashby. A girl aged seven years had suffered from jaundice for

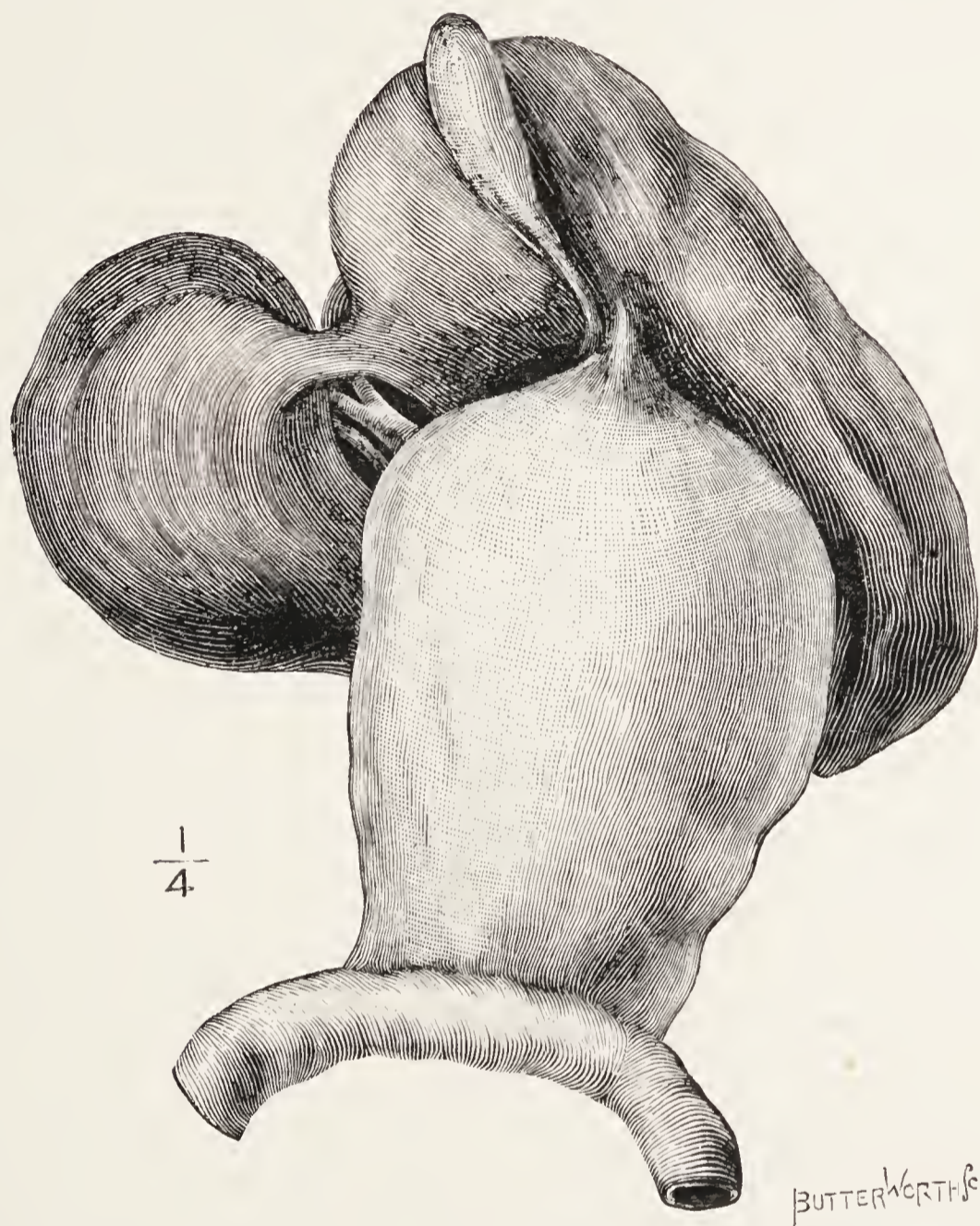
thirty months. The common bile-duct was obliterated near the duodenum and the ducts behind the obstruction, including the cystic duct, were greatly dilated, and contained sixteen pints of bile-stained mucus. The same observation applies to the following case: A girl became jaundiced at the age of three years, and it continued until she was nineteen years of age. She was operated upon by Treves, who found the gall-bladder distended with mucus, faintly tinged with bile; the common duct was not half an inch in length, impervious, and ended as a fibrous nodule. Cholecystenterostomy was successfully carried out. Ten months after the operation the skin was slightly jaundiced.

A similar explanation probably applies to a case reported by Edgeworth. His patient was a girl aged four and a half years, with an abdominal cyst, which he opened and removed 29 oz. of bile, under the impression that it was a dilated gall-bladder. The child died, and at the *post-mortem* examination the gall-bladder and cystic duct were found atrophied, but the cyst represented an enormously dilated common bile-duct; its duodenal end was stenosed.

The specimen represented in Fig. 9 is referred to by Frerichs as being preserved in the Anatomical Museum at Breslau. The common and cystic duct were involved in the dilatation, which contained bile.

In relation to morbid conditions of the bile-ducts during foetal life, reference may be made to some

observations of Still on biliary calculi in children. He finds there is a much greater tendency for the formation of gall-stones during early infancy than



$\frac{1}{4}$

FIG. 9. — Enormous dilatation of the common bile-duct secondary to obstruction of the duodenal orific. From a female infant. (After Frerichs.)

in later childhood, and he refers to Thomson's observation that nearly all, if not all, the calculi found in the newborn are formed during intra-uterine life. He also refers to an observation by Bouisson, who found gall-stones in an infant associated with some

narrowing of the common bile-duct. Still has collected five cases of intense jaundice in new-born infants, due, as was proved by examination *post mortem*, to calculi impacted in the ducts. It is fair to assume that the same morbid process in ante-natal life which obliterates the ducts is also responsible for the production of the calculi (see Chap. V).

In contrast to obliteration of the bile-duct, some examples of very great dilatation of the gall-bladder have been described in children without any obvious evidence of obstruction or jaundice. Among the best known of these is a case recorded with great care and detail by Vincent. The girl was eight and a half years of age and her gall-bladder contained three litres of fluid. Cholecystotomy was performed, but the child died. No definite obstruction was found in the ducts.

In one case the dilated gall-bladder contained three litres of bile and mucus. This little girl, aged two and a half years, recovered from cholecystotomy, which was performed by Miller Brown. There was no jaundice and no obvious obstruction to the common duct.

REFERENCES.

- Ashby, Henry**, "Two Fatal Cases of Obstructive Jaundice in Children."—*Med. Chronicle*, 1898, x, n.s., p. 28.
- Bland-Sutton, J.**, "On the Value of the Systematic Examination of Still-born Children."—*Med.-Chir. Trans.*, 1884, lxxvii, p. 157.
- Brown, Miller**, "Congenital Dilatation of the Gall-bladder and Bile-duct."—*Amer. Journal of Obstetrics*, 1903, xlvi, p. 182.

- Edgeworth, F. H.**, "Case of Dilatation of the Common Bile-duct simulating Distension of the Gall-bladder.—*Lancet*, 1895, i, p. 1180.
- Emanuel, J. G.**, "A Case of Congenital Obliteration of the Bile-ducts in which there was fibrosis of the Pancreas and the Spleen."—*Brit. Med. Journ.*, 1907, ii, p. 385.
- Frerichs, Prof.**—*Diseases of the Liver*, Sydenham Society's translation, 1861, 11, p. 461.
- Hawkins, F. H.**, "Congenital Obliteration of the Ductus Communis Choledochus."—*Path. Soc. Trans.*, 1895, xlvi, p. 76.
- Oxley, M. G. B.**, "Congenital Atresia of the Duodenal Opening of the Common Bile-duct in an Infant producing a large Abdominal Tumour."—*Lancet*, 1883, ii, p. 988.
- Rolleston, H. D.**, "Congenital Syphilitic Obstruction of the Common Bile-duct."—*Brit. Med. Journ.*, 1907, ii, 947.
- Rolleston, H. D.**—*Diseases of the Liver, Gall-bladder, and Bile-ducts*, 1905.
- Still, G. F.**, "Biliary Calculi in Children."—*Path. Soc. Trans.*, 1899, 1, p. 151.
- Thomson, J.**, "On Congenital Obliteration of the Bile-ducts."—*Edinburgh Med. Journal*, 1892, xxxvii, pp. 523, 604, and 724.
- Treves, Sir F.**, "A Case of Jaundice of Sixteen Years' Standing treated by Operation."—*Practitioner*, 1899, lxii, p. 18.
- Vincent, E.**, "De la Cholécystotomie chez les Enfants."—*Revue de Chirurgie*, 1888, viii, p. 753.

CHAPTER V

GALL-STONES: THEIR FORM, STRUCTURE, COMPOSITION, AND MODE OF FORMATION

Classification.—Naunyn arranges gall-stones into six classes, according to their composition :

(1) *Pure cholesterin stones.*—These are hard, oval, or roughly spherical, seldom faceted. They are white, or yellowish and translucent, or more rarely brown or greenish on the surface. On section they are crystalline, but not stratified. They vary in size from a cherry to a pigeon's egg.

(2) *Laminated cholesterin stones.*—These may contain nearly 90 per cent. of cholesterin, the remaining constituents being bilirubin-calcium in the brown and biliverdin-calcium in their green parts. These stones are hard but may be friable when dry. They are often distinctly faceted and on section display laminae which are coloured yellow, brown, and even green or red. In size and form they resemble pure cholesterin calculi. The external layers are usually vitreous or earthy, but the structure is crystalline towards the centre of the stone.

(3) *The common gall-bladder stones.*—The bulk of gall-stones are included in this category: they vary in size, form, and tint, and are distinctly faceted. Their surfaces are usually yellow, but often brown or white; they are often no larger than the head of a pin, and rarely exceed the dimensions of a large cherry. When fresh they are often soft and can be squeezed into a pulp. On section they

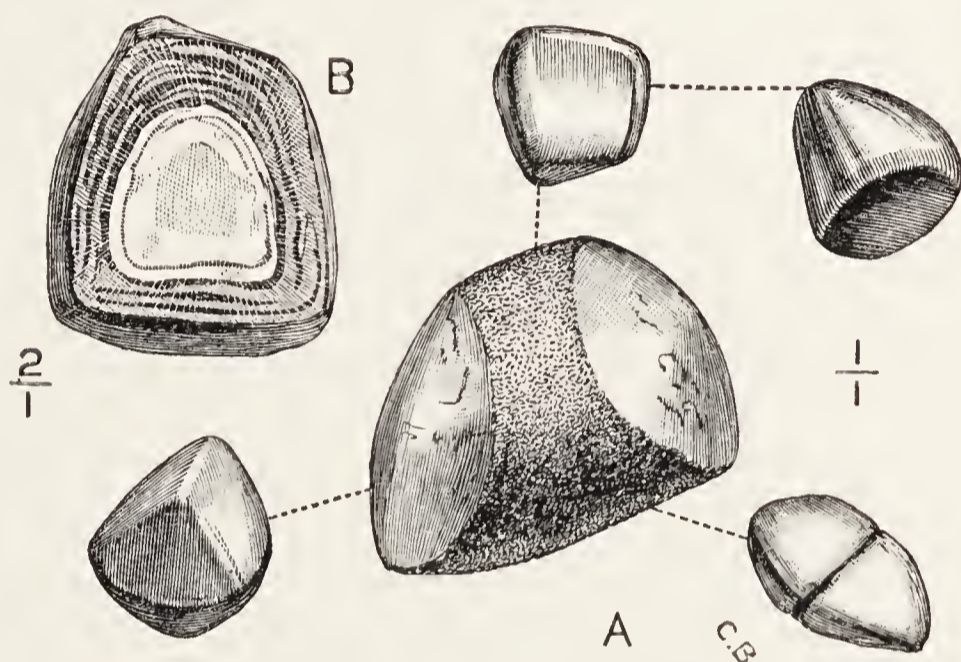


FIG. 10.—A group of common faceted gall-stones.

are laminated, and within the nucleus there is frequently a cavity filled with yellow alkaline fluid. Such calculi do not exhibit any distinct crystalline structure to the naked eye.

(4) *Mixed bilirubin-calcium calculi.*—These stones are usually as big as a cherry. A solitary stone is common, but groups of three or four may be found in the gall-bladder or large bile-ducts. When multiple they are faceted. These stones contain 25 per cent. of cholesterin, the remainder being

bilirubin-calcium. The nucleus is cholesterin, covered by thick layers of dark brown material which easily flakes off.

(5) *Pure bilirubin-calcium calculi*.—These stones vary in size from a grain of sand to a pea; they occur in two forms :

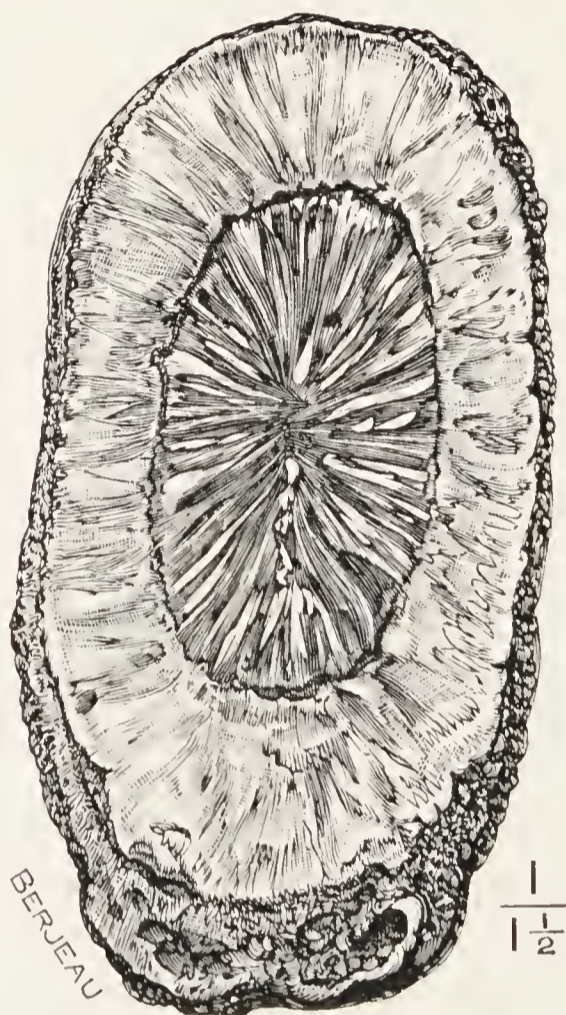


FIG. 11.—A large cholesterol calculus in section.

(a) As solid, brownish-black concretions about the size of a pin's head with rough, irregular surfaces. They are waxy, and show a tendency to weld together.

(b) These are, as a rule, small, steel-grey or black, with a pronounced metallic lustre. They are hard and brittle, and have a spongy texture, and in

the midst of the meshes there are small granules with a metallic lustre.

Bilirubin-calcium is the chief constituent of these calculi, but there are always present, and often in

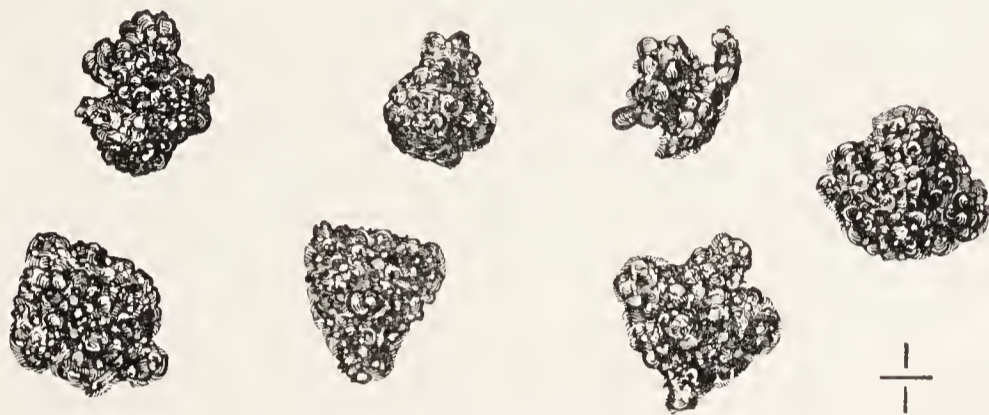


FIG. 12.—A group of bilirubin-calcium gall-stones.

considerable quantities, biliverdin-calcium, bilifuscin, and cholesterin in minute quantity.

(6) **Rarer forms.**—(a) *Amorphous and incompletely crystalline cholesterin gravel.*—These vary in size from a grain of sand to that of a large pea, and often

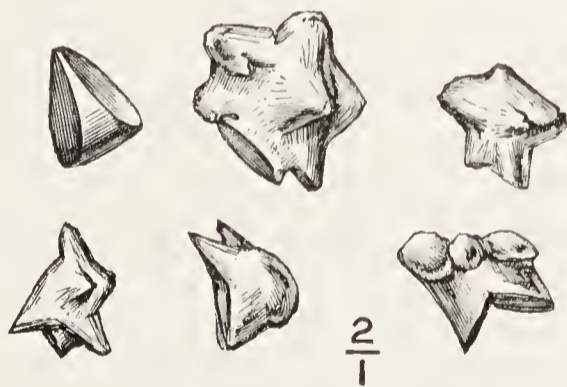


FIG. 13.—Gall-stones composed of chalk. (Calcium carbonate.)

look like pearls. They have a nucleus of bilirubin-calcium enclosed in cholesterin.

(b) *Calcium carbonate calculi (calcareous stones.)*—These are rare. The museum of the Middlesex Hospital contains a set of twenty spiculated chalk

(calcium carbonate) stones removed from the gall-bladder after death.

(c) *Concretions with included bodies.*—Gall-stones not infrequently have a nucleus which may be recognised as an independent calculus. Such may be called conglomerate gall-stones.

Foreign bodies, such as a round worm or a portion of a fluke, a needle, and a plum-stone, have been found in gall-stones.

(d) *Casts of bile-ducts.*—These are rare in man. They consist of pure bilirubin-calcium, and among the small calculi composed of this material there are always some which are hollow and are actually casts of the smaller bile-ducts.

From this it will be seen that cholesterin and bilirubin-calcium are the most important chemical constituent of gall-stones. Calcium carbonate ranks next. Pure bilirubin-calcium stones are found in the gall-bladder and in the intrahepatic ducts. The true denizens of the gall-bladder are the common mixed cholesterin stones. It is a noteworthy fact that stones removed from any one gall-bladder are alike in appearance and constitution.

A solitary calculus closely embraced by the mucous membrane of the gall-bladder has a rough surface, due to small tubercles, and if these be carefully examined they will be found to correspond to the pit-like depressions (*foveolæ*) which beset the mucous membrane of the gall-bladder.

There is a condition of the mucous membrane of the gall-bladder occasionally seen in which these foveolæ are occupied by small dots of bilirubin-calcium ; these are the beginnings of calculi, and more rarely its inner surface is sprinkled with cholesterin crystals, which are adherent to the epithelium. The museum of the Medical School attached to Charing Cross Hospital contains some carefully prepared specimens of this, and in two of the pre-




FIG. 14.—A solitary tuberculated gall-stone.

parations the spangles of cholesterin on the mucous membrane sparkle like the tinsel on the coat of a harlequin.

The mode of origin of gall-stones.—Our knowledge of this matter we owe to Naunyn, who showed that the cholesterin of which they are so largely composed is not derived from the bile, but from the epithelium of the gall-bladder, especially when inflamed ; little masses of cholesterin, mixed with bilirubin-calcium from the nuclei of the stones, and these two substances may collect about shed epi-

thelium and clumps of bacilli which may happen to be in the gall-bladder. Micro-organisms, especially the *Bacillus typhosus*, *coli communis*, streptococcus,

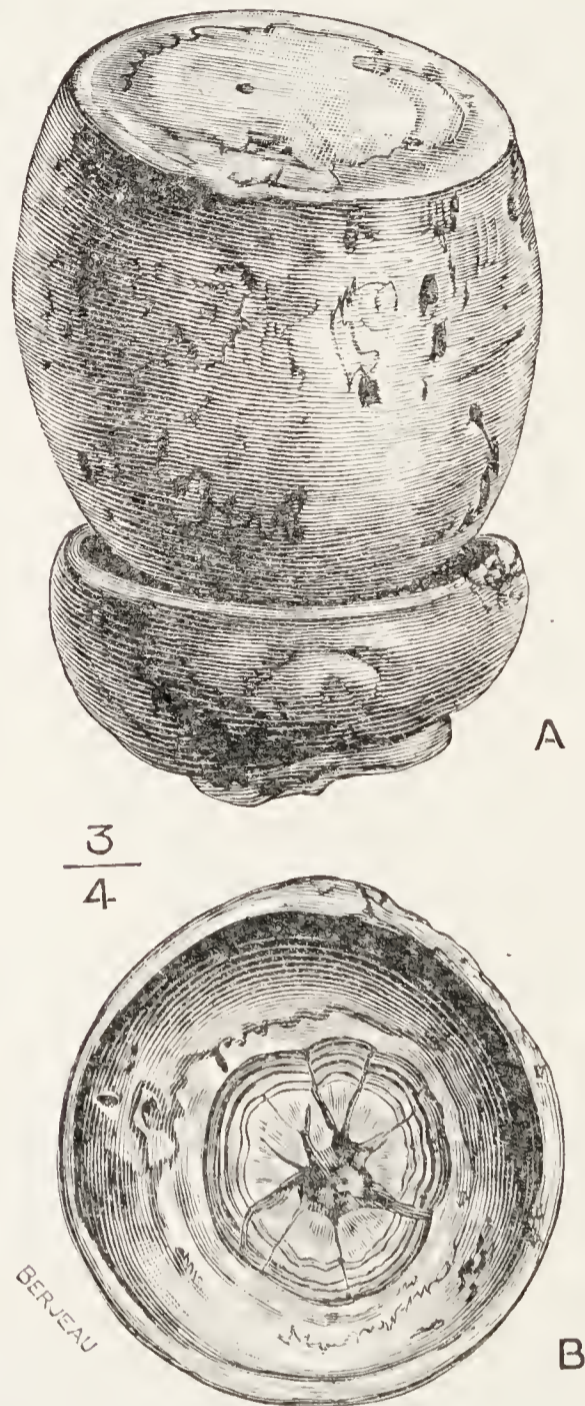

FIG. 15.—Two gall-stones adjusted in the form of a mill. B. The nether gall-stone with its polished surface exposed. (From a cancerous gall-bladder.)

and pneumococcus, are often present in the gall-bladder, and thus act in a two-fold capacity, for they set up a catarrhal condition in the mucous membrane of the gall-bladder which leads to the production of

cholesterin, and clumps of bacilli form nuclei around which it may collect.

Many observations have been published drawing attention to the frequency with which typhoid fever is complicated with *Cholecystitis typhosa* and the typhoid bacillus has been found in the gall-bladder years after the patients have recovered from the fever; moreover, clumps of these bacilli and of the *Bacillus coli* have been isolated from the nuclei of gall-stones (see Chap. II). The relation between micro-organisms and gall-stones has been experimentally established. (Gilbert, Fournier, Girode, Mignot, Hanot, and others.)

Experimental experience has also taught that gall-stones do not follow virulent infection of the gall-bladder, but the most successful results are obtained after the injection of attenuated cultures into the gall-bladder.

The favouring conditions for the formation of gall-stones are catarrh of the epithelial lining of the gall-bladder and the bile-ducts and the presence of micro-organisms, especially the *Bacillus typhosus*.

The successful experimental production of a biliary calculus represented in Fig. 16 was obtained by Mignot in the following way:

A small compress impregnated with a pure culture of *Bacterium coli* was introduced into the gall-bladder of a dog, December, 1897. The microbe was obtained from a calculous cholecystitis in man and attenuated.

Six weeks later the dog was again operated upon and the compress removed from the gall-bladder ; at the same time a thread 2 cm. long was fixed into the gall-bladder wall and the free end allowed to float in its cavity. In June, 1898, cholecystectomy was performed on the living dog and two cholesterol calculi were found on the thread in the gall-bladder.

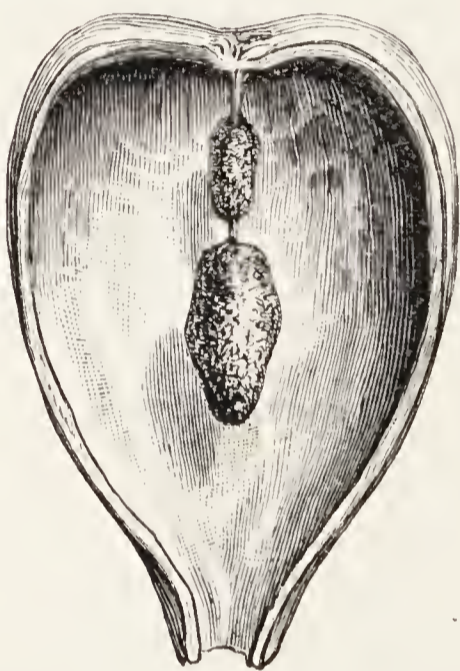


FIG. 16.—Gall-bladder of a dog opened longitudinally showing two gall-stones formed around a thread experimentally introduced (Mignot).

Mignot found that as long as the bacteria retain their virulence they do not form calculi, but only a sediment mixed with pus.

The attenuation of the microbe is best obtained by growing the bacteria for some months in bile to which constantly decreasing amounts of broth are added. When sufficiently attenuated they are no longer pathogenic when injected into the cellular tissue of animals.

Homans recorded a case of interest in relation to this experiment and also of importance in relation to the recrudescence of gall-stones.

He performed cholecystotomy on a woman aged thirty-eight years, and removed ninety-seven gall-stones and closed the gall-bladder (cholecystendysis). On counting the gauze dabs one was missing, and

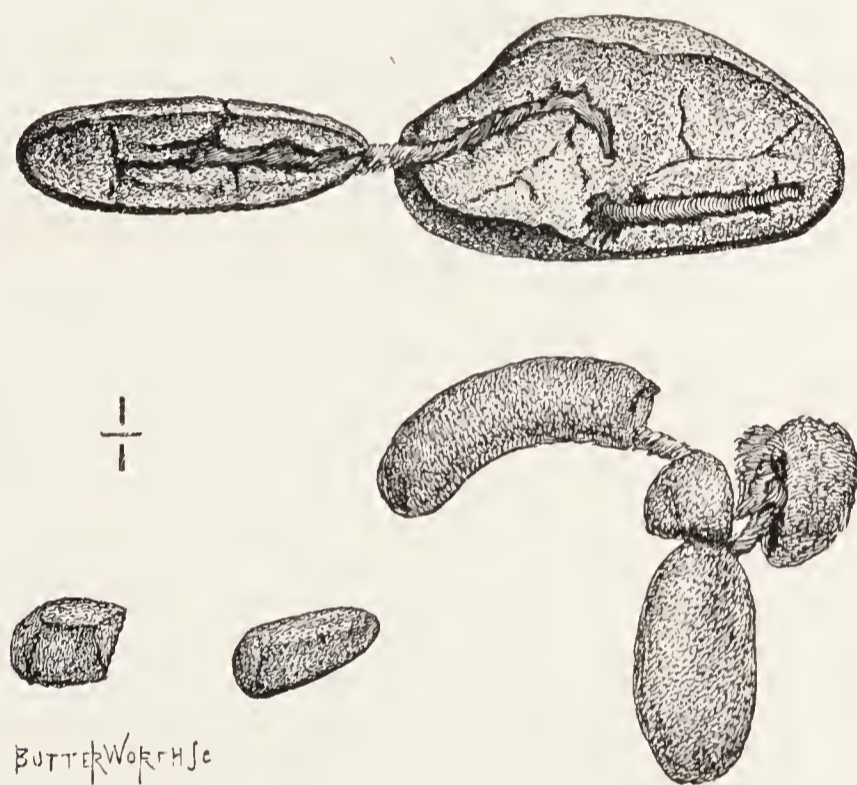


FIG. 17.—Two groups of gall-stones formed around a thread accidentally left in a gall-bladder (Homans).

could be felt in the gall-bladder ; this was reopened, the dab recovered, and the gall-bladder stitched to the abdominal wound and drained. Twenty months later there was recurrence of symptoms which led to a second operation, and on opening the gall-bladder the calculi represented in Fig. 17 were removed. Homans states that the thread on which they are formed was that used to close the gall-bladder at

the time the swab was sequestered, and it had not been removed.

Gall-stones form on pieces of catgut used as sutures for securing the gall-bladder to the abdominal wall in the operation of cholecystotomy (Sinclair White, Hamilton Drummond).

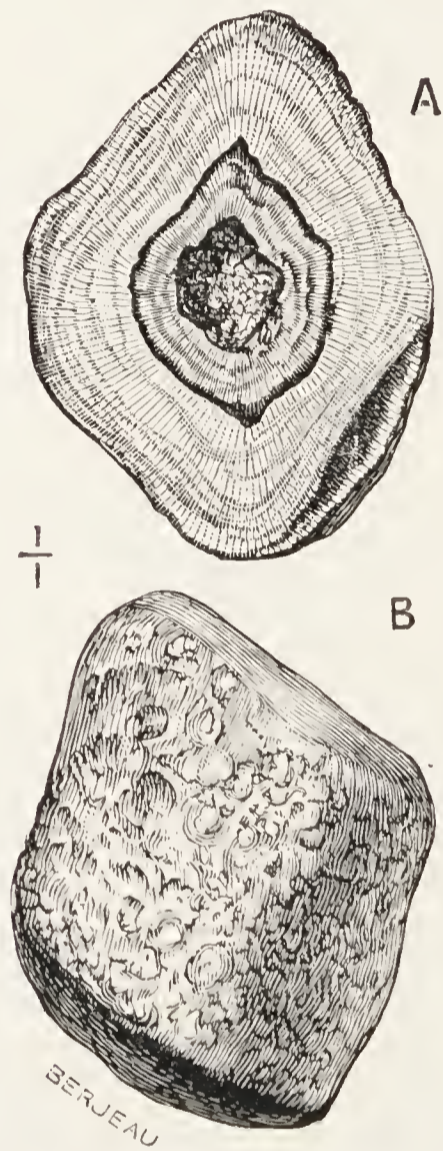


FIG. 18.—Quadrilateral gall-stones. A. In section. B. Entire.

In regard to the recrudescence of gall-stones after cholecystotomy the following observation, published by Kehr, has, as Körte remarks, the value of an experiment :

Twelve cystotomised patients complained of pain, gastric trouble, and colic. The gall-bladder region

was painful, the scar swollen, and there was evidence of cholecystitis. In five he punctured with a fine needle and withdrew turbid bile, which contained *Bacterium coli*. This furnishes strong evidence for those who advocate cholecystectomy.

It might be urged that concretions are found occasionally in the bile-ducts of the newly born whose bile is sterile; but these are soft bilirubin-calcium concretions, and it is not out of question that they may be the productions of inflammation, especially when we remember that congenital obliteration of the main bile-ducts, and even of the gall-bladder, is attributed to ante-natal inflammation (see Chap. IV).

Small bilirubin-calcium concretions not infrequently play the part of foreign bodies and establish a cholelithiasis. Naunyn writes that he has several sets containing twenty or thirty stones out of one gall-bladder; in the centre of each stone there is a bilirubin-calcium concretion (p. 105).

Facetting.—A solitary gall-stone, free to swim in the bile or contained in the gall-bladder, is usually ovoid and smooth on the surface. When a stone is tightly embraced by the walls of the gall-bladder its surface is nodular, the nodules being casts of the pits in the mucous membrane lying in contact with the gall-stone; thus a large gall-stone is often a cast of the interior of the gall-bladder. A very large stone in a greatly distended gall-bladder may have

a smooth surface, as in the gall-stone Fig. 19, which is the largest specimen I have removed: it measures 13 cm. round the base and 19 cm. round the major axis. The patient, a woman aged 50 years, had a gall-bladder so large that this big calculus could float about in the bile it contained.



FIG. 19.—A solitary gall-stone successfully removed from an inflamed gall-bladder. Nat. size. (Museum of the Middlesex Hospital.)

When the gall-stones are multiple, and especially when gregarious, facets are usually present; these are produced by pressure when the calculi are soft, and not by abrasion. The effect of pressure in producing facets and modifying the shape of gall-

stones is shown in Fig. 15. In the elongated gall-bladder (Fig. 20) the string of calculi was firmly

FIG. 20.

FIG. 21.

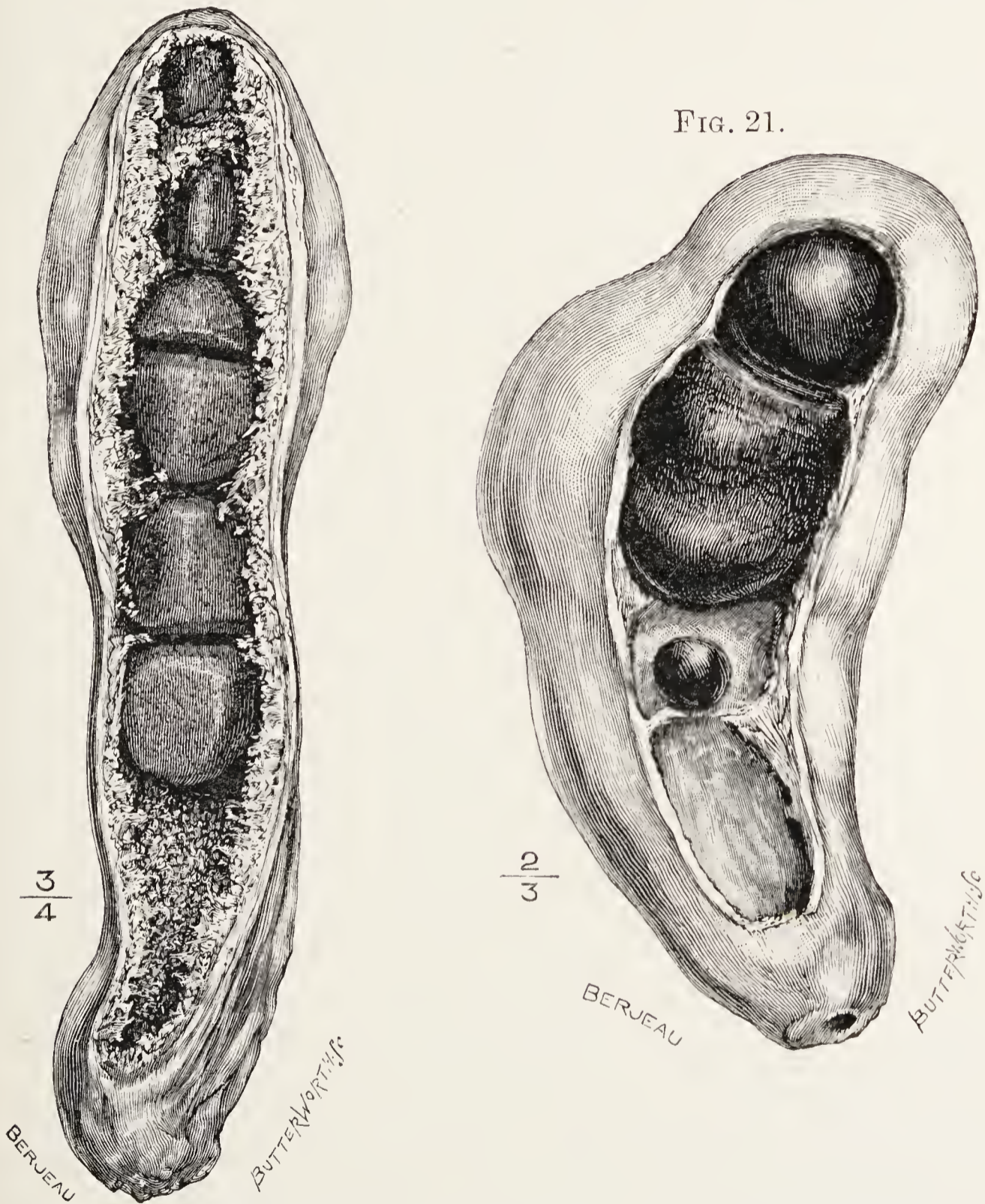


FIG. 20.—A gall-bladder elongated like the finger of a glove, tightly compressing a row of gall-stones.

FIG. 21.—Gall-bladder with a drum-shaped calculus.

kept in line and facets only appear on their opposed surfaces.

The facets on calculi in such circumstances resemble those seen in large gall-stones tightly impacted in the cystic duct.

The presence of facets on gall-stones is of some importance to the surgeon because in the course of an operation it affords him valuable evidence concerning the existence of other calculi in the gall-bladder or ducts.

The fact that gall-stones in the early stages of their formation are soft explains their curious shape when occupying the intrahepatic ducts (see p. 103).

The formation of gall-stones is more complex than would appear at first sight. For example, pure cholesterin stones can only form in a gall-bladder when the cystic duct is so completely obstructed that no bile enters the gall-bladder.

Then, as Naunyn so carefully relates, when the cholesterin nucleus of a gall-stone is coated with layers of bilirubin-calcium and biliverdin-calcium, it may, if no bile runs into the gall-bladder, become coated with cholesterin, and under favourable conditions the cholesterin may permeate the calculus and crystallise, and whilst the cholesterin is thus permeating the calculus through favouring cracks and fissures the bilirubin-calcium is dissolved out and finally replaced. Thus a gall-stone primarily composed of laminae is transformed into a pure cholesterin calculus with a crystalline structure (secondary crystallisation of cholesterin).

This observation is of importance because the absence of surface crystallisation on the gall-stone

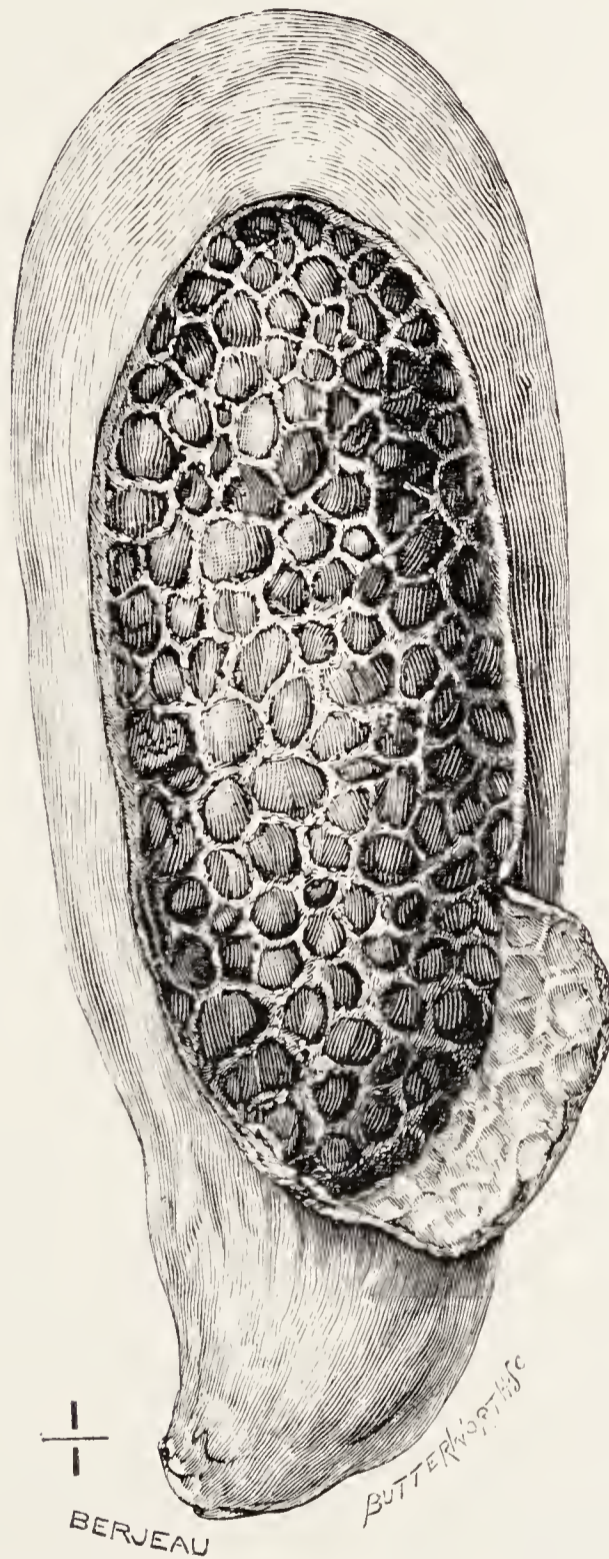


FIG. 22.—A gall-bladder tightly filled with calculi. A portion of the wall has been cut away to show them arranged like the pieces in a mosaic with mucus for cement. (Museum of the Charing Cross Hospital.)

shows that their growth has not been brought about by the deposition in crystals of the cholesterin held

in solution by the bile. The time required for the formation of gall-stones has been variously estimated. Experimental evidence supports the view that it requires six months to form a well-stratified biliary calculus (Mignot). Calculi are probably formed in batches, and it is possible that the calculi in a gall-bladder may be of the same age and due to the same attack of cholecystitis. This would explain the fact that the calculi in any one gall-bladder are of the same class and composition (Fig. 22).

REFERENCES.

- Drummond, H.**, "Note on a Case in which a Gall-stone formed round a Catgut Suture."—*Lancet*, 1908, 1, p. 1206.
- Gilbert, A., and Fournier, L.**, "Rôle des Microbes dans la Genèse des Calculs Biliaires."—*Comptes Rendus Soc. de Biologie*, 1896, tenth series, iii, p. 155.
- Gilbert et Gerode**, "Cholecystite Purulente Provoquée par le Bacillé d'Eberth."—*Comptes Rendus Soc. de Biologie*, 1893, ninth series, v, p. 956.
- Hanot and Letienne**, "Note sur Diverses Variétés de Lithiase Biliare."—*Comptes Rendus Soc. de Biologie*, 1895, tenth series, ii, p. 857.
- Homans, J.**, "Gall-stones formed around Silk Sutures twenty months after recovery from Cholecystotomy."—*Annals of Surgery*, 1897, xxvi, p. 114.
- Kehr, Hans**, "Wie Verhält es sich mit den Recidiven nach unsern Gallensteinoperationen?"—*Langenbeck's Archiv*, 1900, Bd. lxi, s. 173.
- Mignot, R.**, "L'Origine Microbienne des Calculs Biliaires."—*Archives Générales de Médecine*, 1898, ii, p. 129.
- Naunyn, Prof.**—*On Cholelithiasis*, 1892. Translation by the New Sydenham Society, 1896.
- White, S.**, "Gall-stone formed around a Chromicised Catgut Ligature."—*Brit. Med. Journ.*, 1907, ii, p. 883.

CHAPTER VI

THE PATHOLOGIC CONSEQUENCES OF GALL-STONES

THE evil consequences which arise from gall-stones are many, various, and often serious to those who are unfortunate enough to possess them. This has been a favourite subject with medical writers, and the literature relating to it is enormous. The severe pain and constitutional disturbance which attend their passage along the ducts have attracted great attention, and the deep interest aroused by the surgical treatment of cholelithiasis has added to the accuracy of our knowledge concerning the local complications set up by gall-stones. These inconveniences will be considered under three headings :

- (1) Gall-stones in the gall-bladder and cystic duct.
- (2) Gall-stones in the hepatic and common duct.
- (3) Concretions in the intrahepatic ducts.

Gall-stones in the gall-bladder and cystic duct.—The common place for gall-stones is the gall-bladder. This receptacle is admirably adapted for their production, especially as experimental inquiry has shown that the two favouring conditions for their production

(stasis of the bile and the presence of micro-organisms) exist in it. Naunyn pointed out that though cholesterin is found in many parts of the body in addition to the bile-passages, the frequency of chole-

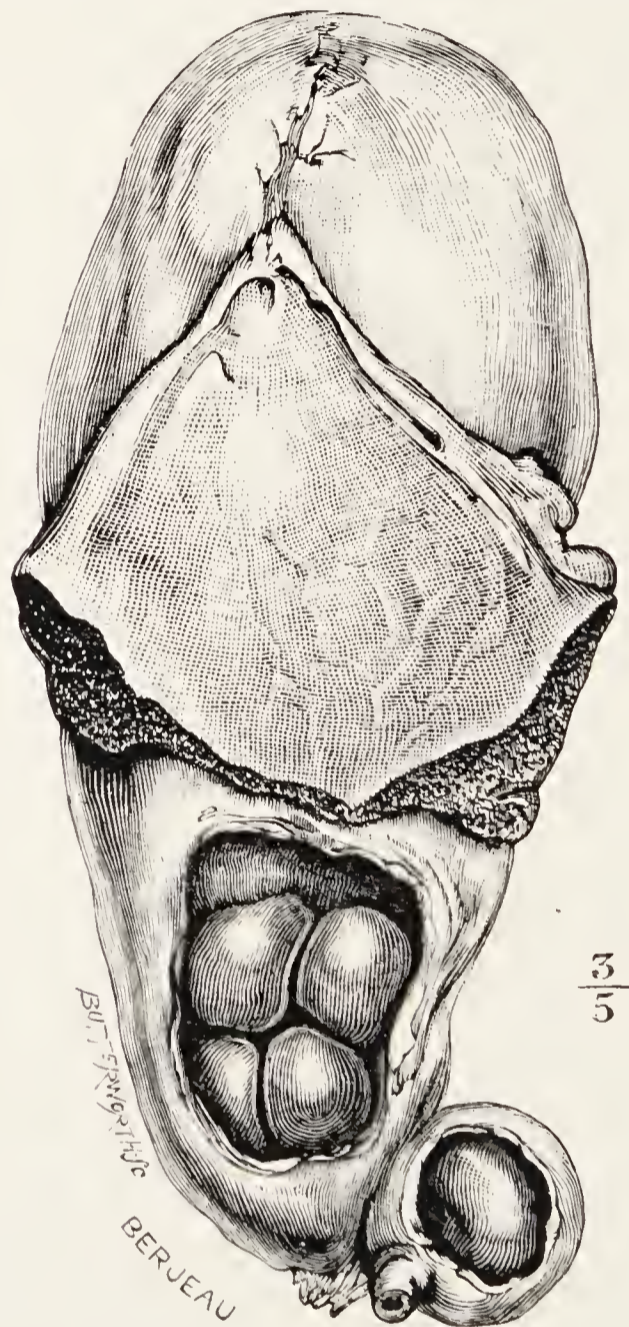


FIG. 23.—Gall-bladder dilated and filled with mucus (*hydrops vesicæ felleæ*) secondary to the impaction of a gall-stone in the cystic duct. The triangular patch of liver is sometimes called Riedel's lobe.

sterin² stones in the gall-bladder is due to the presence of a cementing substance admirably suited to the purpose—namely bilirubin-calcium. Moreover, the gall-bladder is a place of refuge in which the newly

formed concretions can undergo further development undisturbed, and their consolidation favoured by the compression exerted by its muscular coat.

The number and size of gall-stones in the gall-bladder vary greatly. The largest gall-stone I have removed is represented by Fig. 19; the greatest number of biliary concretions which have come under my own notice in one patient is 1321. It is not uncommon to find 100 calculi present. Naunyn counted 5000 in a gall-bladder and Otto 7000.

The conditions of calculi in the gall-bladder are worth comment. When the cystic duct is occluded by a calculus no bile enters the gall-bladder, but it becomes filled with mucus and slowly enlarges, and may become big enough to be obvious on clinical examination. In typical examples of this condition (*hydrops vesicæ felleæ*) the gall-bladder is a thin translucent, pyriform bag, and the calculi it contains consist usually of almost pure cholesterol and float freely about in the thin mucus. A gall-bladder enlarging in this way usually has attached to it a triangular and colourless process of the adjacent hepatic tissue.

In other specimens the mucus of the gall-bladder may be so inspissated that the gall-stones are imbedded in it as if it were a mere stiff paste. (Fig. 25). Mayo Robson found the mucus in a calculous gall-bladder equal in consistence to jelly,

and he removed it entire; the mucus being transparent, this cast of the gall-bladder with the stones

FIG. 24.

FIG. 25.

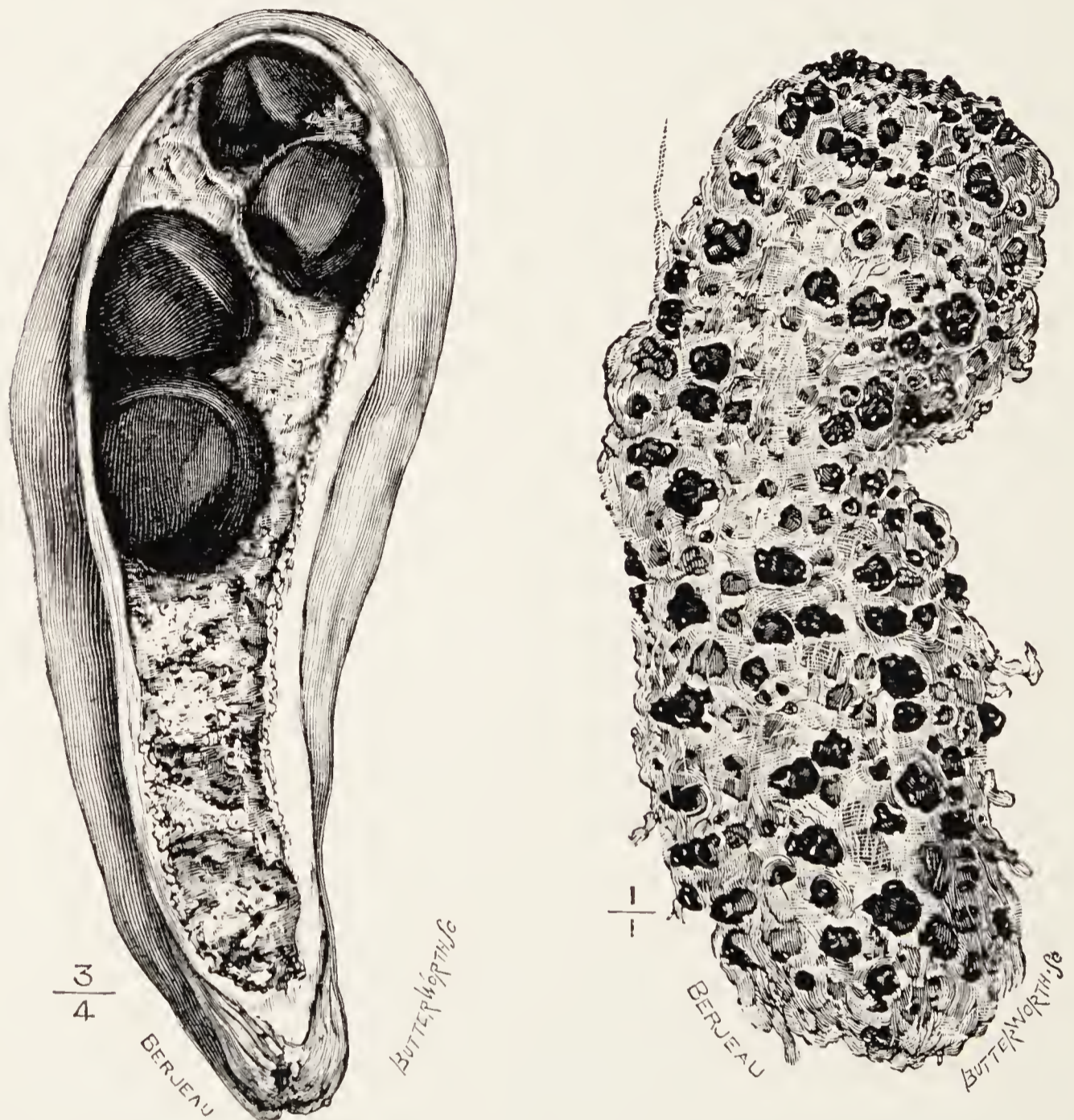


FIG. 24.—A gall-bladder with gall-stones imbedded in firm mucus.
 FIG. 25.—Bilirubin-calcium calculi imbedded in the gelatinous contents of the gall-bladder; “gall-stones in aspic” (Museum Royal College of Surgeons).

in position resembles what a cook would call “gall-stones in aspic” (Fig. 25).

In such conditions the walls of the gall-bladder are sometimes a centimetre or more in thickness and

often very tough, indicating the existence of a more severe form of cholecystitis than in the simple mucocele. The gall-stones in these cases are of the common laminated variety.

A solitary gall-stone may exist in the gall-bladder under two opposite conditions. The stone may be large, oval, and smooth, and the gall-bladder large and full of bile or mucus, and the gall-stone free to move about. In such a condition it is liable to block up the orifice leading to the cystic duct and produce sudden distension of the gall-bladder and great pain. The distension of the gall-bladder is sometimes so great that it forms a tumour under the costal arch. In a few hours the blockade is removed, the pain subsides, and the swelling disappears. The term **intermitting hydrops** may appropriately be applied to such a condition.

In another class of case the gall-bladder may be firmly contracted on a solitary gall-stone, the surface of which is rough and tuberculated (Fig. 26), the small tubercles representing casts of the pits in the mucous membrane of the gall-bladder.

Occasionally when the gall-bladder contains numerous calculi of different sizes, its walls may contract on them firmly and press them together, so that on opening the gall-bladder it will require some force to extract the stones. If such a gall-bladder be removed entire and its wall be partly peeled off the stones form a rude mosaic (Fig. 27), or if the calculi

are of the same size, the appearance is not unlike that of a head of ripe maize (Fig. 22), the thick mucus acting as cement. In rarer instances an enlarged gall-bladder contains a crowd of loose stones, and

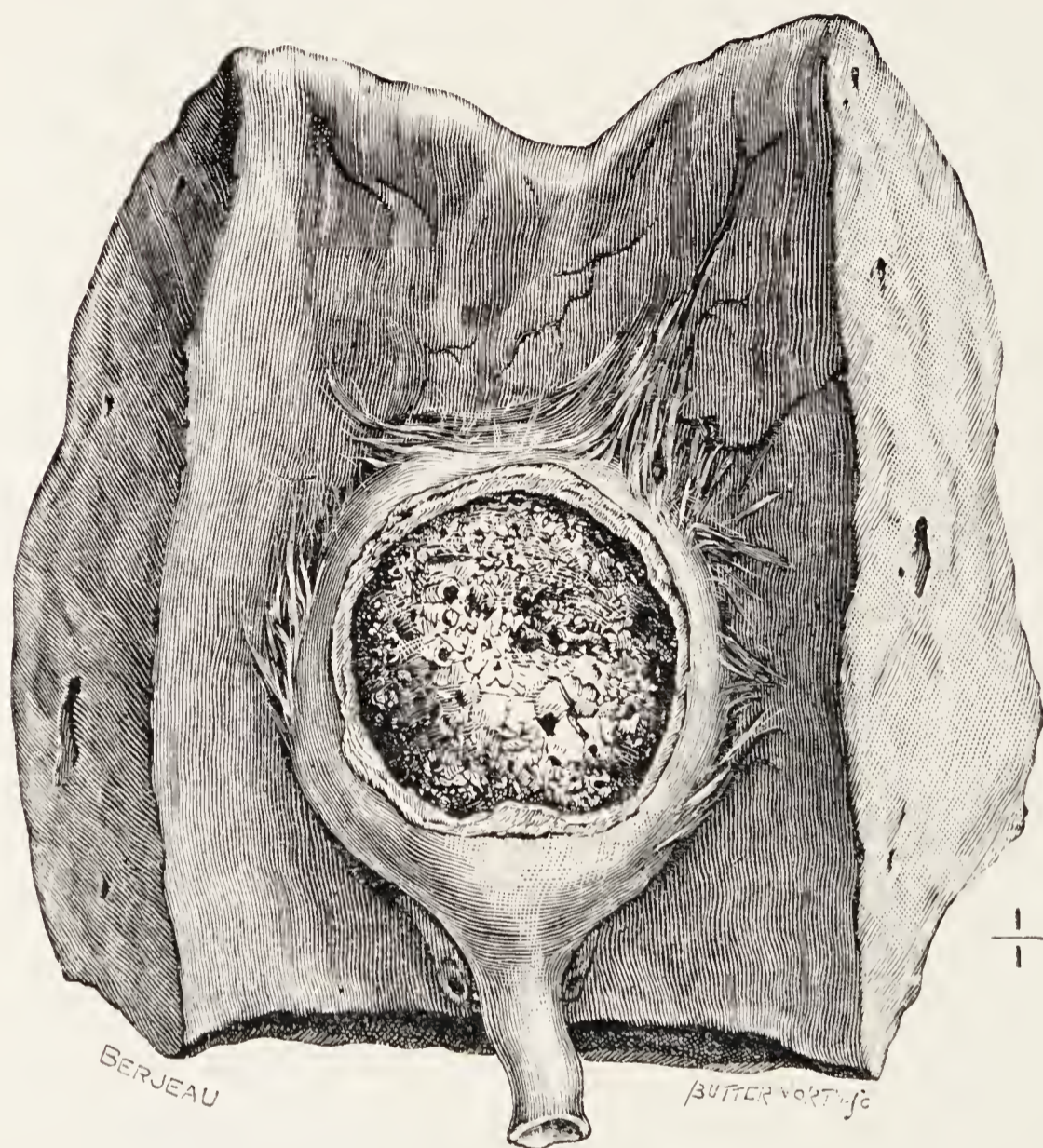


FIG. 26.—A solitary gall-stone in a contracted gall-bladder (Museum of the Royal College of Surgeon).

when it hangs low in the abdomen and the belly wall is thin the calculi may be made to rub together. I have seen an example of this in a thin, emaciated old woman.

When a gall-bladder contains two large calculi and contracts upon them it will assume an hour-glass

shape, and if it be bisected the two distended portions will be found separated by a perforated diaphragm. Bilocular gall-bladders are common, and occasionally, when containing several stones of

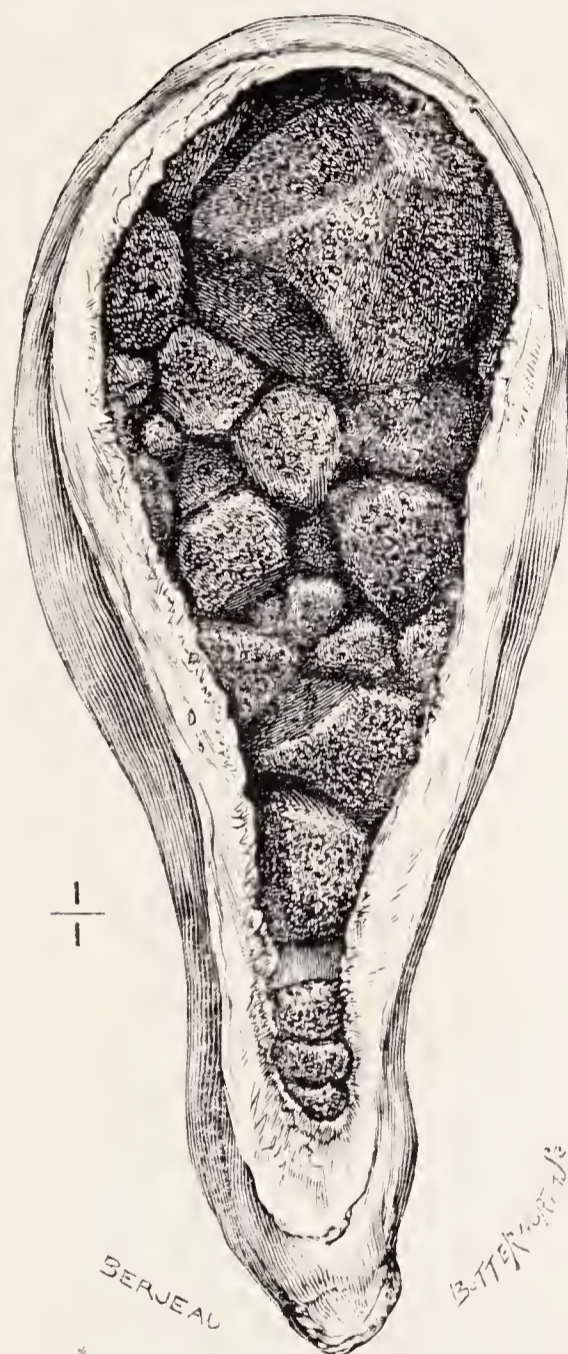


FIG. 27.—A gall-bladder contracted on a group of calculi of irregular shapes and sizes.

fair size each, may be lodged in a recess and produce a multilocular arrangement. Naunyn describes this process as “encapsulation,” and it indicates that a gall-bladder loculated in this way has been the seat of chronic cholecystitis.

A careful distinction must be made between gall-stones encapsuled as a result of contraction changes in the gall-bladder and those lodged in a diverticulum.

Gall-stones in diverticula.—It has been pointed out that gall-stones lead to ulceration of the gall-bladder, which may end in perforation of its walls with extrusion of the calculi into the peritoneal cavity or into an adjacent viscus. In some cases, however, the mucous membrane will be ulcerated through, but not the muscular coat, and the stone may come to lie in a sacculus between the mucous and muscular coats, and in course of time the orifice of communication between the sacculus or diverticulum may become very narrow, or even obliterated. Diverticula of this kind may form in any part of the excretory apparatus of the liver, but they appear to be more common in connection with the neck of the gall-bladder and the cystic duct. Saccular pouches of this kind may burrow into the substance of the liver.

In regard to diverticula connected with the gall-bladder, it is necessary to distinguish between a stone in an adventitious saccule and a loculus due to contraction. I examined a museum specimen supposed to represent gall-stones in a diverticulum in the liver-substance, but they were really calculi in a loculus of a bilocular (hour-glass) gall-bladder.

Diverticula of the gall-bladder or the bile-ducts

are rare, but they produce puzzling conditions which are apt to embarrass an operator when he has to deal with them.

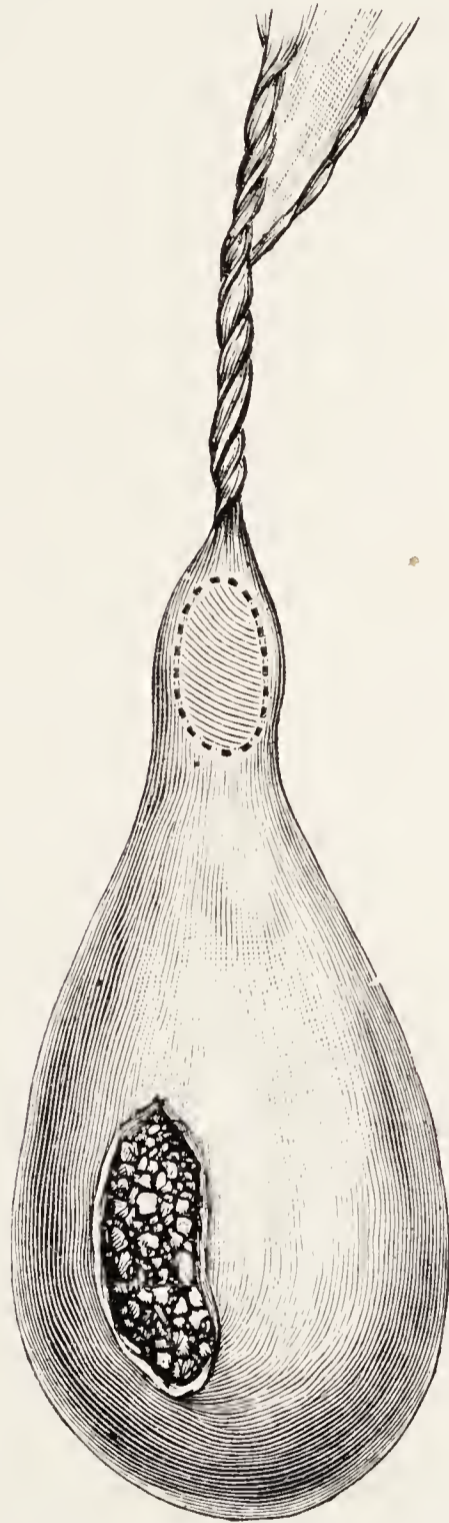


FIG. 28.—Gall-bladder with a long cystic duct which had undergone axial rotation. (After Wendel.)

Axial rotation of a calculous gall-bladder.—Like the viscera in the abdomen generally, the gall-bladder is liable, in very rare circumstances, to rotate and twist its pedicle.

In an example of this condition recorded by Wendel the patient, a woman aged twenty-three years, was seized suddenly with severe pain in the right iliac region and symptoms indicative of appendicitis. She refused surgical aid, but some months later the condition was such as to lead her to submit to operation. The gall-bladder was found in the right iliac region; its wall was perforated, and it contained 213 gall-stones. The cystic duct measured $3\frac{1}{4}$ in. from the free border of the liver to the neck of the gall-bladder, and was "very much twisted" (Fig. 28). The perforation in the gall-bladder had given rise to a localised intraperitoneal abscess. The patient recovered.

Lett removed from a woman aged seventy-two years an enlarged gall-bladder, which had undergone axial rotation and twisted its cystic duct through four and a half turns. She was admitted into the London Hospital on account of sudden acute pain in the right hypochondrium. She died twelve hours after the operation. The gall-bladder was completely covered by peritoneum; it was attached to the liver by a narrow mesentery, which left the gall-bladder near its neck.

Spontaneous fracture of calculi in the gall-bladder.—Cases have been reported in which gall-stones have been found broken up in the gall-bladder. No satisfactory explanation has been advanced to explain this condition, and it has been assumed

that the phenomenon is capable of explanation on the same grounds as the spontaneous fracture of calculi in the urinary bladder is explained by Ord and Plowright. The condition is curious, but of no importance. The chief reported cases have been collected by Rolleston.

Gall-stones in the cystic duct.—In the normal condition it is easy to distinguish the neck of the gall-bladder from the cystic duct; but in diseased conditions when a stone is impacted in this duct the parts behind are often so dilated that it is impossible to draw a dividing line between the duct and the gall-bladder. In normal conditions the cystic duct measures in transverse diameter 3 mm., and its lumen is irregularly encroached upon by the fold of its mucous membrane, known as the valves of Heister. No very accurate statements can be made in regard to the size of concretions which are able to pass along this duct, and I have, on several occasions, found it absolutely obstructed by a calculus the size of a cherry-stone.

There is a very characteristic form of gall-stone which is found in a very dilated cystic duct; it occurs in sets of three; the middle one is faceted at each end, which causes it to resemble a beer-cask. These large calculi are always bile-stained, which serves to show that though big and situated in a widely dilated duct they probably allow a small amount of bile to trickle past them. This may

also account for their size, for if the duct will not admit anything exceeding the dimensions of a cherry-stone, it is certain that calculi as big as cherries could not enter it. The inference is obvious

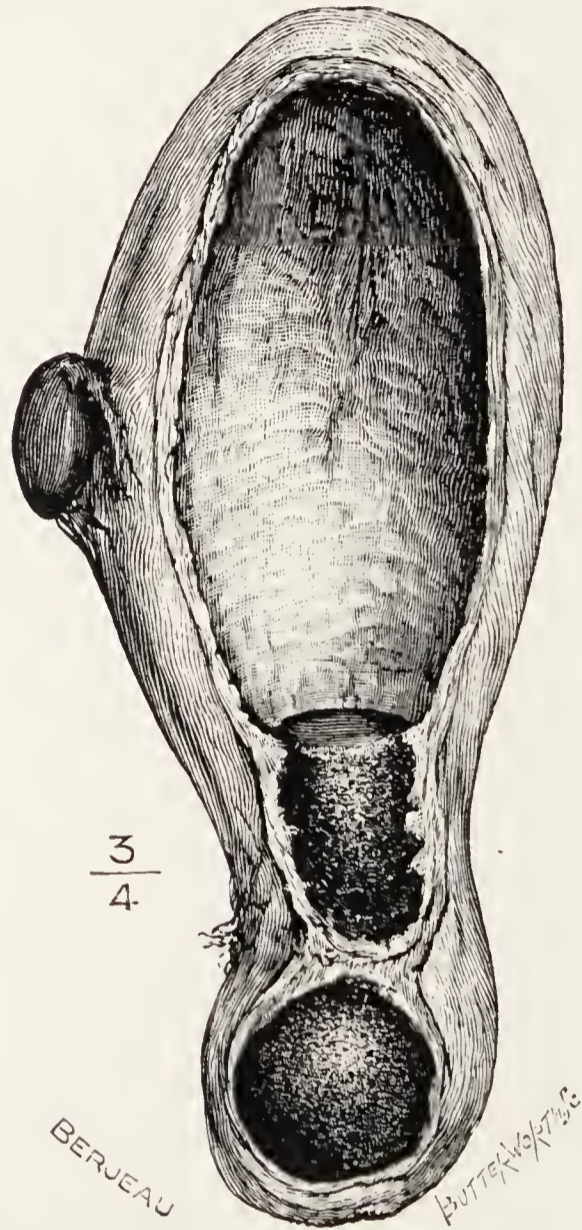


FIG. 29.—Gall-bladder with gall-stone impacted in the cystic duct. The small body on the gall-bladder is an accessory liver.

that small calculi find their way into the duct and gradually increase in size.

A calculus impacted in the cystic duct may cause the gall-bladder to become so big as to simulate a large hydronephrosis, or an ovarian cyst.

For example, Lawson Tait removed a large gall-bladder which contained nearly eleven pints of gluey fluid under the impression that it was a big

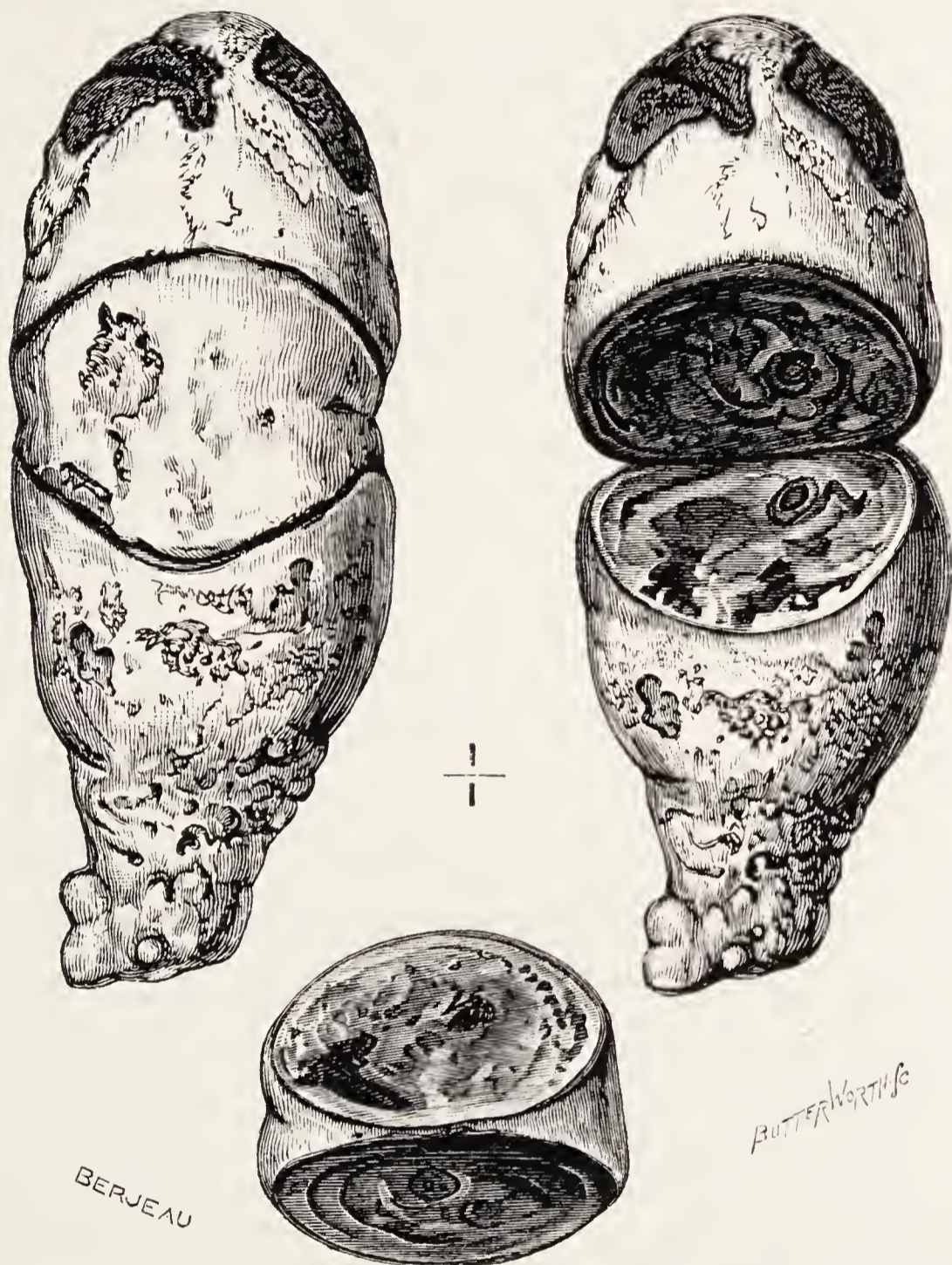

FIG. 30.—Three gall-stones which were passed at intervals with the faeces in the following order: (1) The conical piece; (2) the central wedge; (3) the stalk-like portion. The three pieces represent a cast of the gall-bladder, and the calculi probably ulcerated into the transverse colon. (The specimen was presented to the Museum of the Middlesex Hospital by Dr. Murchison.)

parovarian cyst, the obstruction was due to a calculus in the cystic duct.

Collinson removed from a woman aged thirty-one years a gall-bladder, which had been twice tapped, and twenty-five pints of fluid were withdrawn on each occasion. When removed it contained twenty-two pints of thick gamboge-coloured fluid.

Terrier removed from a woman aged fifty years a gall-bladder containing forty-two pints of a similarly coloured fluid.

It is when occupied by large stones and thus widely dilated that the cystic duct sometimes adheres to, and subsequently communicates with, the stomach (cysto-gastric fistula), with the duodenum (cysto-duodenal fistula), or with the transverse colon (cysto-colic fistula) as a result of ulceration.

It is a matter of common observation that gall-stones are often found in the gall-bladder after death which gave no sign of their existence during life. It is also equally common in conducting *post-mortem* examinations, as well as in the course of an abdominal operation, to find that an unsuspected gall-stone was the cause of the trouble.

It will be useful to describe some of the many curious ways in which gall-stones set up pathologic changes.

Biliary fistulæ.—A gall-bladder containing calculi may become infected from the duodenum by way of the common and cystic ducts. So long as these channels remain unobstructed and the inflammatory fluids can freely drain away there is rarely much

BILIARY FISTULÆ

harm; but should a gall-stone move into the cystic duct and block it, the inflammatory products no longer flow away but accumulate in and distend the gall-bladder, and if the infecting micro-organisms are of a virulent strain the gall-bladder will fall into a condition of acute inflammation. Its walls become red, œdematous, and quickly contract adhesions to surrounding structures, such as duodenum, colon, stomach, jejunum, omentum, or the anterior abdominal wall.

If unrelieved by surgical art, the sequence of events may be one of the following:

The walls of the gall-bladder may slough and the purulent contents with the gall-stones may escape into the belly with deadly results. When a gall-stone ulcerates through the wall of the gall-bladder and an adjacent viscus, it finds its way usually into the duodenum, and, as a rule, near the pylorus; occasionally it ulcerates into the transverse colon, and very rarely into the jejunum. There are some carefully described cases on record in which the perforation occurred into the stomach.

In Chapter VIII attention is especially directed to the intimate relationship of the gall-bladder to the first portion of the duodenum, and I have made some observations which serve to show that the gall-bladder and the pyloric section of the stomach are occasionally very closely associated. In one case under my care a woman had an hour-glass stomach

with a large hole in the isthmus plugged by a long, attenuated gall-bladder with a gall-stone as big as a cherry in its fundus ; I could not determine whether the hole was due to a gall-stone ulcerating into the stomach or a perforating ulcer of the stomach luckily plugged by a calculous gall-bladder.

On another occasion I found a pyloric ulcer, probably malignant, with the gall-bladder incorporated with it and forming its base.

Galliard has studied obstruction of the pylorus by gall-stones : he points out that the condition is rare. The obstruction may be due to a gall-stone ulcerating into the stomach and then becoming impacted in the pylorus. In another class of case the gall-bladder becomes adherent to the pylorus, and the adhesions and dragging of the stomach lead to constriction of the pyloric orifice. Of this I have seen three examples and relieved the patients by means of an operation.

Fortunately, the wall of an inflamed gall-bladder or the cystic duct often adheres to a neighbouring viscus, so that when perforation occurs the wall of the adherent viscus is also perforated, the gall-stones and pus being extruded into duodenum, colon, or stomach as the case may be : these adventitious openings are known as "internal biliary fistulæ." Such an accident is followed by abatement of the symptoms, and if the gall-stones are of moderate size their evacuation through the anus occurs in due course. With some frequency the calculi when

discharged through an internal biliary fistula in the duodenum or jejunum are too large to traverse the ileum and they set up intestinal obstruction of an acute and highly dangerous kind (Chap. VIII).

In a certain proportion of cases of inflamed gall-bladder the point of perforation occurs where it is in relation with the parietal peritoneum. This leads to the formation of an abscess, which will involve the anterior abdominal wall and eventually burst through the skin, the gall-stones escaping externally with the pus.

It is a point to remember that when the gall-bladder perforates into a hollow viscus the fluid contents escape, and if the calculi be multiple some of them leave it also. A solitary stone may also be extruded but not invariably, and it will be necessary to point out that this natural form of relief to an inflamed and calculous gall-bladder rarely benefits the patient. The results which follow are of great interest and deserve careful consideration by surgeons who have to deal with the complications.

When the adhesion of the gall-bladder to the intestine is not complete or is unstable the calculus may find its way into the gut, but the pus leaks into the peritoneum and sets up peritonitis, local or more often general. Cases have been reported in which a gall-bladder has perforated the gastrointestinal tract in three situations—stomach, duodenum, and colon (Voelcker).

The gall-bladder may thoroughly evacuate itself of fluid and calculi, the hole in the duodenum closes, and the gall-bladder shrivels up ; this process may lead to contraction of the intestine so as to cause interference with the flow of gastric contents into the duodenum.

Rarely the pus perforates the wall of the gall-bladder where it abuts on the liver and sets up a large hepatic abscess. It is often hastily assumed when a person passes a gall-stone after an attack of biliary colic that the calculus has traversed the common bile-duct and entered the duodenum, following the normal course of the bile. This can only happen when the gall-stone is small. Very few writers have directed attention to the probable limits of size which permit a gall-stone to enter the duodenum through the terminal section of the bile-duct. Operative experience teaches very clearly that calculi find their way into the intestinal tract through adventitious fistulæ very often. In a large proportion of patients submitted to operation for cholelithiasis with a history of having passed gall-stones the gall-bladder will be found adherent to the neighbouring viscera ; the adhesion may be sessile and very intimate, or funnel-shaped ; great care is necessary in dealing with such adhesions, for a small channel or fistula may still exist and maintain communication with the intestine, and if it be opened and overlooked in the course of the operation it will leak and set up fatal peritonitis.

External biliary fistulæ.—The spontaneous escape of gall-stones through the anterior abdominal wall has been known for centuries. As a rule, an abscess forms in the neighbourhood of the umbilicus, usually above and a little to the right of it; or near the groin; or in the neighbourhood of the ensiform cartilage; the abscess bursts spontaneously, or it is opened by a scalpel and pus and gall-stones escape. There is rarely a flow of bile, owing to the occlusion of the cystic duct. The sinus continues as long as gall-stones remain in the gall-bladder; it is therefore necessary to thoroughly remove the calculi from the gall-bladder and the sinus quickly closes. In one case the escape of two gall-stones through a sinus in the epigastrium was followed by a fistula into the duodenum, and food taken by the patient flowed through the sinus. The patient died of inanition (Alexander and Irvine). In this instance the patient had an internal as well as an external biliary fistula.

The frequency with which an external biliary fistula opens near the navel may be due to the fold of peritoneum known as the falciform ligament, conducting the pus in that direction.

Although gall-stones are common, perforation of viscera by these bodies is not a very common event, and even in the course of a long professional life, though a surgeon may see a fair number of these accidents, no single experience is sufficient to allow

of any positive statement in regard to their relative frequency; for this purpose it is necessary to fall back on statistics. These have been diligently compiled by several writers, including Roth, Courvoisier, Naunyn, and Schroeder.

It is stated that gall-stones have made their way into the pregnant uterus and been discharged through the vagina. This is probably as apocryphal as the statement that Realdus Columbus found three gall-stones in the portal vein of Ignatius Loyola; they were probably lying in the common bile-duct.

Gall-stones in the Meckelian diverticulum.—Sherren reported the case of a butcher aged thirty-eight years who was admitted into the London Hospital with acute abdominal symptoms: on opening the abdomen he felt what appeared to be a gall-bladder full of stones, but when the parts were examined it proved to be a Meckel's diverticulum containing concretions. The gall-bladder was normal. The diverticulum (Fig. 31) was removed, and its communication with the gut closed with sutures: the man recovered and was in good health two years later. The concretions consisted of cholesterin, calcium oxalate, and traces of bile-pigment. Sherren is doubtful that the concretions were gall-stones. Collections of cholesterin form in any cavity lined with mucous membrane when it is the seat of chronic inflammation, and Sherren believes that the concretions were formed

in this way in his patient. He gives references to similar cases reported by Beale, Forque et Riche, Hollander, and Znojensky.

Lediard has reported a case in which he removed a **vermiform appendix** containing eleven small stones, "of varying sizes, from that of a pea to that of a

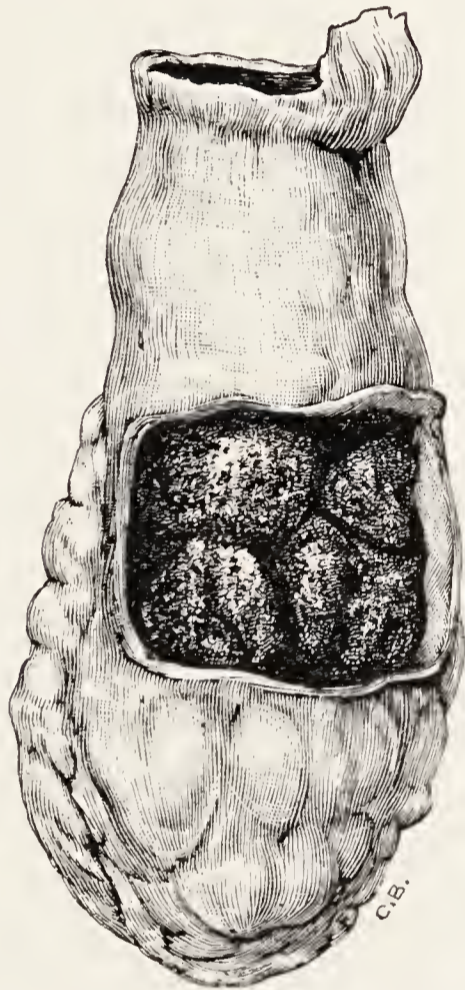


FIG. 31.—A Meckel's diverticulum containing concretions; it communicated with the lumen of the ileum by a narrow opening protected by a valve. (After Sherren.)

pin's head." They consisted of cholesterin and bile-pigment.

Gall-stones in the urinary tract.—Fauconneau-Dufresne has reported a case in which gall-stones were voided with the urine, but it does not rest on any *post-mortem* evidence that there was a fistula between the gall-bladder and the renal pelvis.

Littler Jones operated on a patient whose gall-stones were extruded through a hole in the gall-bladder and collected in a large perinephric abscess. This abscess opened into the pelvis of the kidney, some of the stones being passed out of the body through the urinary tract, others being removed at the time of the operation.

Michel reported a case of great interest, in which a spinster, aged twenty-nine, exhibited definite signs of gall-stone colic, followed by symptoms of peritonitis in the right half of the abdomen. Later the woman suffered with vesical symptoms. Three years after the attack of cholecystitis, four stones were removed from the urinary bladder by vaginal cystotomy. These concretions were faceted and had the appearance of gall-stones, and yielded cholesterin on examination. Michel thought it probable that a communication existed between the gall-bladder and the urinary bladder, for bile was discharged with the urine before and after operation without the co-existence of jaundice. The calculi are figured in the original communication.

REFERENCES.

- Alexander and Irvine**, "Remarkable Case of Fistula."—*Med. Times and Gazette*, 1876, 11, p. 202.
- Bland-Sutton, J.**, "On Some Cases of Gall-stones."—*Clinical Journal*, 1906, xxix, p. 17.
- Collinson, F. W.**, "A Case of Very Large Gall-bladder successfully Treated by Excision."—*Brit. Med. Journ.*, 1909, i, p. 1294.

- Doran, A.**, "Dilatation of the Gall-bladder simulating Ovarian Cyst."—*Brit. Med. Journ.*, 1905, i, p. 1316.
- Fauconneau-Dufresne, V. A.**—*Maladies du Foie*, 1856, p. 345.
- Jones, T. C. Littler**, "Suppurative Cholecystitis."—*Brit. Med. Journ.*, 1907, i.
- Lediard, H. A.**, "Gall-stones in the Appendix."—*Lancet*, 1907, i, p. 83.
- Lett, H.**, "Two Unusual Conditions of the Gall-bladder."—*Lancet*, 1909, i, p. 1099.
- Michel, F.**, "Gallensteine in der Harnblase."—*Zentralb. für Gynäk.*, 1909, xxxiii, p. 25.
- Sherren, J.**, "Meckel's Diverticulum containing Calculi and producing Colic."—*Proc. Roy. Soc. Med.*, 1909, Clinical Section.
- Tait, Lawson**, "The Surgery of the Liver."—*Edin. Med. Journ.*, 1889, vol. xxxv, Part I, p. 305.
- Terrier**, "Dilatation considérable de la vésicule biliaire."—*Bull. de l'Acad. de Méd.*, 1890, xxiv, p. 831.
- Yoelcker, A. F.**, "Biliary Fistulæ opening into the Pylorus, Duodenum, and Transverse Colon."—*Path. Soc. Trans.*, 1895, xlvi, p. 78.
- Wendell, A. V.**, "A Case of Floating Gall-bladder complicated by Cholelithiasis with Perforation of the Gall-bladder."—*Annals of Surgery*, 1898, xxvii, p. 199.

CHAPTER VII

THE CHANGES GALL-STONES PRODUCE IN THE BILE-DUCTS

IN the preceding chapter it was stated that the gall-bladder is the common source of gall-stones, but it is equally certain that they are formed in the common bile-duct, the hepatic duct, and the intra-hepatic ducts.

It is also reasonable to believe that the nuclei of some gall-stones of the common duct are formed in the gall-bladder and find their way down the cystic into the common duct, and there grow into calculi of troublesome dimensions.

The gall-bladder often contains minute calculi resembling shot, and some find their way with the bile down the ducts, and enter the duodenum: such are occasionally detected in the fæces. Should one or more of these concretions be detained in the common duct they would serve as nuclei for large calculi, much in the same way that a renal calculus, after descending the ureter, may be arrested in the bladder, and form the kernel of a large vesical stone. The point of arrest of a gall-stone in the

common duct is also determined by its size at the time of escape from the cystic duct, for it is a matter of common observation that the largest stones found in the main duct are not at the ampulla but in the supraduodenal portion, where the lumen of the duct is wider than elsewhere. I have removed a gall-stone from this part of the common duct of the size and shape of a dove's egg, but in the ampulla I have never found a calculus larger than a cherry-stone.

The disturbances which follow the formation of a stone in the common duct depend on the size of the stone and its situation in the duct. These are matters of clinical importance, because the careful consideration of them is in a measure the key to the proper interpretation of the symptoms, which, expressed in clinical terms, means diagnosis.

The changes produced by a gall-stone in the main ducts are similar to those which follow the impaction of a calculus in the ureter: they are various, not only in regard to the effects produced on the ducts, but also those it induces on the gall-bladder, the intrahepatic ducts, and the proper tissue of the liver. The nature of the changes will vary according to whether the obstruction is partial or complete.

The obstruction is incomplete.—It is important to realise that a gall-stone in the common duct rarely blocks it absolutely. When a calculus is too large to pass through the duct it hinders the free passage of bile and causes it to accumulate behind the obstruc-

tion and dilate the duct. This increase in the lumen of the duct allows the stone a certain amount of freedom, and there are periods when bile flows around the obstruction and reaches the duodenum; at other times the stone will be forced like a plug into the narrow part of the duct, and the obstruction will be for a while complete. The intensity of the jaundice will, in these circumstances, act as a gauge and afford information concerning the degree of obstruction caused by the calculus. This variation in the blockading action of a gall-stone is sometimes likened to a ball-valve (Fenger). It is probable that the obstruction caused by a gall-stone in a dilated common duct depends on another change besides that of position and mobility of the stone. The presence of a gall-stone in the common duct is associated with inflammatory changes in the walls of the duct (cholangitis), and the incidence and remission of the inflammation may largely influence its mobility. This probably applies more particularly to the duct when it contains many gall-stones.

So far we have discussed the question as if the common duct contained a solitary gall-stone; but a dilated bile-duct may contain many calculi, and between them there may be a fair amount of biliary sand or gravel, and through this, bile makes its way like a rill along a pebbly channel. In other instances the duct may be filled with a muddy paste of inspissated bile, cholesterin, and pus.

Gall-stones in the common bile-duct not only cause dilatation of the duct, but this condition often facilitates the ingress of septic micro-organisms from the duodenum, which sets up septic cholangitis. Infection in this way may lead to ulceration of the bile-duct at the spot where the stone presses on the duct, which may ultimately lead to perforation. When this occurs the pus may give rise to a local abscess or establish a subphrenic abscess. Actual observations in which gall-stones have been caught, so to speak, in the act of perforating the common duct are few. Eve was fortunate in this respect, for whilst engaged in evacuating an abscess from the gall-bladder region in a deeply jaundiced woman he detected a perforation in the supra-duodenal section of the common bile-duct; he enlarged the opening and "extracted a gall-stone as large as a marble," and saved his patient.

The obstruction is complete.—In describing some of the consequences of calculi in the gall-bladder it was pointed out that they are often extruded into the duodenum through an adventitious opening, and that this event has been amply demonstrated in many *post-mortem* examinations, as well as by specimens exhibited in many museums. It is natural to believe that occasionally stones in the common duct may find their way by ulceration into the second part of the duodenum. It is difficult to prove this owing to the fact that such an event would be most

favourable for the patient, and the perforation in the duodenum would very rapidly heal and efface itself.

Naunyn is very explicit in relation to cholecho-duodenal fistula; indeed, he speaks of it as a common event, and he states that a fistula of this kind is sometimes erroneously regarded as a dilated duodenal ostium. He also refers to cases in which a calculus incarcerated in the common duct has led to the formation of a fistula, allowing the bile to escape into the intestine, but not big enough to permit the stone to pass through.

It is the formation of such adventitious outlets for the bile, as well as the often incomplete blockade of the common bile-duct by gall-stones, which explains the important fact that uncomplicated jaundice due to gall-stones is rarely fatal.

Among the rarer consequences of gall-stone abscess of the common duct may be mentioned perforation of the hepatic artery (see "Aneurysm of the Hepatic Artery," p. 37).

Inflammation and suppuration in and around a calculous common duct may lead to thrombosis of some of the large veins in its neighbourhood, such as the portal vein, the vena cava, and the radicles of the azygous veins. Thrombosis of the portal vein may lead to suppurative pylephlebitis, and some of its more serious consequences, hepatic abscess or multiple foci of suppuration throughout the liver,

which are invariably fatal. The formation of septic clot in the radicles of the azygous veins is also a serious sequel, for the clot occasionally becomes detached and deported into the lungs, an event which is often followed by sudden death and occasionally by septic pneumonia, with its unpleasant and serious sequelæ.

Apart from the simple present effects resulting from the accumulation of bile behind a gall-stone obstructing the common duct, we have to study the curious and, in a manner, unexpected effect it exercises on the gall-bladder. When the flow of bile from the common duct is completely arrested by primary cancer of the pancreas involving it, the bile-ducts and the gall-bladder become dilated in response to the pressure of the bile they contain, and in these circumstances the gall-bladder becomes enlarged, and is often easily felt as a large pear-shaped tumour in the right lumbar region. So, too, when the cystic duct is obstructed the gall-bladder passively dilates under the pressure exerted by the accumulation of its own mucus. On the other hand, when the common duct is occupied by calculi the gall-bladder is usually found atrophied, and if it contains gall-stones it is, as a rule, tightly contracted on them. In some instances the cicatricial condition is so marked that the gall-bladder may completely disappear or be represented by a fibrous cord, which may sometimes contain an embedded or

sequestered gall-stone. We are indebted for this observation to Courvoisier. These opposite conditions may be briefly expressed in this way :

(A) *Progressive jaundice with dilatation of the gall-bladder indicates cancer in, or around, the termination of the common bile-duct.*

(B) *Intermittent jaundice and contraction of the gall-bladder indicates cholelithiasis.*

This great difference in the result of obstruction under the two conditions is due to inflammation of the ducts (cholangitis) and gall-bladder (cholecystitis), set up by bacterial infection of the ducts.

It is, however, a common event to find the main bile-duct behind an impacted stone dilated to such an extent that it will admit the index finger, and this distension extends to and involves the hepatic and intrahepatic ducts, and if the obstruction is fairly complete and of long duration the dilatation may be very extensive.

Moreover, the dilatation of the common bile-duct has in some cases been so great that it resembled a cyst, and in some instances has been mistaken for an enlarged gall-bladder, and has been opened and the edges stitched to the skin under this impression.

It is stated on p. 16 that when the flow of bile along the common duct is completely stopped by an obstruction of any kind the bile is drained by the lymphatics of the liver into the circulation, and it is eliminated by the kidneys. In the early days

of the obstruction, if the common bile-duct be exposed and incised in the course of an operation it will be found distended with bile. When the blockade of the duct has been maintained many weeks (six or more) it happens now and then that the duct no longer contains bile, but a colourless fluid, probably mucus. This is a sinister sign, for surgeons who have had a wide experience of what is conveniently called "gall-stone surgery" state that in these circumstances the patients almost invariably die shortly after operation. My observations agree with this.

The effects just described follow the retention of gall-stones in any part of the common duct, but when the stone is lodged in the ampulla the consequences may be more complicated, because in this situation it may interfere with the outlet of the pancreatic duct. The complications which may arise in the pancreas secondary to the presence of a calculus in the ampulla are sufficiently important to require separate consideration (Chap. XI).

There is a rare condition associated with the impaction of a gall-stone in the ampulla shown in Fig. 32, namely prolapse of the terminal section of the duct into the duodenum. This is similar to the prolapse of the vesical segment of a ureter into the bladder when a renal calculus is too large to pass: in some instances the ureter with the contained calculus has been known to protrude at the urethra in the case of girls and women. It is certain

that a stone impacted in the ampulla as in this specimen would block the pancreatic duct also.

In a patient recently under my care with chronic obstructive jaundice, I performed choledochotomy,

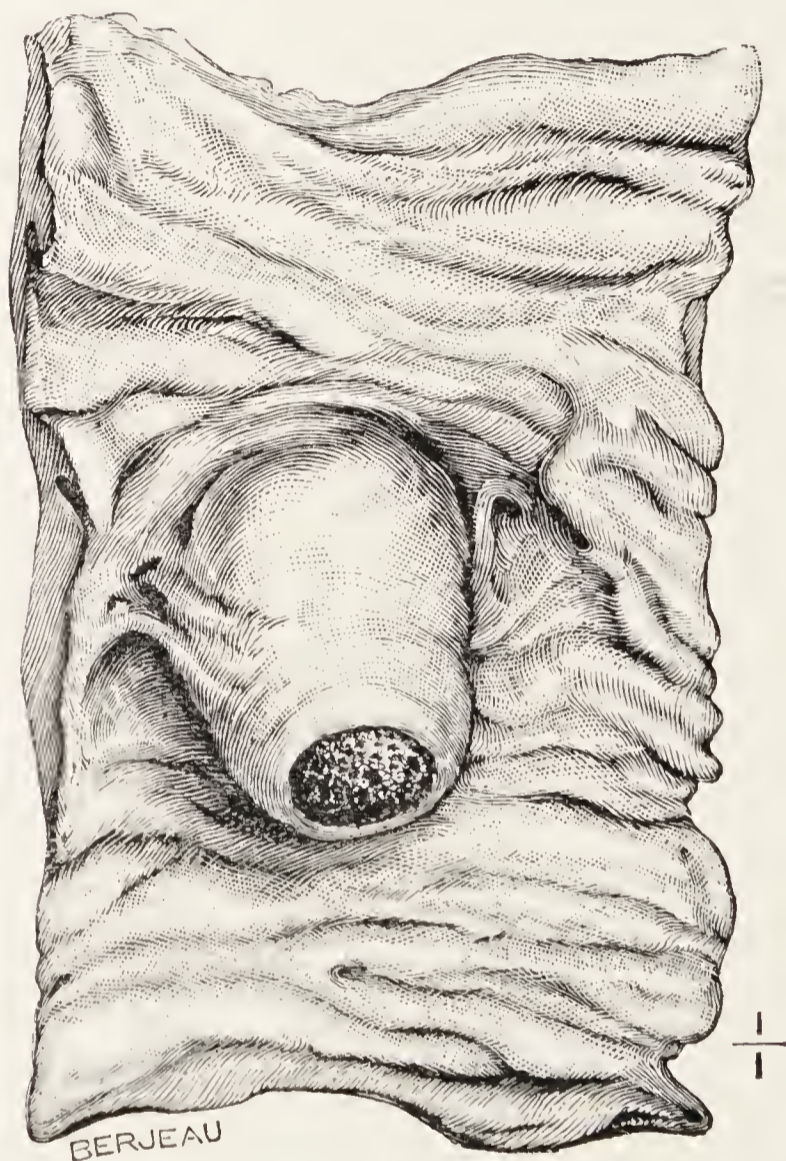


FIG. 32.—Second portion of the duodenum laid open to show a gall-stone impacted in the ampulla of the common duct. From a woman aged seventy years (Museum, Royal College of Surgeons).

and felt a large stone in the duct where it was connected with the duodenum. When the duct was exposed I could feel a concretion as big as a cherry-stone, but failed to feel the big stone. I opened the duct, removed three stones, and after carefully

exploring the ducts with a probe closed the wound with drainage.

The patient died the next day : at the *post-mortem* examination a large hole was found in the terminal section of the duct (Fig. 33). The large stone I

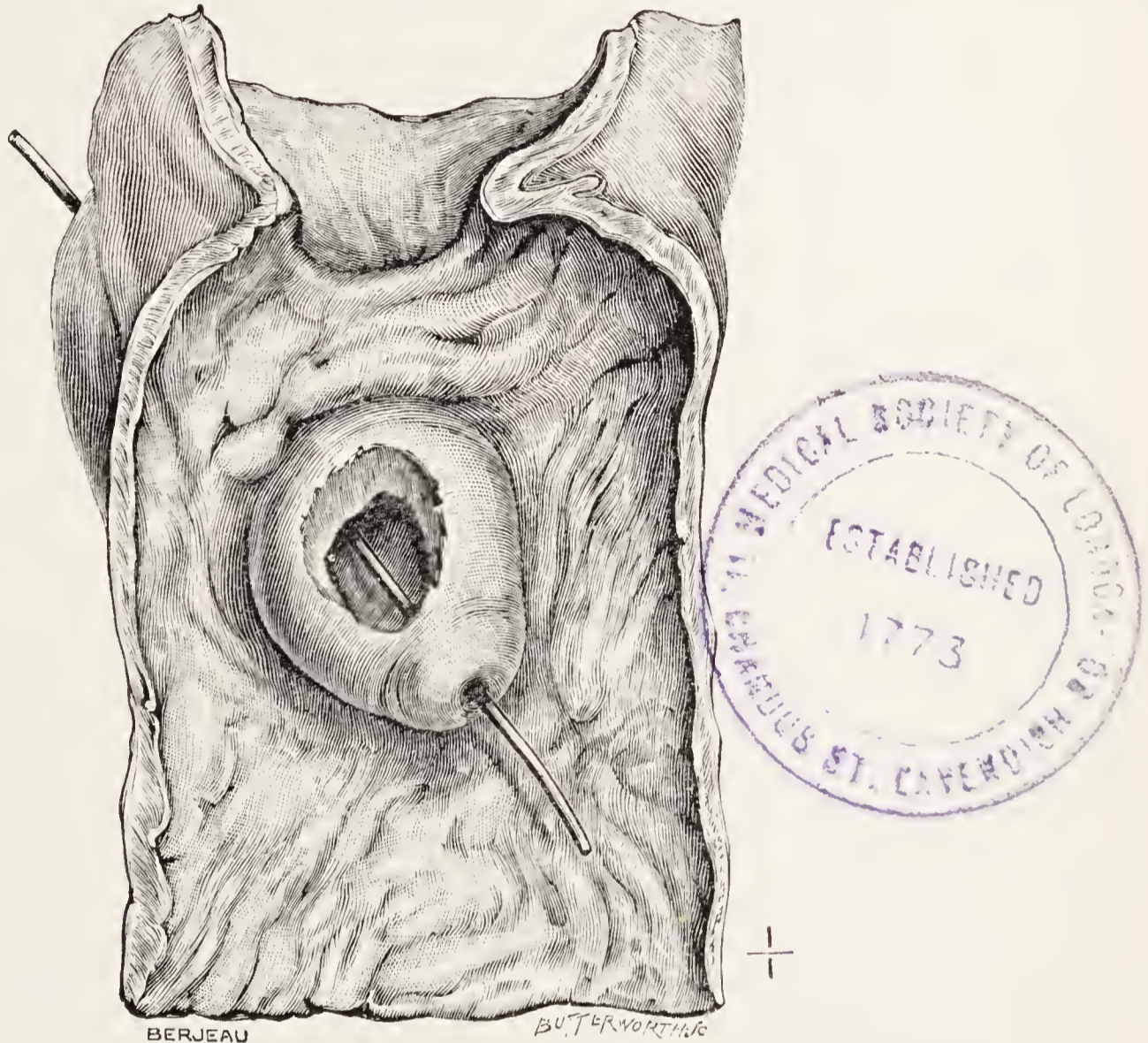

FIG. 33.—The first and second portion of the duodenum laid open, showing an enlarged ampulla of the common bile-duct. A gall-stone which had been long impacted there has ulcerated through its walls.

felt in the course of the operation had ulcerated through the wall of the duct and my manipulation had dislodged it.

Biliary abscess, secondary to gall-stones.—Obstruction of the main bile-ducts, especially by gall-stones,

favours the entrance of pathogenic micro-organisms into the dilated bile-duct ; as a consequence pus is formed in the dilated portions of the ducts, and, if it were possible to make a continuous section of an intrahepatic duct in this condition, it would resemble a stream with numerous pools or ponds in its course. To-day this condition is called suppurative cholangitis. Rogers has recently published an important paper on this disease, and among other valuable observations points out that complete obstructive jaundice is always present in the earlier stages of the disease ; this is followed by the re-appearance of bile in the fæces in small quantities and a decrease in the jaundice, but an increase in the fever accompanied with rigors.

The diagnostic difficulties in this disease are clearly indicated by the statement of Rogers that in twenty cases collected by him the condition was not diagnosed. Out of twenty cases, gall-stones were present in the ducts in eighteen, hydatids in one, and cancer of the gall-bladder in another.

Abscess of the liver as a sequel of gall-stones is much more likely to arise when these bodies obstruct the common duct, and in these circumstances, as Rogers points out, the nature of the case is apt to be overlooked. In some instances, as in a case described by Bristowe, the collections of pus contained in dilatations of the intrahepatic ducts will ulcerate into the adjacent branches of the portal vein.

We must not forget that a calculus in the common duct may give rise to a choledocho-duodenal fistula, and an abscess associated with such a sequel may involve the liver or set up a subphrenic abscess. It may, as in a case described by Bristowe, open into the colon as well as the duodenum.

These complications of gall-stones in the common duct are, fortunately, infrequent, for they run a tedious course, do not give good results to surgery, and are invariably fatal.

Gall-stones in the hepatic duct.—It is not unusual to find stones in the hepatic duct when the common duct also contains gall-stones, but it is rare to find gall-stones in the hepatic duct when the other excreting conduits are free from concretions. It is possible for a gall-stone to form in the hepatic duct as in any other duct in the liver, and it is usually of the bilirubin-calcium variety. A solitary stone has been found, but more commonly they are multiple. When the hepatic ducts are occupied by calculi and the common bile-duct and gall-bladder are free from them it is usual to find concretions in the intra-hepatic ducts (bilirubin-calcium).

It is also possible that when the common duct is occupied by gall-stones and the hepatic duct is widely dilated, a stone escaping from the cystic duct may find its way into the hepatic duct and serve as the nucleus for a large calculus.

A gall-stone, or a nest of gall-stones, in the

hepatic duct will give rise to symptoms like stones in the common duct, and it is possible in conditions of this kind for an operation to be performed and the stone missed.

Suppuration occasionally occurs behind a stone in the hepatic duct, and the intrahepatic ducts become distended with pus.

Another rare condition is rupture of the hepatic duct in consequence of ulceration caused by the stone. In a case of this kind described by Freeland the accident was quickly fatal, and at the *post-mortem* examination the belly was full of blood and pus.

Gall-stones in the intrahepatic ducts.—Large calculi in the intrahepatic ducts are uncommon, but they occur, and are sometimes very numerous. They are generally of the bilirubin-calcium kind, and are usually of irregular shape, like fragments of coral.

There is a remarkable specimen in the museum of the Pathologic Institute in Berlin. The liver is large, and the cut surface shows the calculi as thick as plums in a cake. The Museum of Westminster Hospital possesses a slice of a liver with dilated intrahepatic ducts containing black coral-like gall-stones. To my mind these rounded and slightly curved intrahepatic calculi resemble large woodlice lying under the bark of a decaying tree. In this specimen the dilatation of the ducts was attributed to pressure exerted on the hepatic duct by an echinococcus cyst in the transverse fissure of the liver.

It was pointed out in Chap. V that in their early stages gall-stones are soft and plastic; this is cer-

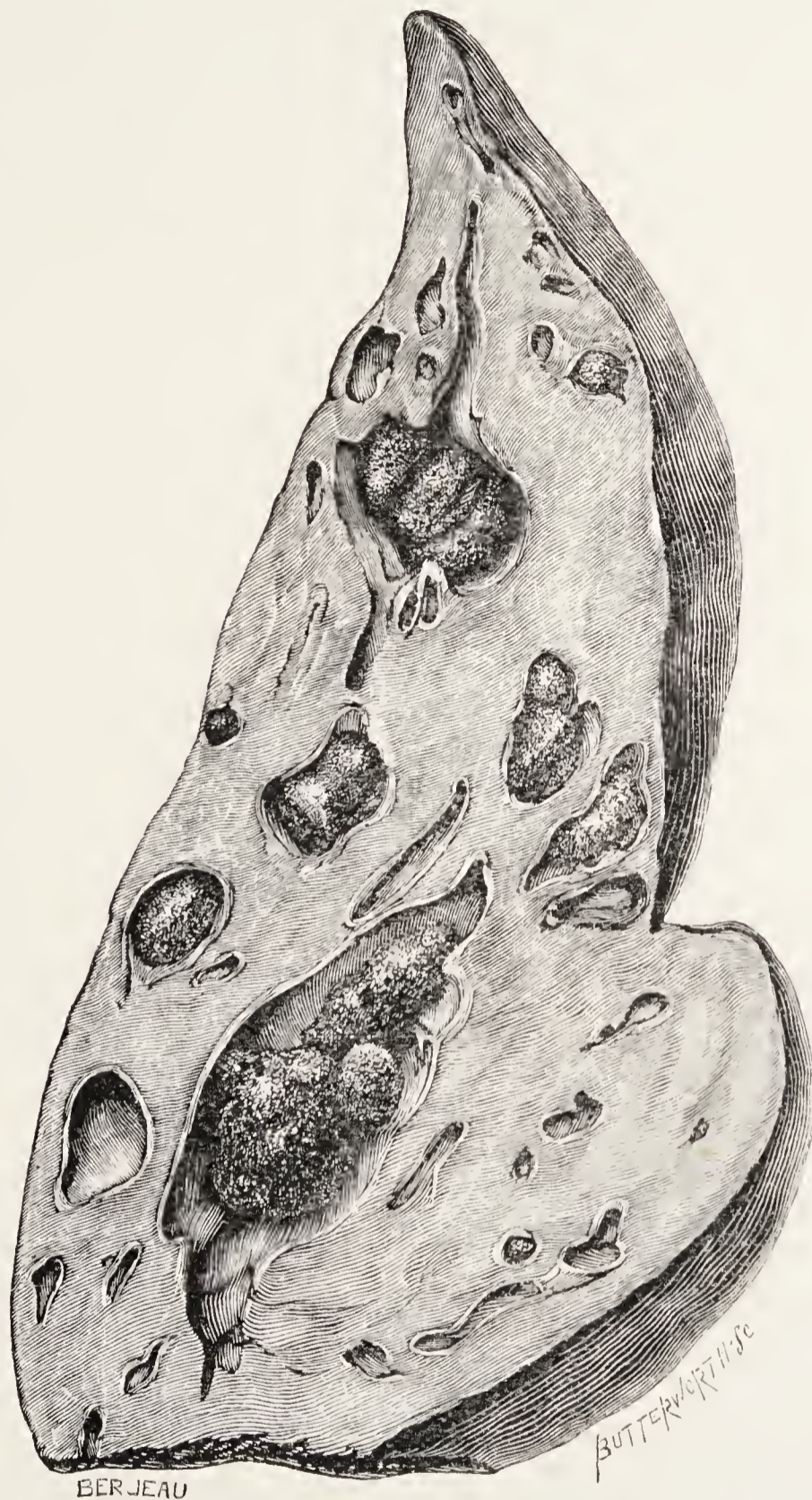

FIG. 34.—A section of liver with dilated ducts containing gall-stones (from a photograph supplied to the author by Dr. Mitchell Stevens).

tainly true of those which arise in the intrahepatic ducts, for they take the form of the ducts in which

they lie, and as the large bile-ducts follow meandering courses in the liver, the gall-stones mould themselves to the various curves; the small nodules on their contour correspond to the oscula of the bile-canals which open into the dilated channels which lodge the stones. These facts explain the curved shape they often possess and their rugged coralline exteriors.

Intrahepatic gall-stones may be very numerous, for in a case recently reported, the liver of a man aged fifty-two years contained 520 calculi distributed through its ducts. "The calculi were of all shapes and sizes and many were faceted." They were composed of cholesterin and bilirubin-calcium. The gall-bladder was of normal size, free from gall-stones or any trace of inflammation, but the cystic duct was occluded. The hepatic duct and adjacent portion of the common duct were greatly dilated and resembled a gall-bladder; this dilatation contained 100 calculi.

There was a large abscess on the dome of the liver from which the *Bacillus coli* was obtained (H. R. Vachell and Mitchell Stevens).

Forbes Hawkes reported a case in a man aged twenty-six years, and he succeeded in removing four intrahepatic calculi; the man recovered.

A glance at specimens of liver with multiple intrahepatic calculi is sufficient to indicate the impotence of surgical skill, or medical art to deal with the condition.

Perhaps the most striking fact connected with these cases of multiple calculi in the intrahepatic ducts is the little inconvenience they cause during their formation. Cruveilhier refers to this in association with the remarkable specimen to which he devotes a whole plate (V) in the 12th Livraison of his great work; and he remarks, as so many surgeons have also noticed, that a small gall-stone in the terminal segment of the common bile-duct (ampulla) is accompanied by far more disturbance than a multitude of calculi scattered through the intrahepatic ducts.

It was mentioned (p. 61) that small bilirubin-calcium concretions not infrequently play the part of foreign bodies in the gall-bladder and establish a cholelithiasis. This matter has been carefully studied by W. Hunter, who points out that the excretion of irritant products through the bile exerts an irritant action on the intrahepatic bile-passages. Thus an infection of the bile-duct system will induce viscosity of the bile and lead to a precipitation of the bile-pigment and the lime of the bile in the form of an insoluble bilirubin-calcium compound: small concretions, often casts of minute bile-ducts, are carried by the bile into the gall-bladder and act as nuclei of larger stones. In this way gall-stones may be formed independent altogether of infection through the common duct. This is Dr. W. Hunter's explanation of the mode of origin of gall-stones in old people that have never caused any symptoms.

REFERENCES.

- Beer, E.**, "Intrahepatische Cholelithiasis."—*Langenb. Arch.*, 1904, Bd. 74, p. 115.
- Courvoisier.**—*Beiträge zu Path. u. Chirurg. d. Gallenwege*, Leipsic, 1890.
- Eve, F.**, "The Symptoms and Surgical Treatment of Gall-stones."—*Clinical Journal*, 1906, xxviii, p. 39.
- Fenger, C.**, "Stones in the Common Duct and their Surgical Treatment, with Remarks on the Ball-valve Action of Floating Choledochous Stones."—*American Journal of the Medical Sciences*, 1896, cxi, p. 124.
- Galliard.**—*La Presse Médicale*, 1895.
- Freeland, J.**, "Rupture of the Hepatic Duct."—*Lancet*, 1882, i, p. 731.
- Hawkes, F.**, "A Case of Intra-hepatic Calculi; Removal; Drainage."—*Med. and Surg. Reports of the Presbyterian Hospital, City of New York*, 1906, vii, p. 230; and *Annals of Surgery*, 1908, xlvii, p. 809.
- Hunter, W.**, "On Cholelithiasis."—*Brit. Med. Journ.*, 1897, ii, p. 1235.
- Murchison, C.**—*Diseases of the Liver*, 1868, p. 335.
- Rogers, L.**, "Biliary Abscesses of the Liver: with Operation."—*Brit. Med. Journ.*, 1903, ii, p. 706.
- Yachell, H. R., and Stevens, W. Mitchell**, "A Case of Intra-hepatic Calculi."—*Brit. Med. Journ.*, 1906, i, p. 434.

CHAPTER VIII

INTESTINAL OBSTRUCTION FROM GALL-STONES (GALL-STONE ILEUS)

SURGEONS agree that gall-stones which find their way into the intestine through the common bile-duct are voided with the fæces, and without difficulty. There is no definite evidence forthcoming in regard to the limit of size which prevents a gall-stone passing through the duodenal orifice of the common bile-duct. The largest calculus I have removed from the supraduodenal portion of the common duct was equal to a pigeon's egg, but I have found persistent jaundice of eighteen months' standing due to a gall-stone not larger than a cherry-stone, and of the same shape, impacted in the ampulla. The specimen represented in Fig. 32 is instructive in this respect. It is a fair assumption that a gall-stone the size of a cherry-stone represents the maximum dimensions of a stone capable of being extruded through the ampulla. In this connection it must not be forgotten that some of the large openings in the duodenum supposed to be normal ostia are choledochoduodenal fistulæ (see p. 94).

Gall-stones large enough to block the small intestine find their way into the intestines through openings formed by ulceration in the wall of the gall-bladder and the wall of the duodenum, which is adherent to it, in consequence of inflammation. The mode by which the adventitious opening arises was discussed in Chap. VI.

No positive statement is possible regarding the



FIG. 35.—A gall-stone which blocked the ileum six inches from the ileo-cæcal valve in a woman aged seventy-nine years. Cœliotomy was performed, and the stone was manipulated through the ileo-cæcal opening into the cæcum.

size of a gall-stone necessary to block the small intestine, for the lumen of the intestine varies in diameter in different persons. Moreover, the lumen of the small intestine narrows from the duodenum to its termination at the ileo-cæcal valve; hence a stone which would be impacted in the terminal segment of the ileum would traverse the jejunum without much difficulty. For example, the calculus represented in Fig. 35 I found firmly impacted in

the ileum six inches from the ileo-cæcal valve in a woman aged seventy-nine years. With care I succeeded in overcoming the muscular spasm and gently pushed the stone along the ileum and through the ileo-cæcal aperture. The patient recovered from the operation (median cœliotomy) and voided the gall-stone four days later; its transverse diameter is 2·5 cm. Many museums contain far larger examples which, after giving rise to symptoms of acute intestinal obstruction, have been safely voided at the anus. It is probable that a gall-stone 2 cm. in diameter would traverse the ileum with difficulty; in fatal cases the calculi have in nearly all instances had a greater diameter than 2·5 cm. High in the jejunum gall-stones measuring 3 cm. to 5 cm. have been found in fatal cases. In rare instances a small gall-stone has been found in the intestine above a stricture due to a band or to cancer.

When the perforation takes place into the colon the gall-stone passes through the large bowel without difficulty, although cases have been recorded in which exceptionally large calculi have obstructed the descending colon and sigmoid flexure.

A large gall-stone extruded into the colon may traverse the large bowel without much disturbance, but may be arrested at the anus, where its exit may require assistance. The large gall-stone represented in Fig. 19 would cause trouble even in the colon, to say nothing of its passage through the anus.

A case of fatal obturation of the large bowel by a gall-stone has been described by Maynard Smith. The patient was a man aged fifty-six years. A gall-stone the size of a hen's egg had set up ulceration

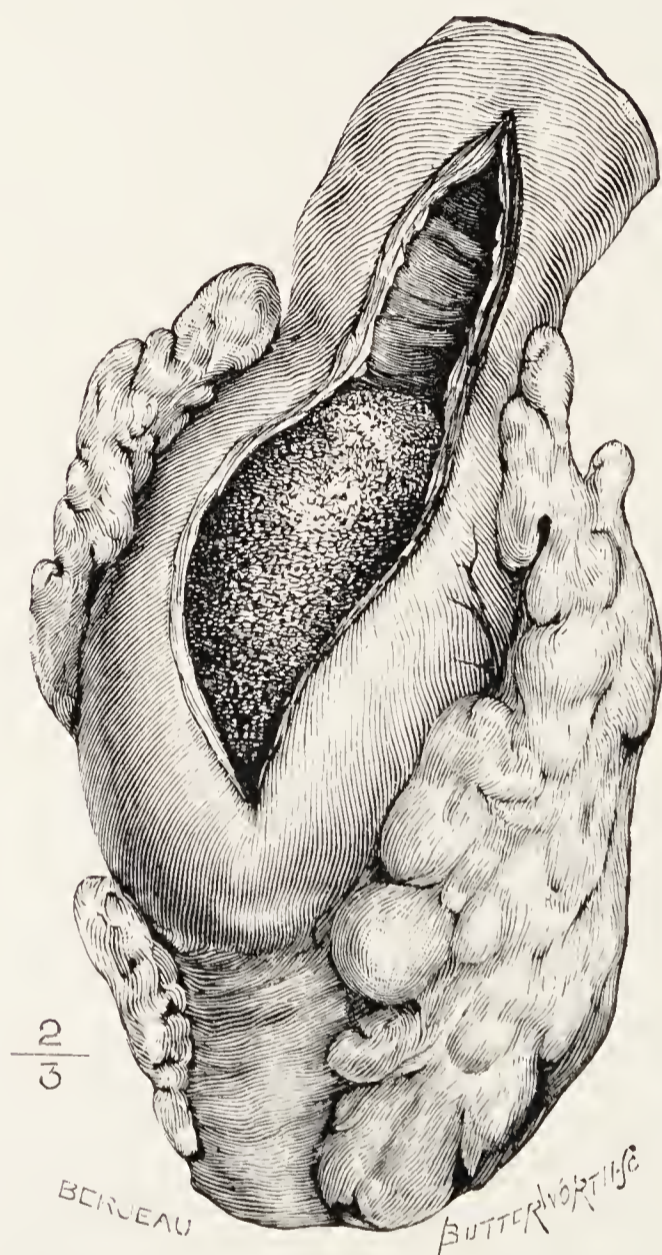


FIG. 36.—A portion of the sigmoid flexure with a large gall-stone impacted in it (Maynard Smith).

in the gall-bladder, and led to a fistula in the transverse colon. The stone passed through this opening and became impacted in the sigmoid flexure at the brim of the pelvis. An operation had been performed and the stone remained undetected until the *post-mortem* examination. The gall-bladder, the segment

of tranverse colon with the fistula in its wall, and a portion of the sigmoid flexure (Fig. 36), with the gall-stone impacted in it, are preserved in the museum of St. Mary's Hospital, London.

The time which a large gall-stone requires to find its way from the duodenum to the ileo-cæcal valve is an undetermined question. We know that foreign bodies when swallowed may traverse the gastro-intestinal tract very quickly. For example, a girl aged eight years swallowed a mother-of-pearl button 1 in. in diameter. Sixteen hours later she was skiagraphed, and this button had escaped through the pylorus, and could be seen in the situation of the ileo-cæcal valve. Three days later it occupied the same position. On the fifth day it was expelled through the anus.

A woman, aged forty-six years, was admitted to the Middlesex Hospital in 1856 with signs of acute intestinal obstruction. She died two days after admission, and at the *post-mortem* examination a gall-stone was found completely blocking the ileum (Fig. 37). The gall-stone was "perfectly cylindrical," and measured nearly 4 in. in circumference and in diameter $1\frac{1}{4}$ in.: the dilated and distended intestine above the obstruction contained "ten small, angular, biliary calculi about half the size of hazel-nuts."

The gall-bladder, the adjacent part of the liver, with the pyloric section of the stomach and duodenum, are represented in Fig. 38. The gall-bladder with

its thickened walls is intimately united with the duodenum at the junction of the first and second portion, and at this part its cavity communicates directly with the lumen of the duodenum, and this opening indicates the path followed by the calculi, the largest of which obstructed the ileum. The case

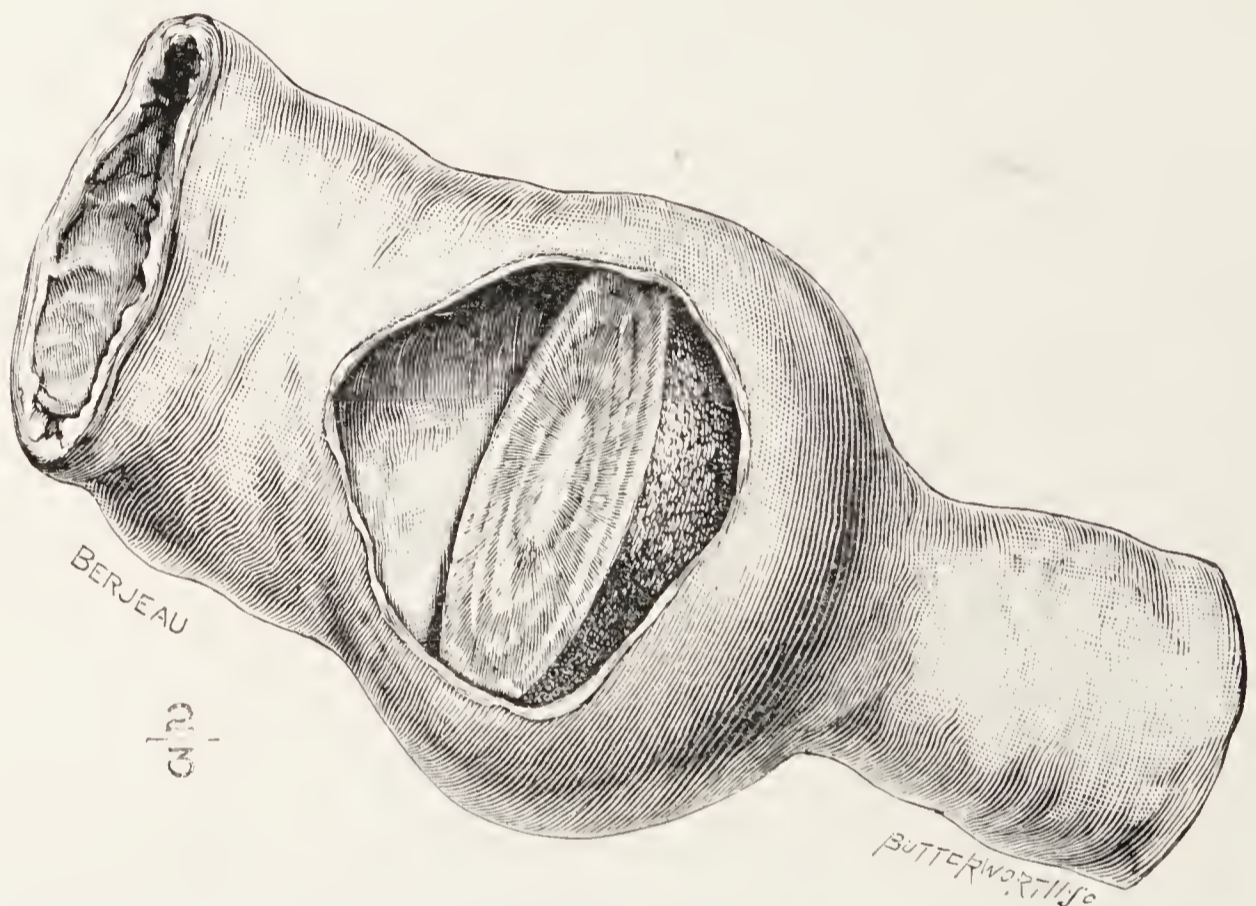


FIG. 37.—Obturation of the ileum by a gall-stone (Museum of the Middlesex Hospital).

was described in 1857 by Van der Byl. The parts have been preserved fifty years in spirits of wine, but on careful examination of the ducts I think the cystic duct is obliterated as a result of chronic calculous cholangitis, which explains also the thickened condition of the gall-bladder and the common duct. No very careful attempts have been made to determine which is the usual spot in the

duodenum for gall-stones to perforate it, but judging from two other examples upon which I have had to operate for a cholecysto-duodenal fistula, it seems to

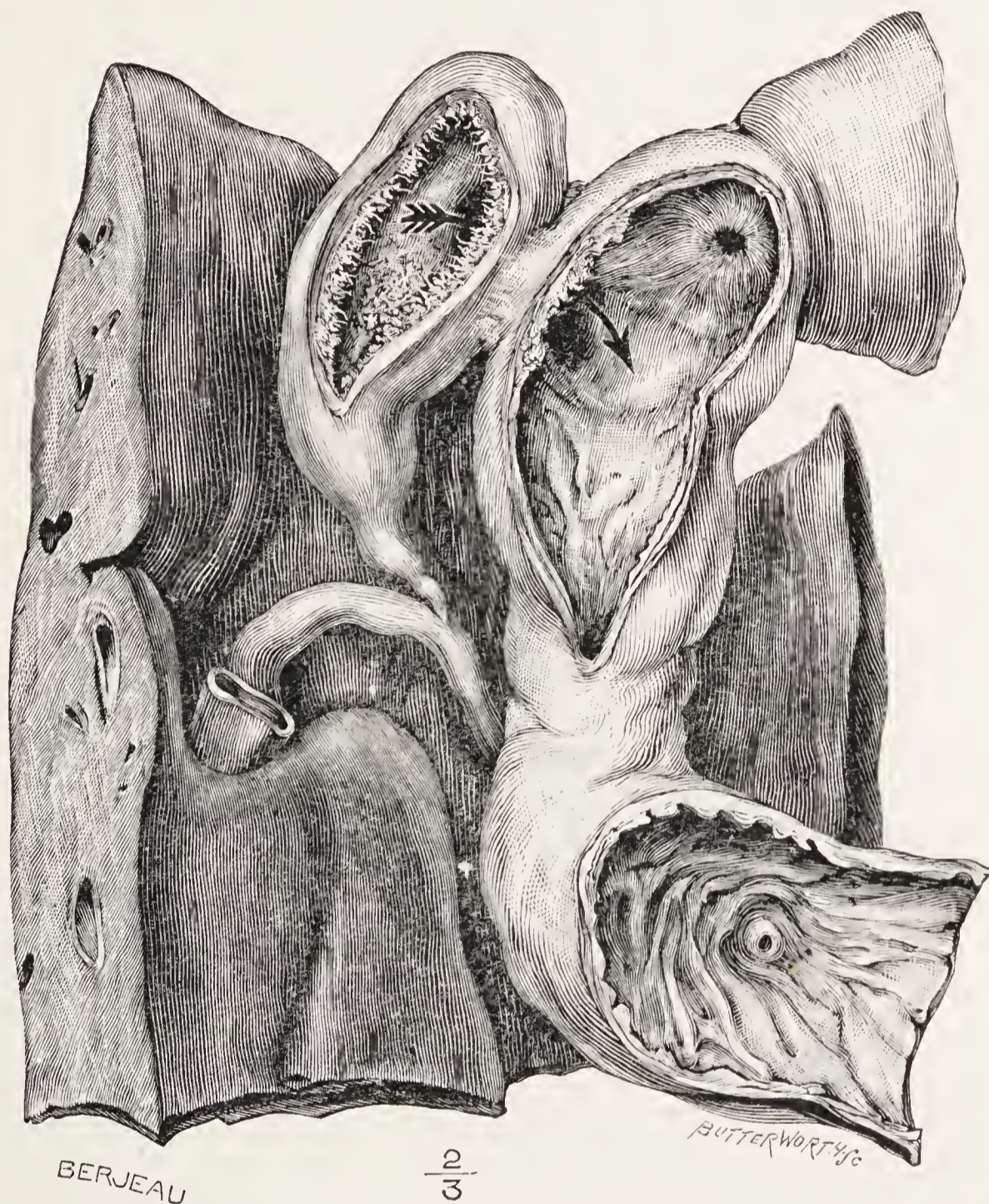

FIG. 38.—Portion of the liver, with the gall-bladder, pyloric section of the stomach, and duodenum. The gall-bladder communicates with the duodenum by an opening which allowed the gall-stone in the preceding figure to enter the duodenum.

me very probable that this is a common situation. In order to show the intimate relation of the gall-bladder to the first segment of the duodenum I have

introduced Symington's excellent drawing (Fig. 39), which demonstrates the relationship in an accurate and artistic manner. This drawing also shows the propinquity of pylorus and gall-bladder, and helps to explain, not only the frequent occurrence of vomit-

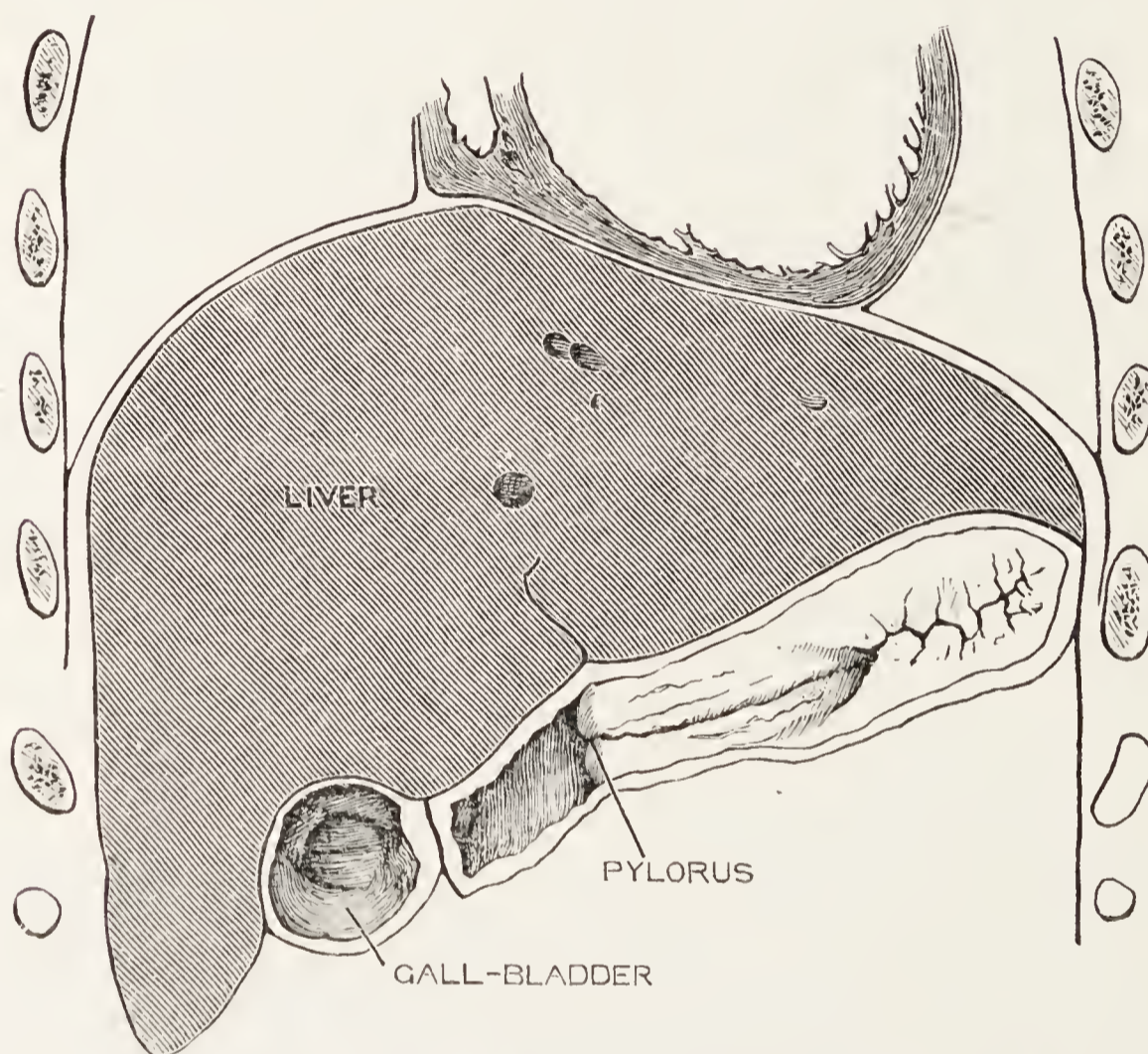


FIG. 39.—Coronal section of a part of the thorax and abdomen of a female infant (aged twenty-two months), showing the relation of liver, gall-bladder, duodenum, and stomach (after Symington).

ing when the gall-bladder is distended as a sequence of calculi in its cystic duct, but also those rare cases in which the pylorus is obstructed by the presence of gall-stones in the gall-bladder. In the remarkable case recorded by Naunyn, in which a gall-stone as large as a goose's egg occupied the gall-

bladder, an ulcerated opening was found in the duodenum just below the pylorus, communicating with the gall-stone. During life the stomach was so distended that it reached to the symphysis pubis. Cases of pyloric stenosis due to gall-stones have been reported by several observers, and in nearly all of them the trouble was supposed, during life, to depend on cancer of the pylorus.

The causes of death in intestinal obstruction from gall-stones is exhaustion from the incessant vomiting and peritonitis. The infection of the peritoneum may be due to leakage at the edges of the fistula between gall-bladder and gut, or more commonly perforation and gangrene of the intestine at the seat of impaction.

In some cases the patients have died after the calculus has been voided in consequence of peritonitis following injury to the terminal section of the ileum, or the parts in the immediate vicinity of the ileo-cæcal valve.

Clinical characters.—Although gall-stones find their way into the intestinal canal very frequently, either through the natural opening in the duodenum or by perforation through the walls of the gall-bladder and adjacent bowel, obstruction from this cause is not common. The patients are advanced in years, usually over fifty, but the condition has been observed in a woman aged thirty-seven years; many are well advanced in years, often seventy

and upwards, and the majority of the patients are women.

The clinical signs are those indicating acute obstruction of the small intestine, and the higher the calculus is lodged the more acute the symptoms will be. The patient complains of a sudden acute pain in the belly, followed by vomiting; at first green bile mixed with mucus is ejected; then the character of the vomited fluid becomes turbid, and in the course of twenty-five hours it assumes the feculent, offensive odour characteristic of vomited fluid coming from the small intestine. The signs are practically those commonly exhibited by acute strangulation of the small intestine, but in some instances the obturation allows the passage of flatus but is complete for fæces. In a few cases when there is a clear history of cholelithiasis the presence of a gall-stone has been suspected; but in the majority of instances an accurate diagnosis is not made until the symptoms gradually abate, and later a large gall-stone is passed with the fæces; or the symptoms continue and become more urgent, an operation is performed, and the gall-stone is found by accident impacted in the small intestine. Intestinal obstruction may be due to a gall-stone and an operation be carried out and the obstructing body missed, for during the negotiations for the operation the gall-stone passes through the ileo-cæcal valve and is voided a few days after the operation.

On one occasion I removed a large faceted gall-stone in size and shape like a Spanish chestnut from a gall-bladder which had suppurated and burst into the peritoneal cavity, but the abscess was enclosed by adhesions. The facets made me carefully search for another calculus, but unsuccessfully. Two or three days later a large faceted calculus was voided with the fæces.

Maclagan has recorded a case in which a woman voided by the anus a gall-stone nearly an inch in diameter; on the following morning she passed a second, an inch in diameter. The next day she passed a third, and two days later a fourth of about the same size. She died about a month later, and a fistula was found between the duodenum and gall-bladder. A stone was found in the gall-bladder similar to the four passed during life.

In some described cases the signs were such that an accurate forecast of the nature of the obstruction could be made. In the most typical examples the signs are: an obvious swelling in the region of the gall-bladder, which suddenly diminishes; the onset of severe pain in the abdomen, which is quickly followed by the signs and symptoms of acute intestinal obstruction.

In rare instances the stone may be felt in its course from the ileum into the colon (Maclagan), and in some cases of acute intestinal obstruction a gall-stone has been felt in the right iliac fossa and

a presumptive diagnosis of gall-stone impacted in the ileum made before operation (Eve, Barnard).

Treatment.—A survey of the reports which are available concerning intestinal obstruction from gall-stones shows that in the cases where the patients have recovered by natural means the calculus has rarely been voided before the fourth day, and a critical examination of reports of cases which have been submitted to operation proves that the very high mortality which attends it may be attributed to two causes—(a) the usually advanced age of the patients, and (b) the operation is postponed till after the trial of medical means, which are usually carried on too perseveringly and too long. A careful perusal of many records indicates that when a gall-stone is impacted in the intestine about two thirds of the patients die.

With operation the mortality is about 50 per cent., but it must be pointed out that even when a stone is safely voided at the anus the patient sometimes dies from exhaustion induced by excessive vomiting, but more frequently from septic peritonitis, due to ulceration and perforation of the intestine usually in the neighbourhood of the ileo-cæcal junction, and not infrequently from leakage near the primary perforation between gall-bladder and intestine.

It is also necessary to remember that cœliotomy may even be a failure, for the surgeon may miss the calculus in the gut.

It is fair to state that the excessive mortality of operations for the relief of gall-stone ileus is, in the main, attributable to undue delay in affording surgical relief. *On the whole it is wise to operate as soon as the diagnosis of intestinal obstruction is made.*

The injury a gall-stone causes to the gut at the seat of impaction is often inimical to successful operation: it is therefore wise to gently move the stone to another part of the intestine and make the incision for its extraction through healthy tissue.

The danger to life from obstruction of the small intestine by a gall-stone and the relative frequency of the accident may be judged from the following facts obtained from several large general hospitals:

MIDDLESEX HOSPITAL.—In ten years (1897–1906) there were three examples; of these two patients died.

LONDON HOSPITAL.—In ten years there were eight cases. One died without operation; seven were submitted to operation and four of the patients died (Barnard).

LEEDS INFIRMARY.—In ten years there was one case (Moynihan).

MANCHESTER ROYAL INFIRMARY (1883–1896).—One case (Brockbank).

ROYAL SOUTHERN HOSPITAL, LIVERPOOL.—Two cases occurred there under the care of G. P. Newbolt: one in 1902 and the other in 1907. The gall-stone in each woman was successfully excised from the ileum.

ST. GEORGE'S HOSPITAL.—In fifteen years one case (Rolleston).

ST. BARTHOLOMEW'S HOSPITAL.—In ten years one case, which was operated upon and died (Hosp. Reports).

GUY'S HOSPITAL.—During five years (1901–1906) there has been “no case of impaction of a gall-stone in the intestine” (Bell Walker).

I ascertained by means of a circular letter that in 1905 two cases of intestinal obstruction from gall-stones occurred in the general hospitals of London; both examples were in the Westminster Hospital (one patient died). In the same year a case occurred in the General Infirmary, Leeds, and was fatal.

REFERENCES.

- Barnard, H. L.**, “Intestinal Obstruction due to Gall-stones.”—*Annals of Surgery*, 1902, xxxvi, p. 161.
- Bland-Sutton, J.**, “On some Cases of Gall-stones.”—*Clinical Journal*, 1906, xxix, p. 17.
- Smith, S. Maynard**, “A Case of Impaction of a Gall-stone in the Large Intestine.”—*Lancet*, 1905, ii, p. 1174.
- Van der Byl**, “Calculus from the Gall-bladder obstructing the Intestine, etc.”—*Path. Soc. Trans.*, 1856–1857, viii, p. 231.
- Moynihan, B. G. A.**, “Intestinal Obstruction due to Gall-stones.”—*Medical Chronicle*, 1903, xxxviii, p. 277.
- Newbolt, G. P.**, “Two Cases of Gall-stone Ileus; Operation; Recovery.”—*Lancet*, 1908, ii, p. 797.

CHAPTER IX

CYSTS ARISING FROM THE INTRAHEPATIC BILE-DUCTS

Two varieties of cysts are found in the liver arising from the bile-canals and ducts independent of any obvious impediment to the flow of bile—namely multiple cysts and solitary cysts.

(1) **Multiple cysts of the liver.**—This variety has long been recognised by pathologists under the term “general cystic disease of the liver.” In typical examples the liver is converted into a huge honey-comb-like mass (Fig. 40). The cavities vary greatly in size; some are as small as grape-seed, others may exceed the dimensions of a ripe cherry. The cysts may project on the surface of the liver, but though this organ may be enormously enlarged, and weigh 35 lb., yet its shape is preserved. The smaller cysts are lined with epithelium. This is best seen in specimens with the cystic change in an early stage, when the dilated canals look like sharp definite punctures in the liver-substance. As the cysts increase in size and number the hepatic tissue is encroached upon, and appears as narrow bridges between large tracts

of honeycomb, but by degrees these become broken up by absorption, and then the remnants of the normal hepatic tissue appear as islands on the cut surface of the liver.

The microscopic characters of the cysts when examined in the early stages prove that they arise in the bile-canals, but no investigator has succeeded in ascertaining the cause of this disease or in associating it with obstruction to the escape of bile. The most remarkable circumstance connected with this disease of the liver is its association with general cystic (congenital) disease of the kidneys, a condition due to ectasia of the uriniferous tubules.

The cause of this cystic disease in the liver is as uncertain as that in the kidneys.

This general cystic disease of the liver causes great enlargement of the organ, but is painless, causes no jaundice, presents no diagnostic features, and comes invariably as a *post-mortem* surprise.

This curious disease has attracted the attention of several pathologists, including Virchow, Rokitansky, Bristowe, Still, Shattock, and Rolleston. Blackburn, in a careful and critical paper, has reviewed the various theories relating to this disease and collected the literature.

(2) **Solitary (non-parasitic) cyst of the liver.**—This is a rare condition, and the general character of such a cyst may be inferred from the specimen represented in Fig. 41. In nearly all the recorded cases the cysts

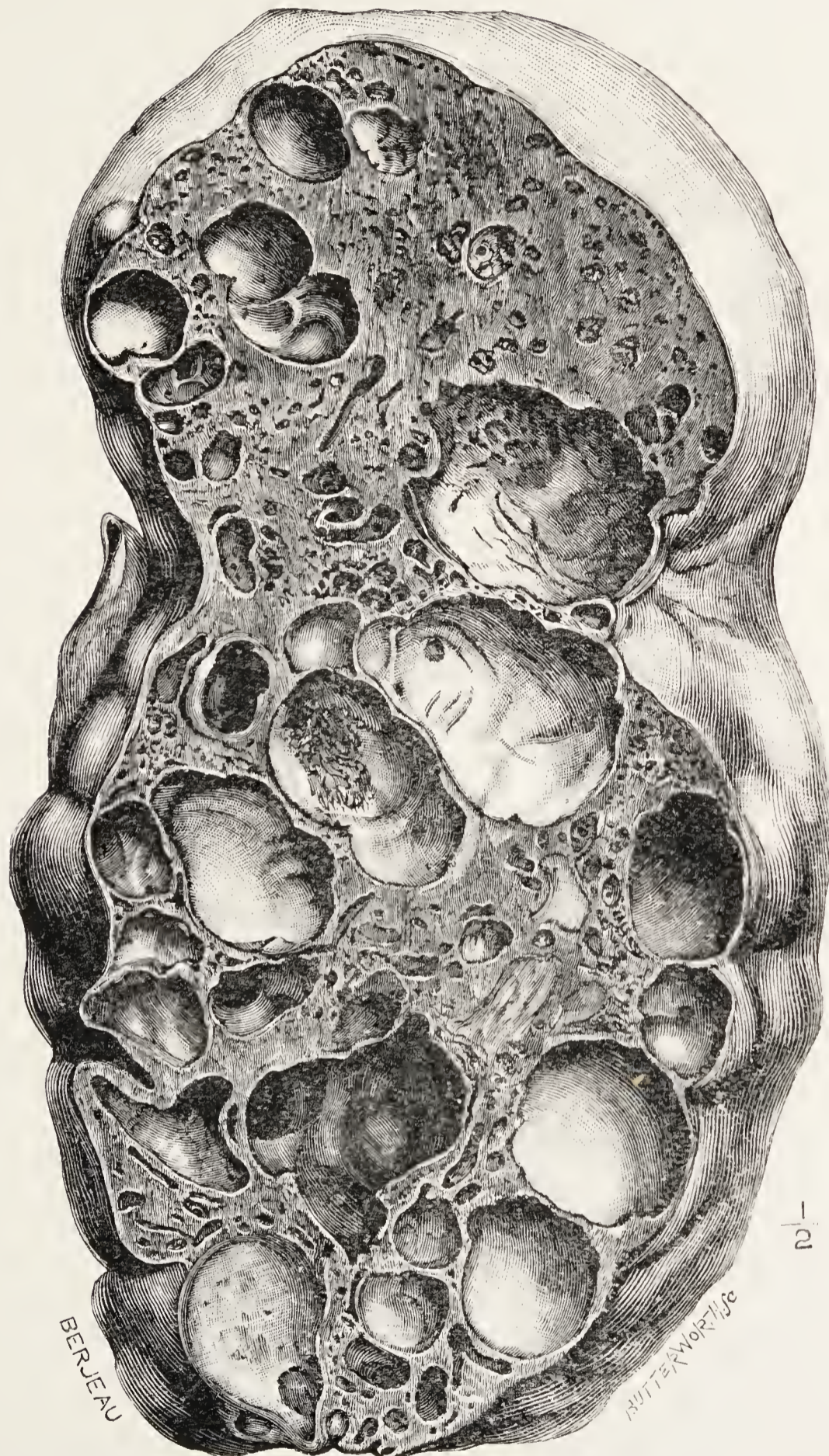

FIG. 40.—A liver in section: the spaces on the cut surface are dilated bile-canals. From a woman aged forty-six years (Museum of the Royal College of Surgeons).

grew from the free margin of the liver, and possessed thin walls which were translucent and had no communication with the gall-bladder. The peritoneal investment and the capsule of the liver were directly continuous with the cyst wall. On microscopic examination of a large solitary cyst, which I enucleated from the liver of a woman, aged seventy-five years, the cyst wall at the point where it joins the liver exhibited small loculi lined with epithelium; ducts could also be detected lined with cubic cells. The cyst wall consisted of fibrous tissue, and its inner surface presented spaces covered with flattened epithelium. In some parts of the cyst wall liver-substance was detected. Such a cyst may be filled with straw-coloured fluid, bile or blood.

The solitary cyst of the liver probably arises from the dilatation and fusion of bile-ducts, and it is difficult to explain its origin. The recorded examples occurred in women. It is noteworthy that the liver of many women presents along its free border a variable strip of thin, atrophied tissue, which appears almost white in contrast with the dark hue of the normal liver. This atrophy of the free border of the liver is attributed, and probably correctly, to the pressure of stays. Whether this be true or not, it was in this pale, thin strip of liver that the solitary non-parasitic cyst arose in my patient, due to the dilatation of the bile-ducts in this tissue; the dilated ducts subsequently fuse to form larger spaces,

much in the same way that cystic spaces arise in a cavernous nævus from the fusion of adjacent blood-vessels composing the primary nævus.

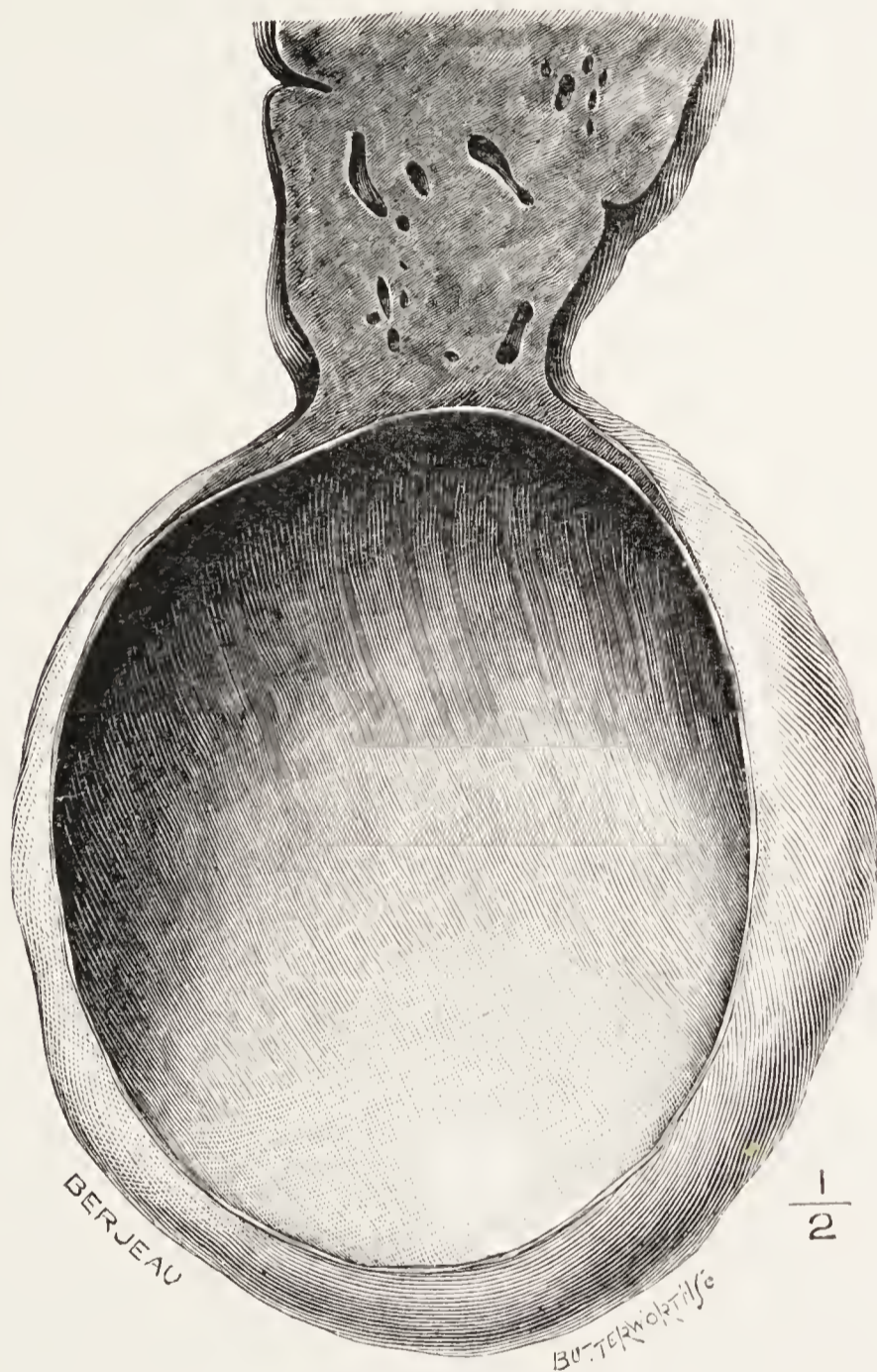


FIG. 41.—A cyst (non-parasitic) growing from the free border of the liver. Obtained *post mortem* from a woman aged thirty-eight years (Museum of the Royal College of Surgeons).

Few special treatises mention the solitary cyst of the liver, but a sufficient number of examples have been recorded to prove that it is a clinical entity and may require surgical treatment. In the patient

under my care the cyst contained two pints of straw-coloured fluid and simulated a mesenteric cyst. One physician who saw the patient regarded the swelling as an ovarian cyst.

In regard to treatment two methods have been adopted. The common plan consists in opening the cyst, evacuating its contents, and then draining it. This is tedious; in my case enucleation of the cyst was followed by the best consequences, although the patient was seventy-five years of age.

It is worth notice that multiple cysts of the liver admit of no treatment, and, as far as I know, do not admit of diagnosis; the solitary (non-parasitic) cyst is a clinical puzzle, but is amenable to surgery.

Rupture of the echinococcus cysts (hydatids) into bile-ducts.—Considering the frequency with which these cysts occur in the liver, it is fair to state that they rarely interfere in any serious way with the bile-ducts, notwithstanding the fact that the large colonies compress and distort the hepatic tissues. The mere pressure of echinococcus cysts on the bile-ducts rarely produces any disastrous consequences. The museum of the Westminster Hospital contains a slice of a liver with great distension of the intra-hepatic bile-ducts which lodge calculi, and the universal dilatation of the ducts and canals in this liver is attributed to an echinococcus cyst the size of an orange which pressed upon and obstructed the hepatic duct.

It was formerly taught that when a cyst of this kind opened into a bile-duct the contamination with bile was fatal to the parasite, but Dévé's observations show that this is not the case, and that scolices will grow in a mixture composed of bile and hydatid fluid in equal parts. It is not uncommon to find bile in suppurating echinococcus cysts of the liver; but it is equally probable, when we consider the frequency with which the larger bile-ducts are infected (septic cholangitis), that when a cyst or colony erodes a *septic* bile-duct, then suppuration of the cyst is an almost certain sequel.

When an echinococcus colony opens into a large bile-duct the hepatic fluid drains away, and the scolices and portions of the mother cyst will traverse the duct and enter the duodenum through the common bile-duct. The passage of vesicles and membrane along the duct produces the paroxysms of pain usually associated with the movements of gall-stones, and the cause of the pain is realised when the evidence of echinococcus disease (scolices and membranes) is found in the fæces.

The reality of this accident is proved by several specimens. For example, the museum of St. Bartholomew's Hospital contains the duodenal termination of the common bile-duct, and a fragment of hydatid membrane projects through the ostium of the bile-papilla.

The museum of the Middlesex Hospital contains a

liver with a large colony which opened into the hepatic duct, and the passage of membrane and vesicles had so dilated the common duct that its terminal orifice would admit a finger.

I took a critical interest in these cases because it is sometimes stated that a frequent route for the discharge of an echinococcus colony in the liver is by communication with the gall-bladder. That a large echinococcus colony does occasionally communicate with the gall-bladder is certain. A man under my care, from whose abdomen I removed many echinococcus colonies, had severe attacks of biliary colic, followed by the passage of vesicles and membrane with the fæces; in order to relieve him I opened and emptied the cyst of membranes and vesicles, found the communication with the gall-bladder, and successfully drained the cavity of the cyst, which was lodged in the omentum. It is also worth remembering that an echinococcus cyst may grow from the under-surface of the liver and be so mobile as to clinically resemble an enlarged gall-bladder, and in at least one instance such a cyst has been removed under the impression it was an echinococcus cyst in the gall-bladder (McGavin). This specimen is preserved in the museum of the Royal College of Surgeons.

The more interesting cases are those in which an echinococcus colony growing in the substance of the liver perforates the gall-bladder and fills its cavity

with fluid and vesicles. J. Hutchinson, jun., has observed an example of this, but it is not a common sequel of echinococcus disease of the liver, and needs to be sharply distinguished from primary echinococcus infection of the gall-bladder.

REFERENCES.

- Blackburn**, "Cystic Disease of the Liver and Kidneys."—*Path Soc. Trans.*, lv, p. 203.
- Bland-Sutton, J.**, "On Solitary (Non-parasitic) Cysts of the Liver."—*Lancet*, 1905, ii, p. 1167.
- Dévé, M. F.**, "De l'Action de la Bile sur les Germes Hydatiques."—*Soc. de Biologie*, 1903, lv, p. 75.
- Doran, A.**, "Large Bile-cyst of the Liver."—*Med.-Chir. Trans.*, 1904, lxxxvii, p. 1.
- Sharkey, S. J.**—"Simple Cyst in Connection with the Liver"
Path. Soc. Trans., 1882, xxxiii, p. 168.

CHAPTER X

EPITHELIAL TUMOURS OF THE GALL-BLADDER AND BILE-DUCTS

THE liver is permeated by minute canals lined with epithelium. These canals are in communication with the duodenum by means of the excretory apparatus of the liver, and the epithelium with which they are lined is continuous with, and was in early embryonic life derived from, the cells lining the intestine. The bile-canals are invisible to the naked eye, but it was shown in the preceding chapter that in certain conditions they are so dilated as to become obvious as cystic spaces and even form large and important cysts.

The forms of epithelial perversion known as adenoma and carcinoma (cancer) arise in any part of the drainage system of the liver, whether internal or external, but cancer is more common in the excretory apparatus than in the intrahepatic system of canals. The common bile-duct and the gall-bladder are also liable to papillomata.

Adenoma and carcinoma arising in the intrahepatic canals imitate their tubular arrangement.

The growths to which the term "adenoma" strictly applies occur as encapsuled tumours in the liver; a single adenoma may be present or many, and they vary in size from a marble to an orange. Some are white, but others are dark green, due to imprisoned bile. On microscopic examination they are seen to be composed of blind ducts, lined with a single layer of columnar epithelium (Fig. 42); these tubules become solid columns of cells towards the periphery of the tumour, and this would lead some observers to regard them as cancerous; as a matter of fact, it is hard to draw a line of demarcation between an adenoma and a cancer, for in all forms of cancer arising in the duct-system of the liver from the beginning of the bile-canals to the ampulla in the duodenum the ground plan underlying their structure is tubular. Rindfleisch, in reference to this kind of cancer, writes: "The peculiar intention which is expressed in the whole foundation advances to a delusive imitation of a tubular gland."

The tubular arrangement may be well seen in some intrahepatic cancers, and especially in metastatic deposits in the lungs.

Although carcinoma may arise in any part of the excretory apparatus of the liver, it is more common in the gall-bladder than in the main ducts; it will be convenient to study its leading features as manifested in this organ.

Cancer of the gall-bladder.—This disease has in

recent years attracted a large amount of attention; this is in a measure due to its intimate association with gall-stones, though this fact has been long recognised.

Cancer may arise in any part of the mucous membrane of the gall-bladder, and, like this disease when it attacks the intestine, may project into the cavity as an exuberant fungating growth, or infiltrate its walls and spread directly into the subjacent

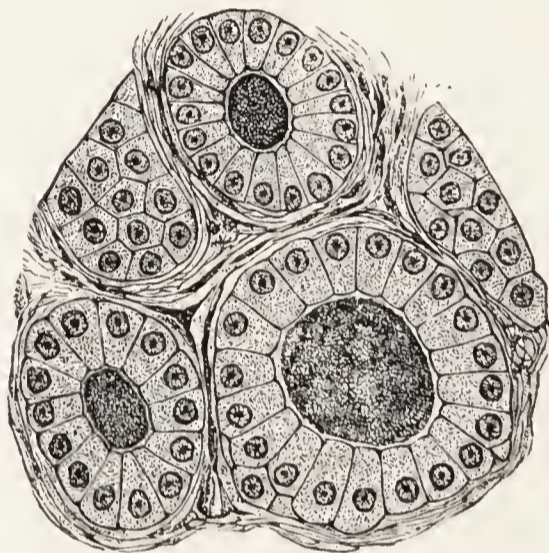


FIG. 42.—Section of an adenoma of the liver showing the tubular structure (after Paul). The cavities were filled with green fluid.

hepatic tissue. Occasionally the disease may be localised to the fundus of the gall-bladder, and bud-like processes of growth will perforate its walls and the cells from the surfaces of these “buds” will give rise to general cancerous infection of the peritoneum.

It is not uncommon for the gall-bladder to be implicated and infected with cancer of the liver, both primary and secondary; it requires some care to discriminate between primary cancer of the gall-

bladder infiltrating the liver and cancer of the liver, implicating the gall-bladder. In some instances the distinction cannot be made. The lymph-glands in the portal fissure are early infected.

The most important feature connected with primary cancer of the gall-bladder is its almost constant association with gall-stones. Careful investigations on this point prove that in at least 95 per cent. of cases gall-stones are present, and this has induced surgeons to regard the presence of biliary concretion in the gall-bladder as a precancerous condition. It is, however, a curious fact, and one worth bearing in mind, that although cancer of the gall-bladder is nearly always complicated with gall-stones, this association is quite exceptional when primary cancer arises in the common bile-duct or the ampulla.

The relations of gall-stones to cancer vary a great deal; in some the walls of the gall-bladder are greatly thickened and the calculi are nested together in the centre of the mass. In other cases, the gall-bladder is filled with a semi-pultaceous mass of soft white growth, and the gall-stones are irregularly distributed through it. In a specimen of this kind I found eighty-six almost pure cholesterin calculi, resembling square lumps of spermaceti. The growth in this instance was so soft that it could be scooped out of the gall-bladder as if it were paste. In other instances the cancerous walls of the gall-bladder are thick and tough and firmly contracted

on a set of gall-stones which completely fill it; yet the organ is free from adhesions and mobile. On the other hand, it may be tightly contracted on a

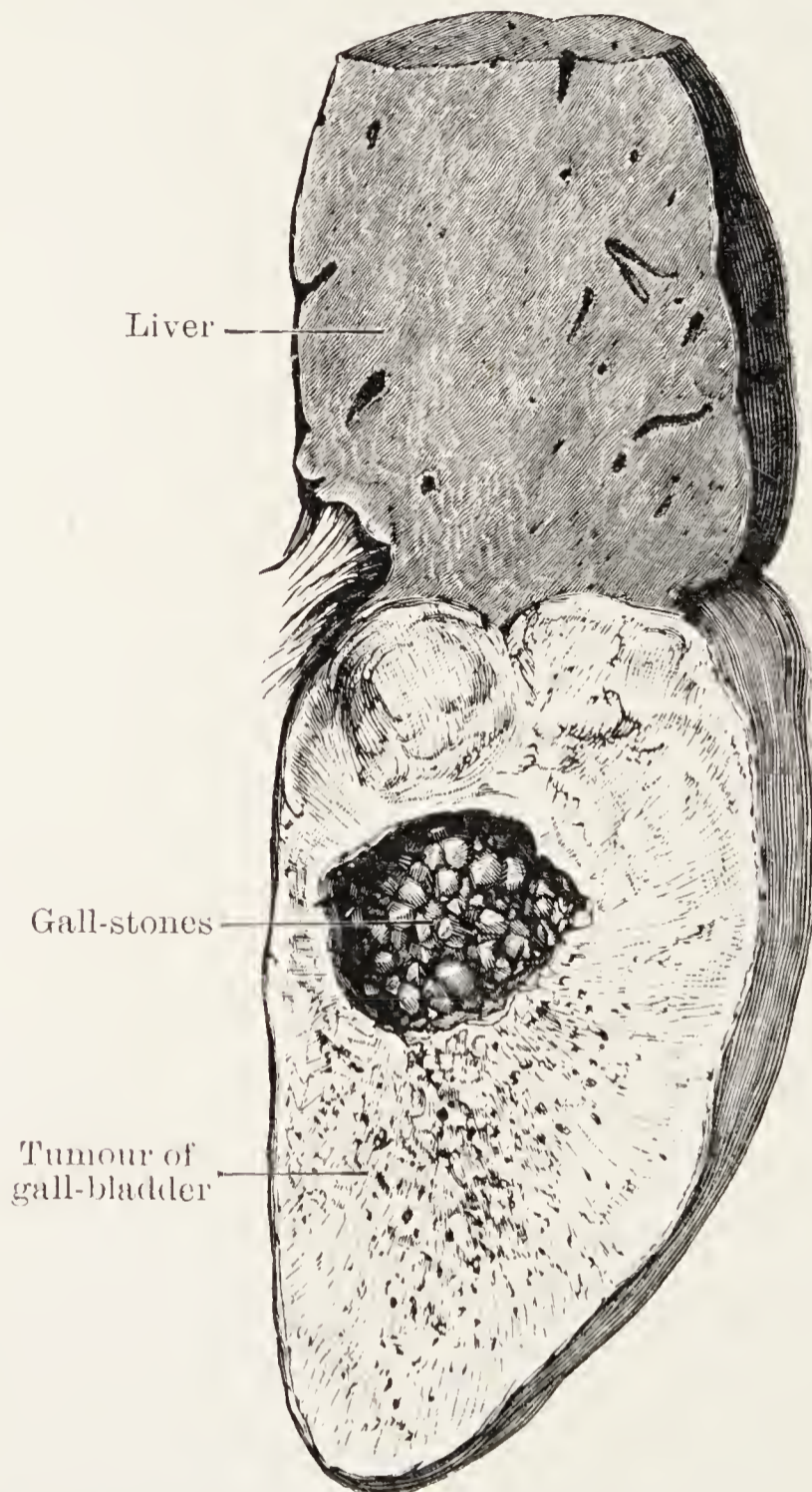


FIG. 43.—A cancerous gall-bladder in section (Museum of the Middlesex Hospital).

solitary gall-stone, and the growth so infiltrate the liver that there is no obvious indication of the limit between the gall-bladder and the hepatic tissue (Fig. 44).

Cancer usually begins, as far as we know, near

the fundus of the gall-bladder, but it may begin in any part of it or the cystic duct. The specimen represented in Fig. 45 is instructive in this respect,

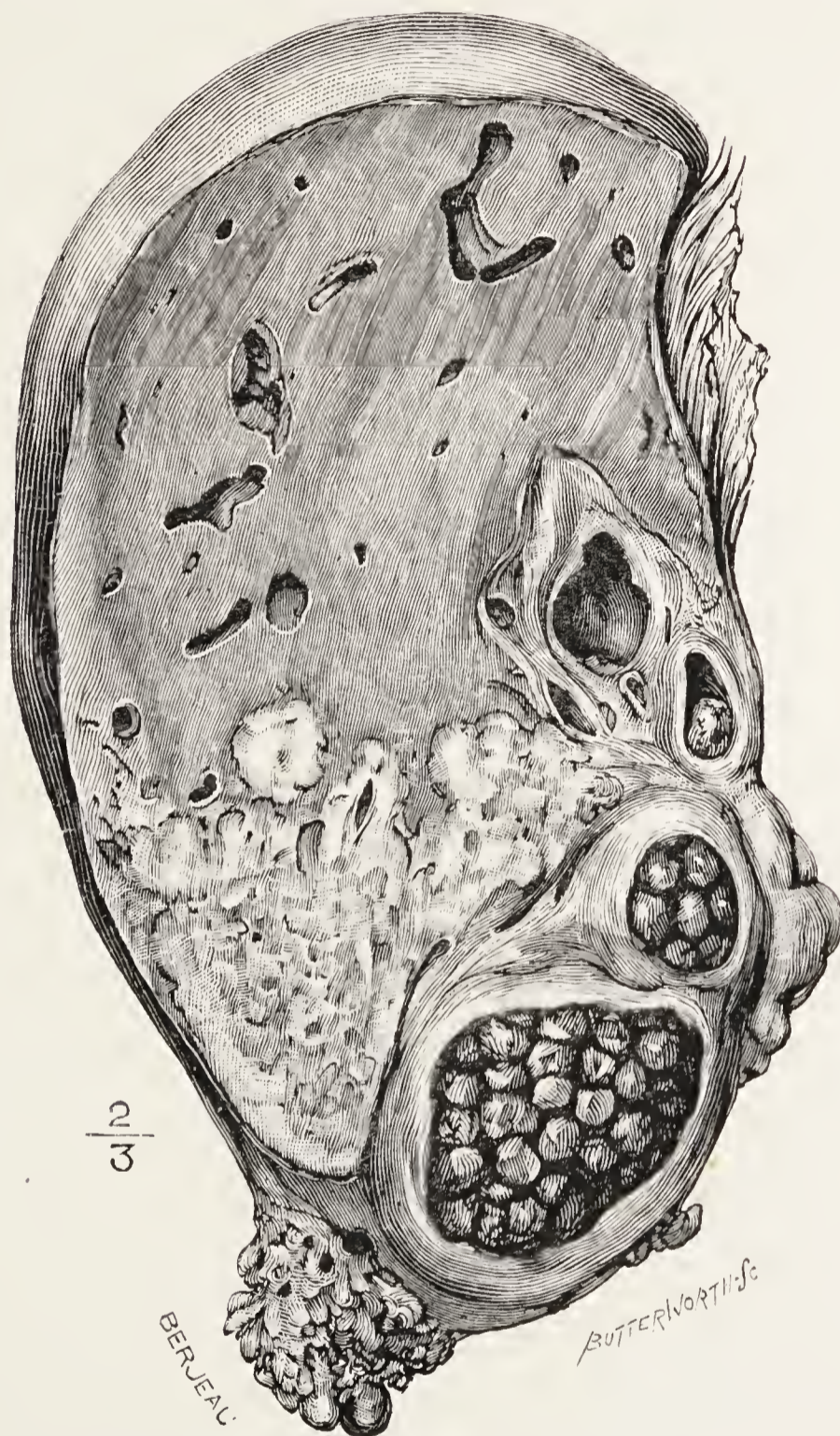

FIG. 44.—A cancerous and calculous gall-bladder in section, showing the manner in which the liver is infiltrated (Museum of St. Bartholomew's Hospital).

for the neck of the gall-bladder and the cystic duct are infiltrated with cancer, which is occupied by a solitary calculus. The new growth forms a ledge

or collar of cancer around it. The gall-bladder was filled with pus. The patient died nine months after the beginning of the symptoms.

The extension of cancer into the cystic duct has a clinical interest, for in a woman, aged sixty-six years, who died under the care of Fürth (see Weber) with deep jaundice and extreme emaciation, the gall-bladder was filled with calculi and surrounded with malignant growth; all the bile-ducts, intra- and extra-hepatic, were so dilated as to resemble the appearance seen in a hydronephrotic kidney.

The type of cells usually found in primary cancer of the gall-bladder is columnar, or subcolumnar. When the walls of a cancerous gall-bladder grip the contained calculi firmly the columnar cells of the mucous membrane flatten and the growth assumes the characters of a squamous-celled cancer, and cell-nests abound.

In one instance of malignant disease of the gall-bladder the tumour proved to be a perithelioma (endothelioma).

Papillomata.—A papillomatous condition of the mucous membrane of the gall-bladder has been observed in association with gall-stones and without them. No special consequences have been connected with the presence of papillomata of this organ.

The most luxuriant growth of papillomata that has been observed in a gall-bladder is figured by Virchow, and its subject was a cow.

Clinical characters.—Primary cancer of the gall-bladder is three times more common in women than in men : the period of greatest liability is between the fiftieth and sixtieth years.

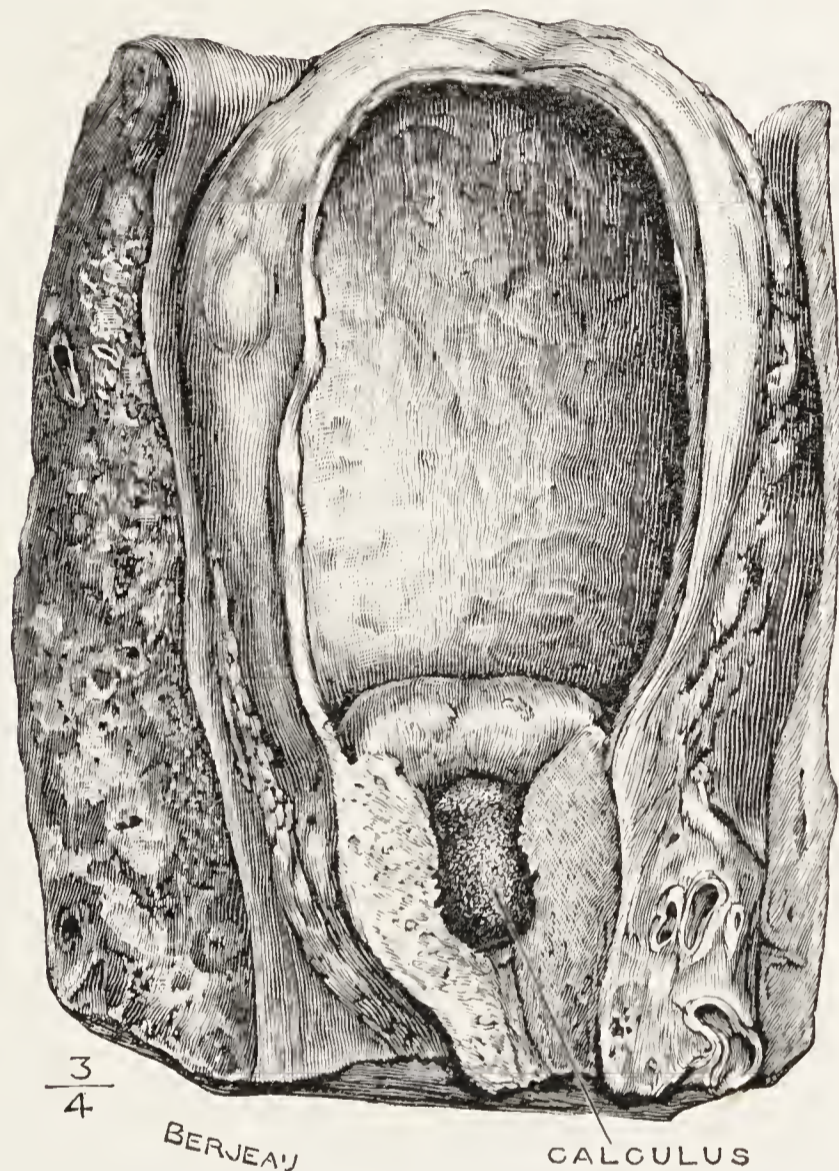


FIG. 45.—A gall-bladder with primary cancer of its neck extending into the cystic duct ; a gall-stone is imbedded in the growth. From a man aged seventy years (Museum, Charing Cross Hospital).

The beginning of the disease is very insidious, and it is remarkable that, notwithstanding the presence of gall-stones, the familiar signs and symptoms of cholelithiasis are usually in abeyance. As a rule, the patients seek advice either on account of a local

lump which they have detected, or for a marked depreciation of their health.

In my experience there are two distinct conditions which present themselves in this disease. In one a more or less movable painful pyriform swelling exists in the right hypochondrium associated with a slight tinge of jaundice; this swelling resembles in all particulars an enlarged gall-bladder, but the local signs are not so acute as in cholecystitis, yet there is usually such an obvious impairment of the general health as to make one suspect the lump to be malignant in nature. In the late stages of the disease ascites is present.

In the other class the patients come under observation with signs indicating serious disease which resemble in part those peculiar to the gall-bladder and those indicating cancer of the liver, and in many instances the signs are such that it is impossible to decide from physical signs which organ is diseased until an exploratory operation is performed. In many instances a gall-bladder full of stones is found (calculous cholecystitis), in others cancer of the gall-bladder; in a few primary cancer of the liver; and occasionally a gall-bladder will be found full of calculi and the liver dotted with nodules of secondary cancer. It is not an uncommon experience to watch a surgeon operate for a suspected calculous cholecystitis to find the disease to be cancer of the pylorus, or of the hepatic flexure of the colon. On the other

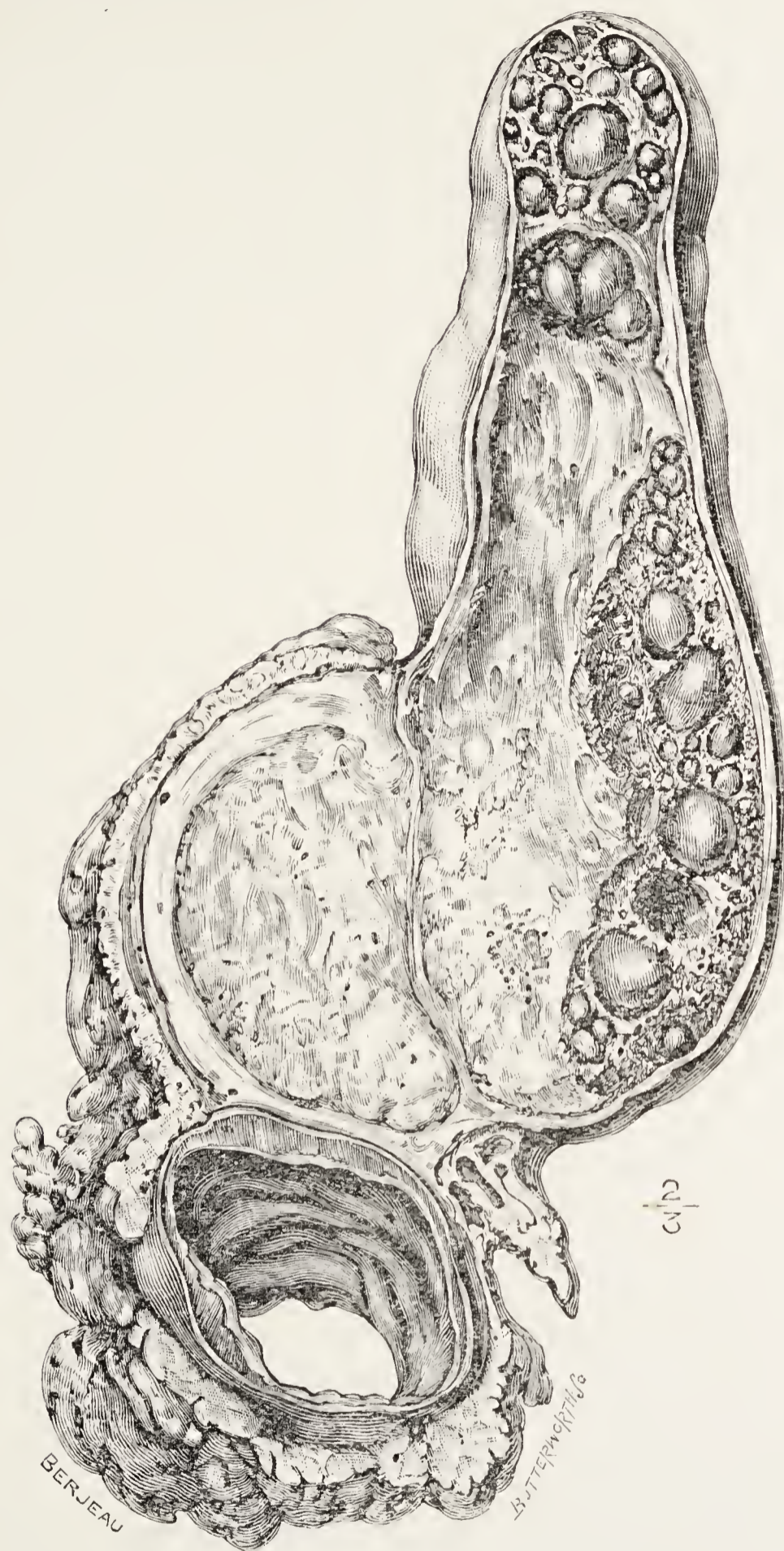

FIG. 46.—An enlarged (cancerous) gall-bladder removed from a woman, aged forty-three years. The cancer had burst through the fundus of the gall-bladder and implicated the transverse colon. Eight inches of the latter were resected. Several hundred calculi, consisting almost entirely of cholesterin, were present.

hand, a timid surgeon, fearing to find cancer of the gall-bladder or the liver, refrains from operating, whereas one of a bolder temperament, unwilling to abandon the patient, explores the gall-bladder, finds a stone in the cystic duct, and reaps a just reward.

Primary cancer of the gall-bladder runs a rapid course, and is usually fatal within six months of the onset of definite symptoms. In its later stages cancer of the gall-bladder infiltrates the adjacent organs, especially the transverse colon and stomach (Fig. 46). Jaundice is present in a third of the cases. The early course of the disease is, like that of cancer attacking internal organs, generally very insidious.

Treatment.—The operative treatment of cancer of the gall-bladder has, in some instances, been carried out with success, but when a large number of hospital cases are analysed the results cannot be considered encouraging. In the year 1905 seventeen cases of primary cancer of the gall-bladder were submitted to operation in the chief general hospitals in London; of these nine patients died (see p. 146).

Unfortunately, by the time a cancerous tumour of the gall-bladder is discovered the time for a successful operation has usually passed.

Now that gall-stones are recognised as a predisposing cause of cancer, it behoves surgeons when removing gall-stones to excise the gall-bladder (cholecystectomy), especially when this organ is thickened and disorganised as the result of chronic

inflammatory (infective) changes. I have long held this opinion, and practised it on many occasions.

Since I have had every gall-bladder which has been removed in my practice examined microscopically, I have been astonished at the frequency with which it is the seat of cancer.

Carcinoma of the common and hepatic ducts.—Primary cancer may arise in any part of the extrahepatic ducts, including the ampulla; although it is a rare disease there are many carefully reported cases and specimens available for reference, and it is possible to furnish an account of its chief clinical and pathological features.

Even excluding cancer arising in the ampulla, the common duct is the one most frequently affected, and in a fair proportion of cases the disease is situated at the junction of the hepatic, cystic, and common duct. The amount of growth is small, but it completely blocks the duct and leads to dilatation of the canals above the obstruction, which become distended with bile, and later in the course of the case this becomes replaced by mucous fluid which may be bile-stained (Fig. 47). In many of the reported cases it is stated that there was evidence of more or less interstitial biliary fibrosis.

Clinical features.—Cancer of the main bile-ducts appears to be most common between the fiftieth and sixtieth years. The symptoms are those commonly seen in primary cancer of the head of the

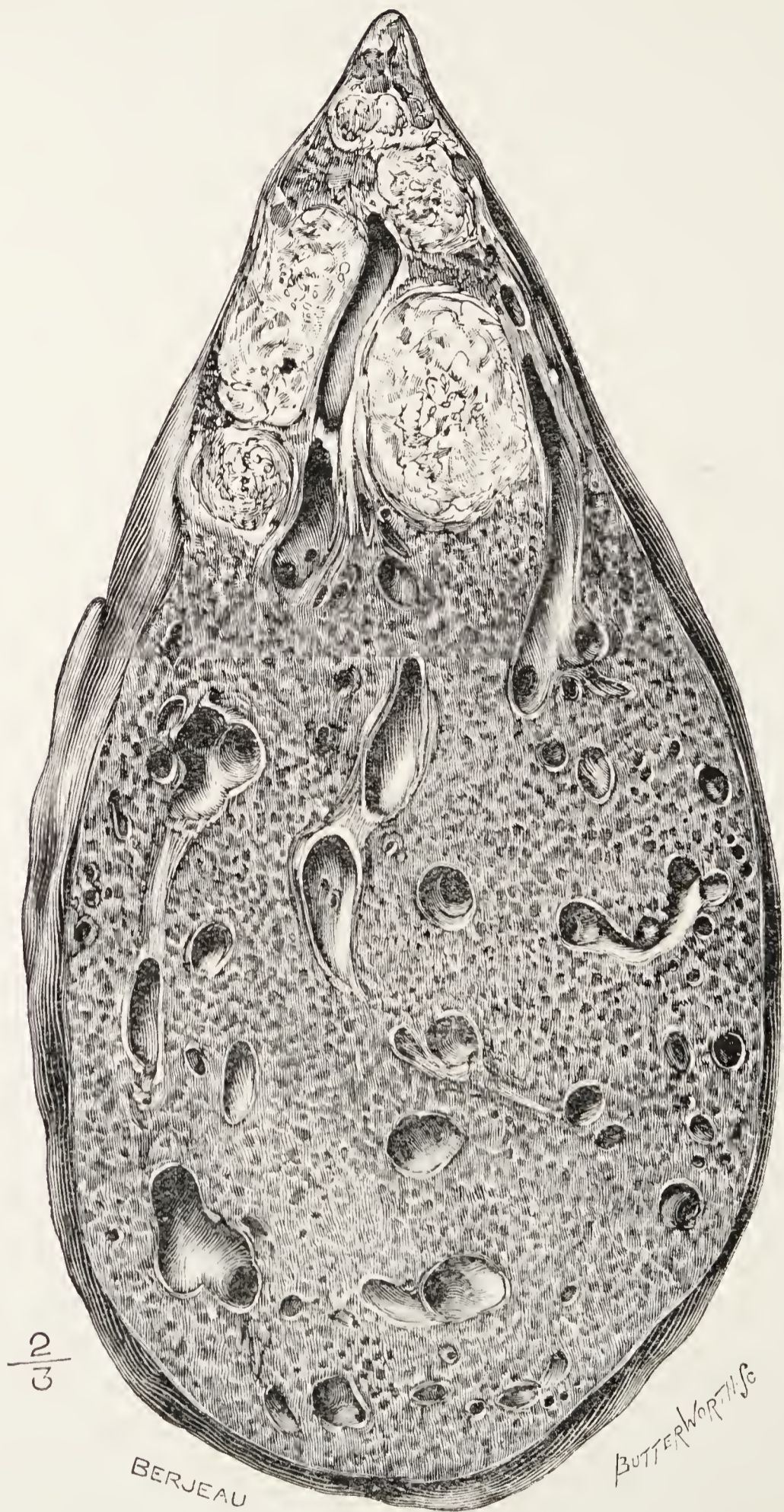

FIG. 47.—Liver in section, showing dilatation of the intrahepatic bile-canals secondary to primary cancer of the common duct.

pancreas implicating the common bile-duct such as jaundice, progressive emaciation, and occasionally enlargement of the gall-bladder. When the ampulla is cancerous the clinical picture would be the same in the two diseases. The distension of the gall-bladder in this disease is of some importance, because cases have been reported in which the patients died from acute peritonitis due to intraperitoneal rupture of the gall-bladder (Cockle, 1883, Coats and Finlayson).

Gall-stones have been found in cancerous bile-ducts but the association is uncommon.

Pain is an uncertain feature; it is well to remember that a gall-stone may painlessly obstruct the common bile-duct, producing profound jaundice; on the other hand, cancer may obstruct the duct and set up attacks of pain resembling biliary colic.

In this condition the patient may suffer greatly from itching of the skin.

To the naked eye cancer of the common bile-duct looks like a knob of tough fibrous tissue, or the ducts appear as if imbedded in this material, but on microscopic examination it is seen to be made up of columnar or spheroidal-celled epithelium, and in some specimens the tubular arrangement is obvious, and it is described as an adeno-carcinoma (Parkes Weber). The lymph-glands in the portal fissure may be enlarged.

Carcinoma of the ampulla.—It is possible to distin-

guish between cancer arising in the common duct near its junction with the ampulla and cancer arising in the epithelium lining the ampulla ; and cancer in either situation needs to be distinguished from this disease arising in the duodenal epithelium around the bile-papilla (circum-ampullary carcinoma).

From a practical point of view the distinction is not important except in the particular that a cancer immediately above the ampulla would block the common bile-duct, but need not block the pancreatic duct, whereas a growth in the ampulla would obstruct the flow of pancreatic secretion as well as bile.

The diagnosis of the condition is beset with great difficulty, as this disease has no specific symptomatology. The symptoms are homologous with those produced by cancer of the head of the pancreas ; primary cancer of the duodenum, involving the bile-papilla ; a malignant tumour of the stomach involving the duct ; and even a gall-stone impacted in the ampulla. It is also impossible to distinguish it from some forms of disease of the liver, such as carcinoma, hypertrophic biliary cirrhosis, or even catarrhal jaundice, and the pressure of an echinococcus cyst or cancerous lymph-glands in the portal fissure.

Treatment.—The diagnosis of this disease is very difficult and occasionally the uncertainty is cleared up by an exploratory operation.

In a case of this kind in a woman aged sixty

years, under Osler's care, Halsted found a carcinoma of the ampulla; he excised the cancer, the bile-papilla and ampulla, and the adjacent section of the common duct; the cut end of the duct he implanted into the duodenum. The woman recovered from the operation, but died several months later from recurrence of the cancer in the head of the duodenum and pancreas (see also Körte).

In cases where an exploratory operation has been performed, and the surgeon finds it impossible or, in consideration of the patient's condition, imprudent to attempt a radical operation, it is sometimes to the patient's interest and comfort to anastomose the gall-bladder with the colon (cholecystenterostomy). This will certainly relieve the irritating minor troubles associated with the jaundice, although it will for a time set up biliary diarrhoea. The great danger of these operations in cholæmic patients is uncontrollable oozing as in leukæmia.

In a few instances where the common and hepatic ducts have been dilated into large sacs behind an inoperable complete obstruction of the common bile-duct an anastomosis between the sac and the duodenum has been successfully effected (cholechohostomy).

In a patient in whom the gall-bladder was too small to permit cholecystenterostomy for the relief of a distressing jaundice Michels performed intra-hepatic cholangiostomy (see p. 230).

With the object of obtaining some idea of the frequency of primary cancer of the gall-bladder I sent a circular letter to the chief metropolitan hospitals (see Chap. XX) for the purpose of obtaining, among other things, information on this matter. In 1905 seventeen patients were submitted to operation for disease of the gall-bladder which proved to be cancer (London Hospital, 7; St. Mary's, 2; St. Thomas's, 1; Westminster, 2; Guy's, 2; University College, 2; Charing Cross, 1). Nine patients died from the operation. In the same year at the General Infirmary, Leeds, there were nine cases of primary cancer of the gall-bladder under observation.

Ten years ago cancer of the gall-bladder was regarded as a novelty. The facts in the preceding paragraph show that it is in no sense uncommon. Since Slade published his important observations on the gall-bladders, removed by the surgeons at the London Hospital, teaching us that cancer of this organ is a common disease, every gall-bladder which I remove is histologically examined; the frequency with which they are found to be cancerous appals me. This is an important matter, and interesting in its bearing on the cause of cancer. The views which have at present prevailed regard the diseases of the bile-ducts and gall-bladder as arising from an ascending infection from the gastrointestinal tract. Observation and experiment teach us that many of the more serious diseases of these

ducts are caused by a primary infection from the blood, either by the general or portal systems (Chap. II). These new views have an important bearing on the origin of cancer of the gall-bladder and the bile-ducts. One of the chief facts urged by those who regard cancer as a micro-parasitic disease, is the frequency with which cancer arises in the gastro-intestinal canal. More than half the total number of cases which attack mankind arise in the alimentary tract. This supports the idea that the hypothetical parasite of cancer is conveyed by uncooked food or water. It is conceivable that cancer of the gall-bladder is caused by some infecting agent obtained from the alimentary canal by the blood and eliminated by the liver and lodged in the gall-bladder, where it stimulates the epithelium to unnatural growth.

Infection of epithelium causes it to multiply: this is exemplified in the gall-bladder. Its mucous membrane under normal conditions contains few glands, but when it is chronically inflamed, mucous glands become abundant and of large size. In cases of fistulæ between gall-bladder and intestine the mucous membrane becomes thick and resembles that of the intestine. These mucous glands are important, for they are the chief sources of the calcium found in mixed biliary concretions. It is undeniable that gall-stones are a common complication of cancer of the gall-bladder, and many writers have maintained

that they are the cause of the cancerous change. I have never accepted this opinion, preferring to believe that the pathological conditions of the epithelium lining the gall-bladder which cause it to produce cholesterin in abundance, increase its vulnerability to the micro-parasite of cancer. For this reason, among others, the surgeon acts in the best interests of his patient when he removes gall-bladders when they are so disordered as to require surgical interference.

REFERENCES.

- Coats, J., and Finlayson, J.,** "Cancer of the Terminal Part of the Common Bile-duct."—*Path. and Clin. Soc. Trans.*, Glasgow, iii, p. 144.
- Cockle,** "Cancer of the Duodenum, Suppuration and Perforation of the Gall-bladder followed by Fatal Peritonitis."—*Medical Times*, 1883, i, p. 435.
- Halsted, W. S.,** "Contributions to the Surgery of the Bile-passages, especially of the Common Bile-duct."—*Johns Hopkins Hospital Bulletin*, Baltimore, 1900, xl, pp. 1-11.
- Korte, Prof. W.**—*Beiträge zur Chirurgie der Gallenwege*, Berlin, 1905, s. 223.
- Paul, F. T.,** "Cases of Adenoma and Primary Carcinoma of the Liver."—*Path. Soc. Trans.*, 1885, xxxvi, p. 238.
- Rolleston, H. D.,** "Primary Carcinoma of the Ampulla of Vater."—*Lancet*, 1901, i, p. 467.
- Slade, G. R.,** "Gall-stones and Cancer."—*Lancet*, 1905, l, p. 1052.
- Virchow, R.**—*Die Krankhaften Geschwulste*, 1863, i, p. 340.
- Weber, F. P., and Michels, E.,** "A Case of Chronic Jaundice and Great Enlargement of the Liver due to Primary Carcinoma of the Extra-hepatic Bile-ducts commencing at the Junction of the Hepatic Ducts."—*Med.-Chir. Trans.*, 1905, lxxxviii, p. 247.

CHAPTER XI

THE EFFECTS OF SOME FORMS OF PANCREATIC DISEASE ON THE EXCRETORY APPARATUS OF THE LIVER

THE pancreas is so intimately associated with the common bile-duct embryologically, anatomically, and pathologically, that it is essential in a work dealing with diseases of the bile-ducts to consider the effects of those forms of pancreatic disease which directly affect, and, indeed, often implicate, the main conduits of the liver, as well as those affections of the common bile-duct which exercise a malign influence over the pancreas.

It is curious that of these two important glands so largely concerned in digestion, one, the liver, should be the largest and most conspicuous organ in any mammal, and the other, the pancreas, may be described as one of the least obtrusive and apparently insignificant organs in the mammalian economy, yet the complete abrogation of its functions is as surely fatal as renal bankruptcy. When the intimate relationship of the terminal segment of the

common bile-duct and of the pancreatic duct are considered—for they both open independently into an ampulla with a diameter of only 4 mm., and their secretions issue into the duodenum through a common orifice less than 2 mm. across—it is sur-

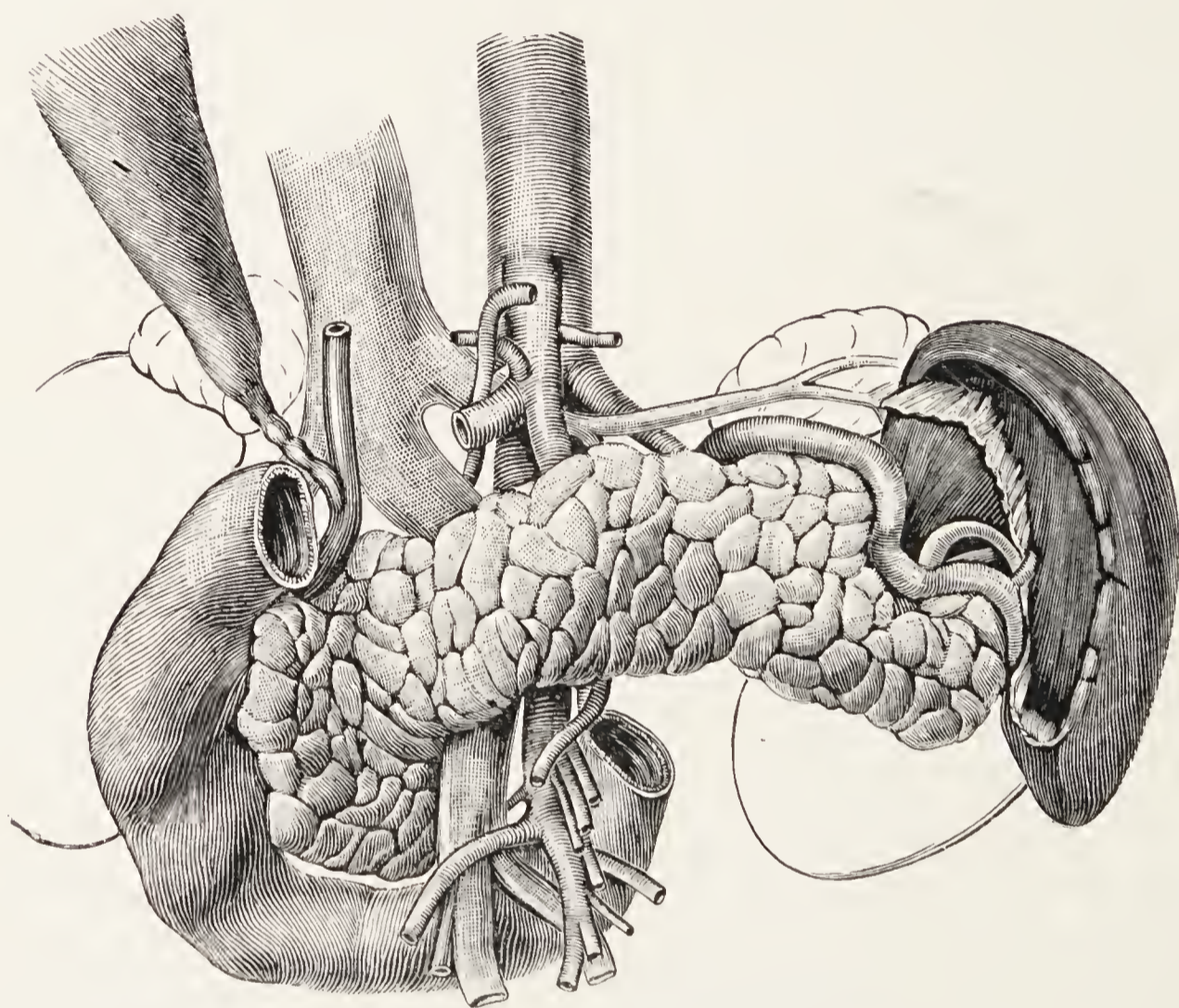


FIG. 48.—A drawing showing the intimate relations of the pancreas, duodenum, and common bile-ducts (Sobotta).

prising that they are not more frequently implicated in a common disorder than is actually the case.

The manner in which disease may attack the terminal segment of the common bile-duct and not implicate the pancreatic duct is illustrated by some specimens of congenital obliteration of the ducts (Chap. IV), in which more than half the common

bile-duct has undergone antenatal obliteration, and persists as a mere thread, but the terminal orifice of the pancreatic duct may be pervious and the papilla and ampulla normal.

The pancreatic duct, in common with the main duct of all compound glands, is liable to be infected with micro-organisms of varying degrees of virulence, and the changes in the glandular tissue of the pancreas in consequence of such infections is known as pancreatitis, with the usual qualifications of acute, subacute, and chronic.

The pathology of pancreatitis is much the same as that of parotitis, but there is this difference: the abdominal position of the pancreas makes acute infection, and especially suppurative inflammation of this gland, a grave menace to life from its liability to set up acute septic peritonitis.

The pancreas differs from the salivary glands, its nearest congeners, in the fact that its secretion is of the highest importance in digestion, especially in relation to fat; and also the peculiar physiologic importance of those parts of it known as the islands of Langerhans, which are believed to stand in close relationship with pancreatic diabetes.

The various degrees of pancreatitis have a symptomatology of their own, and these diseases have recently been studied with much care, since Riedel pointed out their frequent association with cholelithiasis, and the symptoms and signs are such as

permit them to be recognised clinically. The form which concerns us particularly in relation to diseases of the bile-ducts is chronic pancreatitis, for it stands in a triple relationship to cholelithiasis. For example:

(a) Cholangitis and pancreatitis may be the consequences of a common infection.

(b) The pancreatitis may be the sequel of the impaction of a gall-stone in the ampulla.

(c) Chronic induration (sclerosis) of the head of the pancreas, the result of chronic inflammation, may cause stenosis of the common bile-duct.

Some writers also agree with Opie that acute pancreatitis, which is ushered in with sudden epigastric pain and tenderness, and quickly followed by abdominal distension, vomiting, and collapse, may, in some instances, be due to the impaction of a gall-stone in the ampulla. Mayo has recently stated in a review of the fifteen hundred cases of cholelithiasis that eighty-six were complicated with pancreatitis.

Pancreatic lithiasis.—Calculi are sometimes found in the pancreatic duct, and, as a rule, they are multiple. In colour they are opaque white; and in shape round and smooth, or rough and like coral: they consist mainly of calcium carbonate.

Pancreatic calculi are associated with several pathologic conditions of the gland, such as chronic interstitial inflammation, distension of the main duct (pancreatic ranula), acute pancreatitis, abscess of the pancreas, and cancer.

In the pancreas, cancer shows the same partiality so manifest in other organs to attack glands already unhealthy or diseased.

I do not know of any convincing case where a pancreatic calculus has obstructed the common bile-duct or even induced jaundice. On several occasions I have critically considered the symptoms and operated with the expectation of finding a pancreatic calculus in the ampulla, but found a gall-stone; and on two occasions I have operated with the belief that the pancreatic duct was obstructed by a pancreatic calculus, and even with the head of the gland between my finger fancied I could feel a calculus, but on cutting upon it have found the duct obstructed and the supposed calculus to be a cyst.

The balance of evidence goes to show that a gall-stone impacted in the ampulla will lead to chronic inflammatory changes in the pancreas, as well as hinder the flow of pancreatic secretion. The wasting, in consequence, often suggests the existence of malignant disease. It is also somewhat remarkable, considering the firmness with which some of the calculi are impacted, that the obstruction of the pancreatic outflow is not complete. I have given careful attention to this matter when engaged during an operation in removing the calculus from the ampulla through an incision in the duodenum, and I have noticed that the portion of the gall-stone protruding into the duodenum is smooth and rounded like a

pebble in a brook ; and it seems to me that when a gall-stone is lodged in the ampulla the continuous flow of the pancreatic secretion erodes the surface of the stone like water will channel even granite, and thus preserves for itself an outlet into the duodenum.

Another point concerning a gall-stone in the ampulla: it is stated that when the bile is prevented from freely escaping some of it may find its way round the stone and flow into the pancreatic duct. and that this biliary injection of the pancreas may lead to sclerosis of the gland. I have never had an opportunity of studying this condition, and I think it must be rare.

Apart from the deleterious effects which arise from chronic pancreatitis, such as the imperfect digestion of food, especially fat, giving rise to voluminous stools and the passage of free fat with the fæces and the necessary consequences, emaciation and progressive weakness, the local effects are very important, because it is often extremely difficult to decide whether the symptoms of which the patient complains depend on obstruction to the bile-duct from conditions amenable to surgery ; or whether they are due to pressure from tumours or cysts ; or cancer of the head of the pancreas implicating the bile-duct, a condition for which surgery can do nothing.

Cancer of the pancreas.—This is a disease of great

interest because it is in itself very insidious, and rarely becomes clinically recognisable except from what may be called an accident in its environment, namely, the disease is very prone to attack the head of the gland and cause jaundice by obstructing the common bile-duct.

The pancreas is a compound gland, for in addition to its own acini it is occupied by the epithelial bodies known as the islands of Langerhans, which are at present regarded as ductless glands furnishing an internal secretion. The pancreas contains three distinct sets of epithelial structures; these are its own acini, the islands, and its excretory duct, commonly known as the duct of Wirsung. Hillier and Goodall have conducted a valuable investigation concerning the histology and general features of carcinoma of the pancreas, and they have come to the conclusion that primary cancer of this gland may arise in each of the three epithelial structures which it contains. The common type is spheroidal-celled carcinoma with a large amount of fibrous tissue; this probably arises in the acini of the gland and is comparable to spheroidal-celled cancer of the breast. The second variety is columnar-celled and probably arises from the duct; in structure this kind resembles primary cancer of the duodenum.

The third variety is of interest as there is good reason to believe that it arises in Langerhans' islands; "it consist of cells most irregular in size

and shape, but on the whole much larger than in the other varieties of carcinoma, and possessed of nuclei which in some instances are enormous."

In connection with the relation of the islands to carcinoma, it is pointed out that in the ordinary

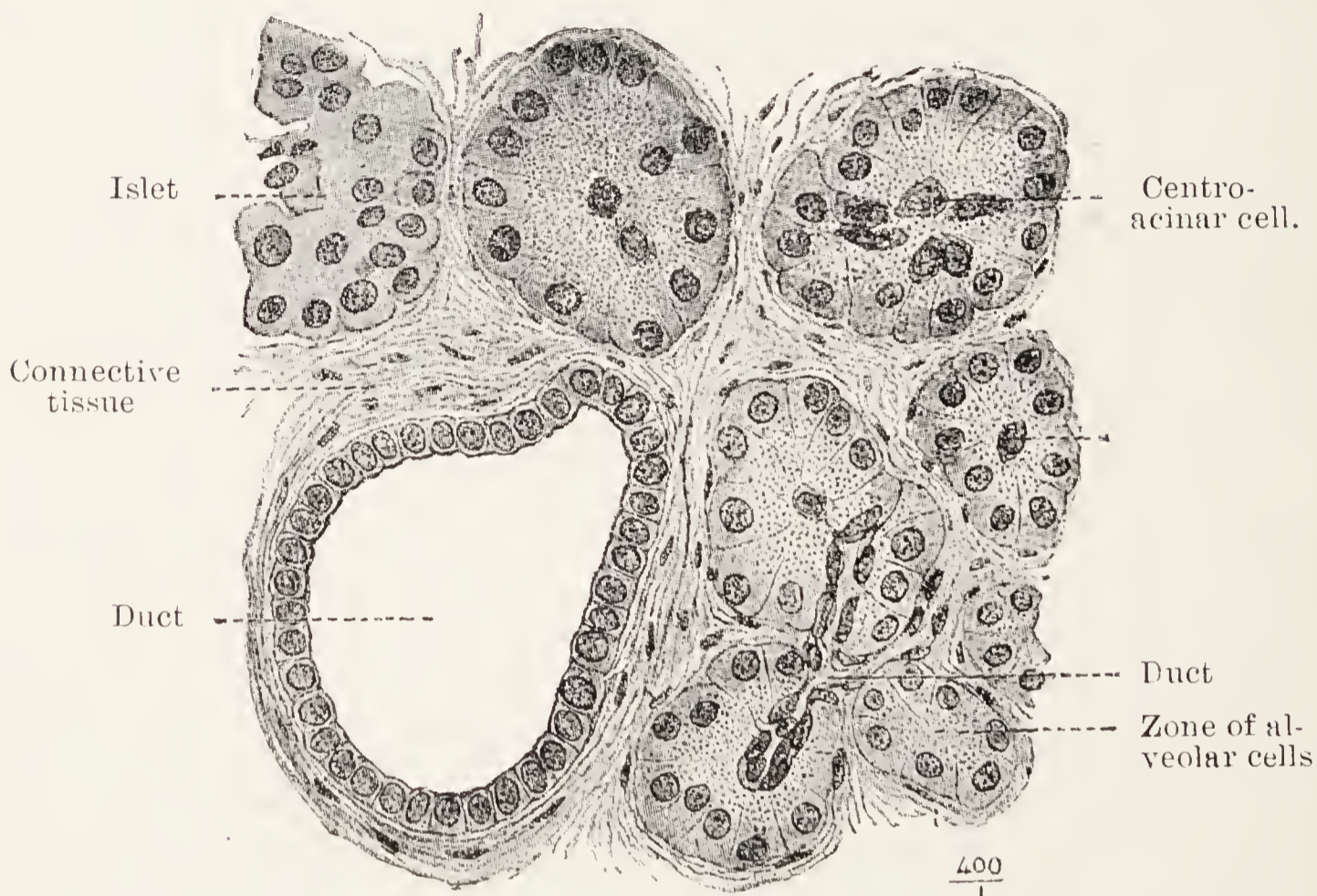

FIG. 49.—A magnified view of a cross-section of the pancreas, showing its various epithelial elements (after Böhn and Davidoff).

varieties of cancer of the pancreas the islands remain unaffected, and may be seen in some instances surrounded by cancerous growth; on the other hand, when the pancreas is the seat of secondary cancer the islands are among the first of the pancreatic structures to disappear.

Cancer of the pancreas attacks the head of the

gland six times more frequently than the tail. In one unusual case a cancerous deposit was found in the head and tail of the same gland (Hale White). Hillier and Goodall observe that the site of origin for the head corresponds closely with the position of the junction of the ducts of Wirsung and Santorini.

Clinical features.—The difficulty of recognising cancer of the pancreas is increased by the fact that the tumour is rarely large enough to be appreciated by manipulation through the abdominal wall. The main clinical features of primary cancer of the head of the pancreas can be accounted for by the position of the growth ; they are—jaundice due to interference with the common bile-duct, bronzing and emaciation from obstruction to the pancreatic duct, pain (cœliac neuralgia) from implication of the cœliac plexus, and septic thrombosis of the large veins in its vicinity. No symptom is constant, and it is uncommon for all to be manifest in one patient.

The disease is rare before middle life, and it attacks both men and women. The chief manifestation is deep jaundice, often unaccompanied by pain. As the disease progresses and the jaundice deepens, an oval tumour is sometimes appreciable in the right lumbar region ; this is the over-distended gall-bladder, and it is painless to touch. In a certain proportion of cases a second swelling can be made out in the region of the head of the pancreas. This disease is rarely a source of pain, but in some cases the late

stages of cancer of the pancreas are accompanied by much suffering, the pain occurring in severe paroxysms.

The most characteristic feature of cancer of the head of the pancreas is jaundice, unaccompanied by pain, but the icterus in these circumstances lacks the yellowness which is seen when the common bile-duct alone is obstructed, for it has a brown tint, not unlike the hue of the skin in Addison's disease. In cases where the jaundice has been relieved by diverting the bile into the colon this brown tint persists.

Glycosuria is an extremely rare complication of pancreatic cancer, and this may be ascribed to the fact that the islands of Langerhans enjoy considerable immunity from the disease. The jaundice is accompanied by irritation of the skin, great depression, slow pulse, and emaciation. The wasting in a measure depends upon the altered digestion and malassimilation, due to the absence of the pancreatic secretion in the alimentary canal. Death is preceded as a rule by coma, the result of toxæmia, and not infrequently from septic phlebitis due to the implication of the large veins in the immediate neighbourhood of the cœliac axis. Œdema of the lower limbs is seen in the late stages as a consequence of thrombosis. It is a curious fact that cancer of the head of the pancreas quickly involves the common bile-duct; it rarely implicates neighbouring viscera, such as the duodenum or the

stomach. Lymph-gland infection is unusual, and dissemination occasionally occurs; the secondary nodules are found in the liver and lung.

Very careful observations have been made in regard to the jaundice caused by the presence of stones in the bile-duct, in order to find a basis of distinction between calculous obstruction and that due to malignant disease of the ducts, the liver, or adjacent organs. It is to be borne in mind that the intensity of the jaundice depends in a large measure on the degree of completeness of the obstruction. A calculus the size of a cherry-stone will effectually plug the duodenal ostium and produce a deep and unvarying jaundice, while in another case the excretory ducts may be blocked with calculi and even the intrahepatic ducts, yet the bile escapes, and the skin may have merely a faint yellow tint. When the following conditions exist the presence of gall-stones in the main ducts is a fair inference, namely the presence and variations in amount of bile in the fæces (this is associated with variations in the degree of jaundice); the liver is of normal size, or only slightly enlarged; no obvious distension of the gall-bladder; and the presence of fever. It must also be remembered that there are varieties of jaundice. The jaundice accompanying acute yellow atrophy of the liver differs from that seen in uncomplicated cholelithiasis; the spinach-green jaundice of the early stage and the black jaundice of the

late stages of hepatic cancer are different from the mahogany-coloured skin seen in jaundice due to primary cancer of the head of the pancreas.

Chronic pancreatitis is frequently mistaken for cancer of the pancreas, the head of the organ being transformed into a hard, nodular mass, which leads to error even in the course of an operation.

From the surgeon's point of view the necessity of distinguishing between gall-stone jaundice and that due to malignant diseases is very great, as it may spare the patient the distress of an unnecessary operation. To this end Cammidge has made some careful observations and elaborated a complex method of examining urine and fæces, for the purpose of determining in a case of obstructive jaundice whether the obstruction is due to calculi which do not involve the pancreas, or whether it is due to disease of the head of the pancreas, or a stone impacted in the ampulla. No very striking success has yet rewarded this earnest and praiseworthy endeavour, nor has it yet found a place in clinical practical chemistry. Cammidge writes :

“The ‘pancreatic’ reaction is only one factor that has to be taken into account in making a diagnosis in suspected cases of pancreatic disease or of jaundice in which it is sought to determine whether there is gross obstruction to the free flow of bile into the intestine, and whether this obstruction, when present, is of a simple or malignant nature.”

Treatment.—The insidious nature of the disease, the almost inaccessible situation of the pancreas, and the large blood- and lymph-vessels in its neighbourhood do not favour surgical enterprise. On one occasion I diverted the bile into the bowel by anastomosing the distended gall-bladder with the hepatic flexure of the colon in a case of pancreatic cancer with jaundice, hoping that if the biliary outflow could be re-established life might be prolonged. This operation was undertaken with the object of deciding if the rapidly fatal character of primary cancer of the head of the pancreas in any way depends on the associated jaundice. The patient, a woman aged fifty years, died in three days from uncontrollable oozing from the operation area, much in the same way that leukæmic patients die from accidental and surgical injuries. In the case of a man sixty years of age with primary cancer of the head of the pancreas I succeeded in anastomosing the gall-bladder into the ascending colon. The jaundice disappeared, but the brown tint of the skin remained, and the disease ran its deadly course uninfluenced. He died a year after the operation.

In order to secure the full benefit of an operation upon a cancerous pancreas it would be essential to remove the whole gland. This in itself would be physiologically disastrous, because experiments on animals demonstrate that complete extirpation of the pancreas is followed by diabetes.

Jaundice associated with a wandering spleen.—This is another, though indirect, way in which the pancreas may induce recurrent attacks of jaundice. Occasionally the spleen will drag upon its pedicle, and so elongate it that the spleen may find its way into any part of the abdomen and pelvis. The tail of the pancreas is sometimes a constituent of such elongated splenic pedicles, and in the operation of splenectomy for such conditions I have on two occasions found it necessary to include the tail of the pancreas in the pedicle. Rokitansky has seen a pancreas so elongated in the pedicle of a wandering spleen that its tail reached the brim of the pelvis.

In one case of wandering spleen in which the pedicle had become acutely torsioned in consequence of axial rotation of a very mobile spleen, the patient was jaundiced on several occasions preceding the splenectomy. The jaundice cleared up immediately after the operation. I attribute the jaundice in this instance to the partial occlusion of the common bile-duct, in consequence of the splenic pedicle dragging upon the pancreas. It may be due also to tension upon the stomach kinking the middle portion of the duodenum. Recurrent jaundice has been noticed in association with wandering spleen by other surgeons.

REFERENCES.

Bland-Sutton, J., "Three Successful Splenectomies."—*Lancet*, 1895, ii, p. 974; and *Clin. Soc. Trans.*, 1901, xxxiv, p. 31.

- Cammidge, P. J.**, "An Improved Method of Performing the Pancreatic Action in the Urine."—*Brit. Med. Journ.*, 1906, 1, p. 1150.
- Hillier, W. T., and Goodall, J. S.**, "The Pancreas in Cases of Carcinoma."—*Archives of the Middlesex Hospital*, 1904, xi, p. 1.
- Riedel, Prof.**—*Die Pathogenesis Diagnose u. Behandlung d. gallensteinleidens*, 1903.

CHAPTER XII

THE SYMPTOMS, SIGNS, AND DIAGNOSIS OF CHOLELITHIASIS

GALL-STONES are very common : in women they are five times more frequent than in men. Cholelithiasis is rare before the twenty-fifth year ; it is common between the twenty-fifth and fortieth year, but is most frequent in individuals after the fortieth year, and the liability of both sexes increases with age. Soft gall-stones have been seen in the newly-born and infants ; the concretions at this early period of life are of the bilirubin-calcium kind. Biliary colic occurs in infants, and as the attacks resemble renal colic the cause of the pain is likely to be overlooked.

Gall-stones may exist in the gall-bladder many years, and their presence be entirely unsuspected until they are detected in the course of an abdominal operation or during the performance of a *post-mortem* examination. They become troublesome under two conditions : (1) when they migrate, and (2) when the main ducts and the gall-bladder become infected with pathogenic micro-organisms.

The troubles which ensue in either event will be considered under the following headings :

- (1) Pain and colic.
- (2) Nausea and vomiting.
- (3) Jaundice.
- (4) Fever.
- (5) Hæmorrhage.
- (6) The enlargement of the gall-bladder.

(1) **Pain and colic.**—When a stone becomes impacted in a duct, pain is a prominent and often agonising symptom. The pain is usually localised to the region of the right hypochondrium and may be of a dull aching character, but when severe it will extend widely over the abdomen. Even when the pain assumes the form of a dull ache it is usually intensified by firm pressure over the gall-bladder. When this organ is acutely inflamed the overlying parts are so tender that the patient cannot bear even gentle pressure from the examining fingers. The most tender spot lies exactly below the costal cartilages under cover of the upper part of the right rectus muscle. Cholelithiasis and cholangitis give rise to referred pain which is of diagnostic value. A common pain in this disease occurs in the right subscapular region, and another situation is on the right side of the back, on a level with the twelfth thoracic vertebra.

In perforative cholecystitis, the pain is more diffuse and resembles that which occurs in acute perforation

of the stomach or the vermiform appendix. The sudden paroxysms of pain termed "colic" are a common feature of the passage of a hard body along a mucous canal scarcely large enough to contain it. Colic is such a well-known sign of gall-stones that the paroxysm of pain from the migration of a gall-stone is known as "biliary colic." The passage of a gall-stone along a bile-duct is in itself a condition usually associated with pain, and it is certain that this pain will be intensified when the stone is forced by spasmodic muscular contractions (cramps) along an inflamed bile-duct. The passage of a gall-stone through a fistula from gall-bladder into duodenum is sometimes accompanied by acute pain. These attacks of colic are very sudden in their onset, may last a long time, and, as a rule, end suddenly. Occasionally biliary colic is so severe that the patient will leave the bed and lie doubled up, or even roll about on the floor. In rare instances patients have died from agony in a gall-stone attack.

The colic associated with the movement of gall-stones in the ducts, a stone in transit along a ureter, or a foetus through the mouth of the uterus is due to the same cause, spasmodic contraction (cramp) of involuntary muscular tissue stimulated to force a hard body along a duct.

The signs of acute cholecystitis are common to certain other abdominal conditions, such as acute appendicitis or acute pancreatitis, perforation of

the stomach, volvulus of the intestine, or axial rotation of an ovarian tumour. Pain is the early predominant feature, situated under the right costal arch; it is severe and paroxysmal and may extend to the epigastrium and down the right side of the belly. This pain is attended with nausea, vomiting, fever, a rise in the temperature, and distension of the abdomen, followed by great prostration and collapse. It is sometimes stated that jaundice is absent, but if the patient be carefully examined a slight yellowness of the skin and conjunctivæ is usually present. In some cases the violence of the symptoms subsides in the course of twenty-four hours, but in the very septic and perforative cases they become intensified and demand prompt surgical interference. So dangerous are some of the cases of acute gangrenous cholecystitis that they require surgical interference as urgently as a case of gangrenous appendicitis.

(2) **Nausea and vomiting.**—These symptoms are as common in cholelithiasis as in biliary colic, and are associated with it, for in many instances the colic and vomiting are due to the same cause, namely movement of the stone. The vomiting is sometimes very severe and prolonged, and patients are sometimes brought into great peril from the violence of the vomiting. Nausea and vomiting often accompany biliary colic, but they may persist when the colic has subsided, and are often due to the impaction

of a gall-stone in the cystic duct; they are occasionally the chief symptom for which the patient seeks relief, and often under the impression that the trouble is due to some disturbance of the stomach and without any suspicion that the fault lies in the gall-bladder. This is by no means an uncommon experience, more particularly when the pain and vomiting are unaccompanied by jaundice. Such cases are often mistaken for pyloric stenosis or indigestion.

Vomiting is also one of the most prominent symptoms when a gall-stone is impacted in the small intestine, and the amount of fluid ejected by patients in such circumstances sometimes amounts to pints in the course of twenty-four hours.

(3) **Jaundice associated with cholelithiasis.**—Contrary to popular opinion, jaundice is not a common symptom of gall-stones, for when they are contained in the gall-bladder there is no impediment to the free escape of bile along the main duct. When gall-stones lodge in the hepatic or the common bile-duct, and when the mucous membrane of these ducts is inflamed as a sequence of cholelithiasis, then the free flow of bile is hindered and jaundice is produced, its intensity depending on the extent and completeness of the obstruction. It is the custom to state that jaundice is absent in these cases, but this is a random statement; for a critical examination of the skin and conjunctiva will often reveal an icteric tinge in cases where the notes state the absence of jaundice.

Under common conditions it may be stated that a stone in the cystic duct does not cause jaundice, but occasionally a stone in this duct will be large enough to interfere with the main duct and lead to

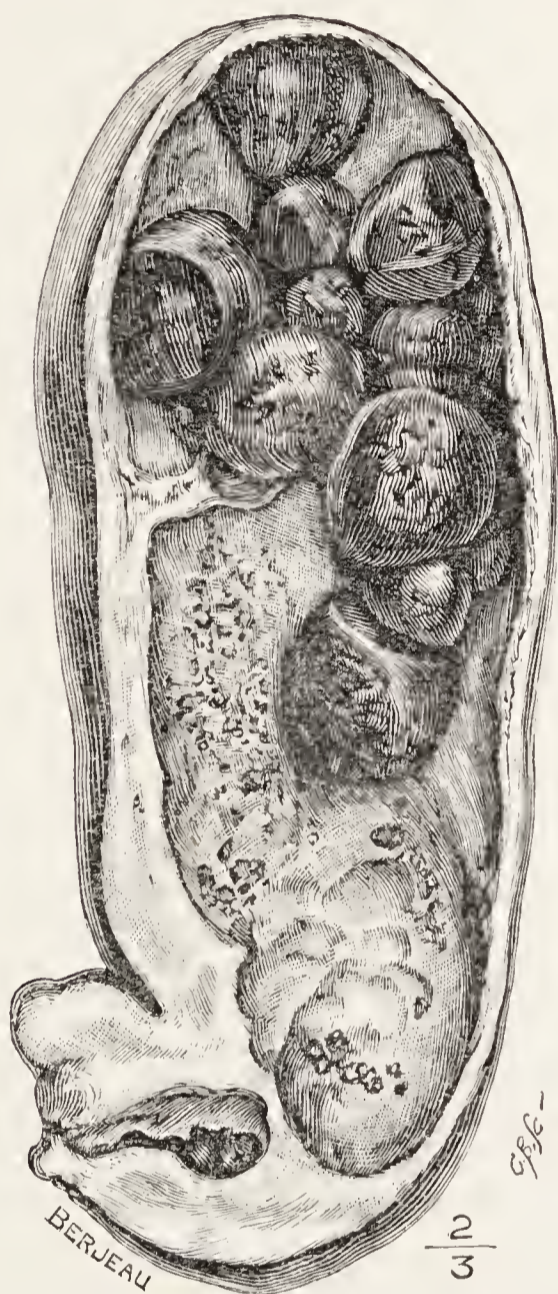

FIG. 50.—An obstructed cystic duct which caused severe vomiting.

jaundice. When a gall-stone is the cause of marked jaundice it is usually associated with local pain and often with colic. Moreover, jaundice caused by a gall-stone usually varies in intensity; at times it will seem to be on the point of clearing up, then a renewed attack of pain or colic occurs, and the colour

deepens. When a stone is firmly impacted in the ampulla the jaundice is deep and does not vary.

There are several unpleasant effects connected with jaundice which it is necessary to consider apart from the cause. Variations in the degree or intensity of the coloration will be considered in detail in connection with the particular cause.

Among the chief inconveniences apart from the annoyance caused by the pigmentation, itching of the skin (*pruritus*) holds the first place; in long-continued and intense jaundice this is very distressing. Sweating is common; the occurrence of the yellow raised patches known as xanthoma is rare. The peculiar raised pink patches known as De Morgan spots are very conspicuous on these yellow skins, but they are of no significance. True purpuric spots are seen in severe jaundice, and it is known that deep and prolonged jaundice is accompanied by retarded coagulation of the blood. Surgical operations on patients who have been long jaundiced are occasionally attended with bleeding difficult to control, especially jaundice associated with cancer of the head of the pancreas.

(4) **Fever.**—The degree of fever associated with gall-stone colic varies greatly. During the attack the temperature may quickly rise to 101°, 102°, or 103° F., and, as a rule, quickly subsides between the attacks. Occasionally it is accompanied by a rigor. In biliary attacks due to secondary infection of the

ducts (acute cholangitis) or of the gall-bladder (acute cholecystitis) the temperature assumes a definite septic type, and may rise to 104° or 105° F., and fails to fall to the normal point.

The peculiar course of the fever associated with gall-stone attacks led Charcot to describe it as "intermittent biliary fever." The ordinary rises of temperature associated with attacks of biliary colic may be described as intermittent in type, but when there is chronic cholangitis the fever is remittent; but in both types the cause is the same—septic infection of the ducts.

The urine.—When the main bile-duct is obstructed the urine is stained with bilirubin before jaundice is obvious in the skin or conjunctiva. This biliary colouring of the urine can be distinguished from other varieties of pigmented urine by the well-known Gmelin's test (p. 14).

In the later stages of obstructive jaundice albumen and renal casts appear in the urine, even in the absence of albuminuria. These casts may contain pigment-granules and pigmented cells.

In extreme degrees of jaundice, with chronic obstruction in the common bile-duct, the urine contains a "mucinoid" substance (a nucleo-albumen) (Parkes Weber).

Fæces.—In obstructive jaundice the fæces are usually offensive, and constipation is the rule. This alteration in colour is due to the absence of urobilin

and other bile-pigments, and an excess of finely divided fat and bubbles of gas causes fæces to assume the appearance known as "clay-coloured."

Detection of gall-stones in the fæces.—After an attack of biliary colic it is the rule to examine the fæces for a week for the purpose of ascertaining if the gall-stones have passed into the intestine. This is an important detail, as it serves to clinch the diagnosis if they are found, as well as a satisfaction to the patient to know that the immediate cause of trouble has escaped from the bile-passages. A proper examination of the fæces requires a little care, and the readiest method is to mix a little weak solution of carbolic acid with the evacuation and pour it upon a layer of coarse muslin stretched across a convenient vessel. It is necessary to remember that there are many solid bodies which escape with the fæces which, from their shape and density, are easily mistaken for gall-stones. In this matter the doctor must not allow his credulity to be imposed upon by statements, however circumstantial, made by patients. Some of the smaller bodies, often called "biliary gravel," constitute a group to which the term "sable intestinal" has been applied by Laboulbene. These consist often of the seeds of fruit. The globular bodies found in the fæces when patients take olive oil for the relief of the gall-stones are often mistaken for actual calculi; these bodies and other "food residues" have been carefully studied by Delepine.

(5) **Hæmorrhage.**—Losses of blood in association with cholelithiasis occur in a variety of ways ; among these the most important are those met with in long-standing jaundice, and the hæmorrhage may take place from the gastric or intestinal mucous membrane, and it may be so frequent and abundant as to cause death. The peculiar tendency of patients with chronic jaundice to bleed, especially after slight injuries or as a result of surgical operations, has been especially noticed in the jaundice produced by cancer of the head of the pancreas. The liability of chronically jaundiced (cholæmic) patients to bleed is a factor which has to be seriously weighed when an operation is under consideration. Chloride of calcium has, in my experience, no effect upon it. Small doses of adrenalin are useful.

Gall-stones when they cause ulceration of the mucous membrane of the gall-bladder occasionally set up serious and even fatal bleeding. The same thing may happen from ulceration of the bile-duct. Fatal bleeding has followed the passage of a gall-stone from the gall-bladder into the duodenum or the stomach through a fistula.

(6) **Enlargement of the gall-bladder.**—When the cystic duct is obstructed by a gall-stone, the gall-bladder will become distended with mucus and often attain the size of a fist ; in rare instances it may be as big as the patient's head, and in the case of a woman it has been mistaken for an ovarian cyst (p. 80).

When a gall-bladder large enough to be felt through the abdominal wall is tender to the touch, it may contain gall-stones and pus, or it may be cancerous. A large gall-bladder which is not painful or tender and associated with deep jaundice indicates, in most instances, that the obstruction of the main bile-duct is due to cancer in the head of the pancreas or primary cancer of the common bile-duct.

Although in a normal condition the gall-bladder projects beyond the free edge of the liver and comes into relation with the right costal arch at a point where the ninth costal cartilage joins the eighth, it cannot be appreciated with the fingers even when distended with bile. When enlarged as a result of inflammation (cholecystitis), or distended with mucus secondary to blocking of the cystic duct, or enlarged in consequence of cancer, it may be perceived as a smooth pyriform body projecting below the right costal arch ; under such conditions it is easily recognised. All surgeons with particular experience in operating on the liver must have performed operations on the notion that they certainly felt the gall-bladder forming a subcostal swelling, and have been surprised on exposing the parts to find the swelling really due to the liver with the gall-bladder safely ensconced under its margin.

When the gall-bladder is the seat of an acute inflammation (acute cholecystitis) its walls become greatly thickened, and the liver-tissue bounding the

sulcus in which the gall-bladder is lodged becomes congested and swollen; as a result the gall-bladder appears imbedded in the liver. In some cases the gall-bladder as it enlarges will push a process or tongue of hepatic tissue covering its fundus beyond the free margin of the liver. Linguiform processes of this kind covering the fundus of an enlarged gall-bladder have been particularly studied by Riedel; sometimes they are long enough to reach as low as the navel, or even Poupart's ligament.

The museum of St. Bartholomew's Hospital contains a gall-bladder whose fundus occupied the sac of a femoral hernia. A woman aged forty-five years was admitted with a right femoral hernia. The sac was opened and the contents were returned. She died of peritonitis some days later. On *post-mortem* examination the gall-bladder was found close to the ring, and a decided constriction was visible some little distance beyond the fundus. A portion of the groove on the inner side was ulcerated. The constriction and ulceration are still visible. The liver did not present the ordinary form; it was elongated from above downwards, and drawn towards the ring. There was no evidence that any portion of the intestine or other structure besides the gall-bladder had passed through the femoral ring.

Dr. Christina Mayne found the fundus of the gall-bladder in the sac of a hernia, three inches below the right costal margin. The patient, a Hindu

woman, aged fifty, noticed the swelling appear when she was doing some heavy grinding a month before she sought advice. The hernial sac was lined by peritoneum. "The edges of the stricture round the neck formed by the abdominal muscles were snicked," a few adhesions liberated, and the gall-bladder

FIG. 51.

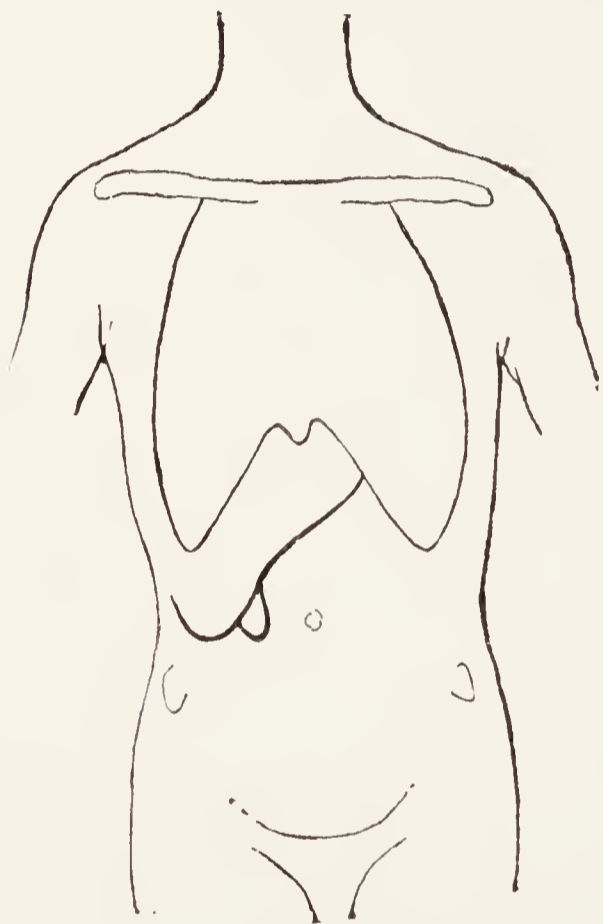
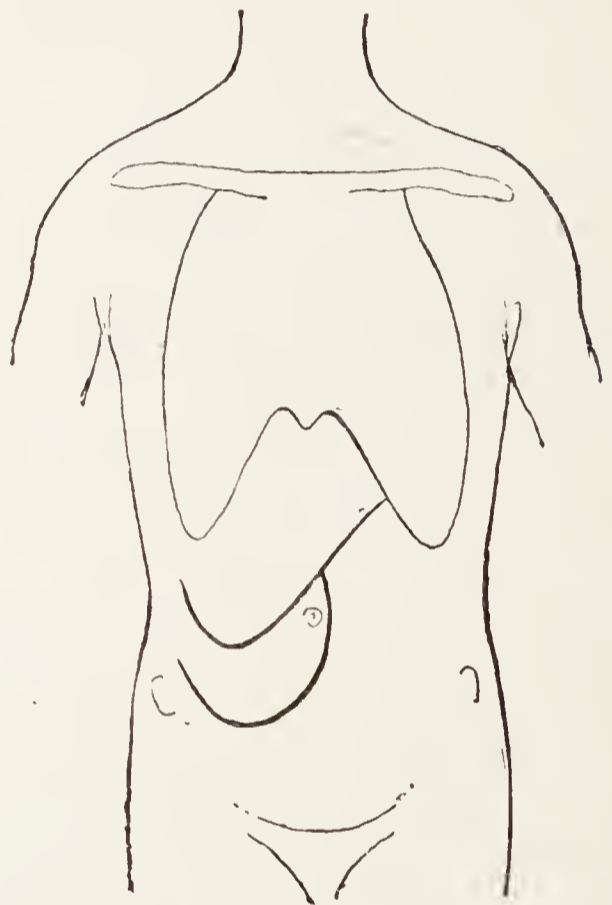


FIG. 52.



FIGS. 51 and 52.—Diagrams to show a linguiform lobe of the liver associated with an enlargement of the gall-bladder. (After Riedel.)

returned to the abdomen. The patient recovered (*Hanson*).

These linguiform processes (or Riedel's lobes) of the liver are distinct from the pedunculated processes sometimes found along the free margin of the liver in women, and usually attributed to "tight lacing."

Riedel points out that when a patient has symptoms of cholecystitis, or attacks of biliary colic, the presence of a linguiform process of liver points to an underlying enlarged gall-bladder (Figs. 51 and 52).

Adventitious lobes of the liver occur independently of diseases of the gall-bladder or "tight lacing," and when large they are sometimes very puzzling and apt to be mistaken for a movable kidney, renal cyst, or a tumour.

It is also certain that when a linguiform lobe is due to acute cholecystitis and the gall-bladder is removed (cholecystectomy) this local enlargement of the liver subsides and the "lobe" disappears.

When a gall-bladder has been the seat of an acute cholecystitis and the inflammatory products escape either by the ducts or in consequence of a fistulous communication with the bowel, stomach, etc., the inflammation subsides or becomes chronic, the walls of the gall-bladder thicken as a consequence of the organisation of the inflammatory products, then sclerosis follows and the gall-bladder shrinks, and, if it be free of concretions, may completely atrophy. Should it contain gall-stones such complete disappearance is prevented and the gall-bladder will be found in its fossa well removed from the margin of the liver (Fig. 26). In the early days of gall-stone surgery, when it was the custom to stitch the gall-bladder to the margins of the abdominal incision, the treatment of these shrunken gall-bladders gave

much anxiety. Now, of course, they are excised (cholecystectomy), and with good consequences.

The relation of a cancerous gall-bladder to the liver margin is instructive in comparison with the effects of an inflamed gall-bladder. When the cancer remains encapsuled within the gall-bladder it will produce the same signs as a mucocele (hydrops); that is, the fundus will project like a large pear beyond the free margin and drag a tongue-like process of the liver with it. When the carcinoma is of the infiltrating type the liver will become implicated, and the parts forming the fossa will also enlarge and overshadow the gall-bladder (Fig. 44) as in acute suppurative cholecystitis.

The diagnostic localisation of gall-stones in the excretory apparatus of the liver.—It is one thing to determine that a patient has gall-stones, but it is quite another matter to define their position, and this is an important consideration in their surgical treatment. It was from this point of view that the two chapters dealing with the effects of calculi in the gall-bladder and in the common bile-duct were written with such detail, for if this matter is thoroughly grasped it will greatly assist in the framing of a diagnosis. When a stone completely plugs the common, or the hepatic duct, it causes severe colic, pain, vomiting, intense jaundice, and fever.

In chronic obstruction of the common duct there

are pain, varying in degree, jaundice, which is variable in its intensity, accompanied by corresponding alterations in the colour of the fæces, intermittent fever, and occasionally a tendency to bleeding from the gastro-intestinal tract. The gall-bladder is usually shrunken, or so contracted and withdrawn under the margin of the liver that it cannot be palpated, but tenderness and pain are evoked when pressure is made by the finger on the abdomen in the upper part of the right rectus abdominis muscle.

In acute cholecystitis a tumour is often detected in the neighbourhood of the right costal arch; this may be the enlarged gall-bladder, but more often it is an enlarged, engorged, and tender process of liver overshadowing the gall-bladder (Riedel's lobe). The constitutional disturbance in these cases is often great, the fever high, and the pain very severe. The attack may begin suddenly, with colic and rigors, which quickly produce great depression and collapse, and no sign of jaundice.

The severe conditions due to rupture of the gall-bladder and perforation of the bile-ducts are more particularly considered in the ensuing chapter, which is devoted to differential diagnosis.

It is also important to bear in mind that when gall-stones infest all portions of the excretory apparatus at the same time—and this is by no means uncommon—it is difficult to decide in which part of the system the mischievous gall-stone is situated.

A valuable feature from the diagnostic point of view is the sudden enlargement of the gall-bladder accompanying colic and without jaundice, as this indicates that a stone has blocked the cystic duct.

Skiagraphy.—In consideration of the great uncertainty which often attends the diagnosis of gall-stones, great systematic efforts have been made to employ the X-rays for their detection. Occasionally shadows have been obtained and the calculi successfully extracted on the evidence thus afforded, and the analysis of such calculi has shown that they contained an unusually large percentage of carbonate of lime (chalk).

A set of almost pure carbonate of lime calculi from the gall-bladder is represented in Fig. 13 (p. 53). I had these carefully tested by the X-rays, and they threw very strong shadows.

The methods of skiagraphy are useless for the routine detection of gall-stones, and those who have tried the method extensively are the most convinced of its uselessness for this purpose.

Regular and irregular cholelithiasis.—These terms occur frequently in reference to the clinical aspect of this disease; they were introduced by Naunyn, and he employed the term **regular cholelithiasis** for those cases in which a gall-stone traverses the bile-ducts and enters the duodenum without inflicting any considerable amount of permanent damage, and the disturbance associated with their passage mani-

fest itself in the typical biliary colic and transient jaundice which is the most characteristic and simple manifestation of gall-stone disease. Under the term **irregular cholelithiasis** he included the various morbid affections of the ducts and liver which develop as sequelæ of gall-stones, such as cholangitis, cholecystitis, fistulæ, etc., conditions which often complicate the incarceration of gall-stones in the bile-duct system.

Riedel, in reference to gall-stone attacks, terms those "unsuccessful" in which the stone does not pass beyond the cystic duct. In "successful" attacks the calculus reaches the common duct and escapes into the intestine.

REFERENCES.

- Delépine, S.**, "Sable Intestinal and some other Intestinal Concretions."—*Path. Soc. Trans.*, 1890, xli, p. 111.
- Hanson, H. B.**, "Hernia of the Gall-bladder."—*Brit. Med. Journ.*, 1907, p. 11.
- Richardson, M. H.**, "Acute Inflammation of the Gall-bladder."—*Amer. Journ. of the Med. Sciences*, 1898, new series, cxv, p. 629.
- Riedel, Prof.**, "Ueber den zungenformigen Fortsatz des rechten Leberlappens und seine Pathognostische Bedeutung für die Erkrankung der Gallenblase nebst Bemerkungen ueber Gallensteinoperationen."—*Berl. klin. Wochens.*, 1888.
- Weber, F. Parkes**, "A Discussion on the Proteids which may occur in the Urine."—*Path. Soc. Trans.*, 1900, li, p. 176.

CHAPTER XIII

DIFFERENTIAL DIAGNOSIS OF CHOLELITHIASIS

IN describing the various diseases to which the excretory apparatus of the liver is liable, each, considered separately, is stated to produce definite pathologic effects, but when these effects are expressed as symptoms we shall find it is not so easy to determine the exact pathologic condition which produces those symptoms, and this becomes a matter of very great importance to the patient, whether it means for him the necessity of submitting to a serious operation, or a forecast as to the effect the condition may produce on his health, or the manner in which the disease may imperil his life.

It is true that the diagnosis of gall-stones is in many instances a simple clinical exercise, and it is often easy to decide that a gall-bladder is filled with gall-stones and pus, or that the common duct contains an obstructing calculus: there are many cases which require clinical experience as well as acumen to determine whether a lump under the right

costal arch is an enlarged gall-bladder or a pathological condition of a contiguous organ. This uncertainty is increased when there is well-marked jaundice associated with a lump in the right hypochondrium.

In describing the symptoms and signs of cholelithiasis it was pointed out that they consist of pain and colic, nausea and vomiting, jaundice, fever, enlargement of the gall-bladder, and hæmorrhage. It will, therefore, be convenient to discuss briefly the conditions in which such signs and symptoms are leading features of diseases which strongly simulate, in their clinical characters, morbid conditions of the excretory apparatus of the liver.

(a) **Pain and colic.**—There are many abdominal conditions which simulate the pain, and also the colic, which is so frequently associated with gall-stones. The sudden pain which is produced by the migration and impaction of a renal calculus in the ureter resembles very strongly biliary colic, and this holds true for sudden distension of the renal pelvis with urine (acute hydronephrosis) when the kidney is sufficiently mobile to allow the ureter to become kinked. The sudden abdominal pain associated with perforation of the stomach, intestine or vermiform appendix, the rupture of a gravid tube or an ovarian cyst will produce the same signs of shock that attend the sudden impaction of a gall-stone in the common or cystic duct, the perforation of the gall-bladder,

the rupture of an echinococcus cyst of the liver, an aneurysm of a visceral artery ; or the intestinal shock which follows the impaction of a gall-stone in the ileum, a volvulus of the intestine or acute obstruction from a band ; or the colic associated with the transit of some indigestible substance traversing the alimentary canal.

In addition to these, the sudden attacks of pain known as gastric crises which occur in tabetic patients, and the colic characteristic of lead-poisoning have been mistaken for biliary colic.

To show how difficult it may be to correctly interpret abdominal colic the following instance will serve : A patient, aged thirty years, was seized with such acute pain that her screams alarmed the household, and a physician who was in the house considered that she had an ovarian tumour which had rotated and twisted the pedicle. Her usual medical attendant attributed the pain to gall-stones. At a consultation three days after an examination under ether I thought the signs might represent an attack of appendicitis. An operation was performed and the belly was found filled with blood in consequence of the bursting of a gravid Fallopian tube (right) : the gall-bladder and cystic duct contained several large calculi, and the appendix was the seat of chronic inflammation.

Apart from the attacks of renal colic, the pain associated with chronic cholecystitis and cholangitis

is similar to that which occurs with chronic ulcers near the pylorus, either on the gastric or the duodenal side of this strait. Aneurysm of the hepatic artery, cancer of the hepatic flexure of the colon, and bands of adhesion between the gall-bladder and pylorus or colon, the result of chronic pericholecystitis, produce puzzling painful symptoms.

There are few things in surgery so difficult to unravel as persistent right-sided pain in women; for it may relate to the excretory apparatus of the liver, the stomach and duodenum, the colon, cæcum and appendix, the kidney and its ureter, or the right ovary and Fallopian tube. Further, any one or two of these conditions may complicate cholelithiasis.

Nausea and vomiting.—These symptoms are associated with many abdominal disorders, some of which may be trivial or indicative of accidents of the gravest kind. Thus the reflex vomiting which occurs when a stone is impacted in the cystic duct is similar to that occasionally seen in painful menstruation, whilst the incessant vomiting characteristic of acute septic peritonitis may be due to perforation of a gall-bladder in a state of acute cholecystitis. The character of the vomit may be that indicating intestinal obstruction, and the actual cause of the obstruction is a gall-stone impacted in the intestine.

On the other hand, the vomiting and the vomited matter point to obstruction at the pylorus, either innocent or malignant, and this may be due to a

gall-stone ulcerating through the gastric wall or it may be so large as to constrict the pyloric orifice.

Attacks of renal colic are usually accompanied with vomiting, and it is necessary to remember that although there is no connection between renal lithiasis and cholelithiasis the two conditions occasionally complicate each other.

Jaundice (icterus).—There is no clinical sign more striking or less misleading than the yellowness of the skin to which the term “ jaundice ” has been applied from the earliest times in the history of medicine. This yellowness is due to the impregnation of the tissues with bile-pigment. The coloration varies in intensity and in duration according to its cause, and a careful study of these variations is a great help in diagnosis. In cases where jaundice is very pronounced and of long standing every tissue and fluid of the body will be stained by it, even the vitreous humour, and in these circumstances the patients may complain of xanthopsia (yellow vision). The only exception to this otherwise universal presence of biliary colouring matter is the *faeces* of the patient, which are cream- or clay-coloured, from its absence when the jaundice is due to obstruction.

Jaundice arises from a variety of causes, and it has long been customary to arrange them under two headings :

(1) Those which induce jaundice by obstructing the hepatic or the common duct (obstructive jaundice).

(2) Those which lead to jaundice without interfering with its escape from the bile-duct (unobstructive jaundice).

Unobstructive or "toxæmic jaundice" occurs in the course of specific fevers, such as yellow fever, malaria, typhus, typhoid and relapsing fever, scarlatina, pyæmia: in poisoning by phosphorus and arsenic and as a consequence of snake-bites. Jaundice is a marked symptom in acute yellow atrophy of the liver. There is a variety seen in new-born children and named in consequence "icterus neonatorum," associated with septic omphalitis, which must not be confounded with jaundice due to congenital obliteration of the bile-duct (see Chap. IV).

Obstructive jaundice arises from various causes:

(1) Foreign bodies within the common duct, such as gall-stones and very rarely intestinal worm (*Ascaris*, *Distoma*).

(2) Inflammatory affections (cholangitis) and its consequences, leading to ulceration, stricture, and even obliteration of the duct.

(3) Tumours arising primarily in the excretory apparatus of the liver.

(4) Tumours arising in adjacent viscera, involving the duct or pressing upon it; such tumours may arise in the liver, pancreas, stomach, kidney, etc. Enlarged lymph-glands in the portal fissure, aneurysm of the hepatic arteries, rarely pregnancy and ovarian tumours.

(5) An enlarged spleen, and especially a wandering spleen (p. 162).

(6) A mobile kidney will cause jaundice by dragging on the duodenum.

Fever.—Increase of temperature in what is called regular cholelithiasis is the rule, but it is not long maintained, and rises and falls quickly according to the severity and duration of the attack. The fever which accompanies irregular cholelithiasis and due to septic cholangitis may be simulated by any septic affection in the abdomen. For example, an acute septic cholecystitis is hard to distinguish on the score of fever from a pyelephlebitis, a subphrenic abscess, acute pneumonia, a biliary abscess; or those not uncommon cases in which a retrocæcal appendix perforates and gives rise to an abscess immediately under the liver; of this I have seen several examples, and in one instance found the detached terminal section of the appendix lying in contact with the gall-bladder.

Even in cases of intrahepatic abscesses it is difficult to decide between those which arise from cholangitis, cholelithiasis, or septic emboli. In some instances of rapidly growing cancer of the liver the fever may be so high (103° — 105° F.) as to lead to an operation under the impression that the patient has a large hepatic abscess.

Local swelling.—Cholecystitis, calculi, and cancer give rise to enlargement of the gall-bladder so

pronounced and often of such a definite shape that the diagnosis may be made with accuracy, and a differential diagnosis between mucocele, purulent cholecystitis and cancer may be attempted. The enlargement of the gall-bladder is sometimes imitated by cancer of the pylorus or of the colon, or by tumours of the kidney and adrenal. The diagnosis between a movable kidney and a distended gall-bladder has been often attended with difficulty.

A large gall-bladder distended with mucus will simulate a hydronephrosis and *vice versâ*: a very large mucocele will rarely imitate in its clinical features an ovarian cyst, but it has happened, and I have seen twice an ovarian cyst adherent to the gall-bladder, and in one the gall-bladder contained calculi and there was a calculous fistula discharging small gall-stones under the costal arch. Lucy reported a case in which a large ovarian cyst had a fistulous communication with the gall-bladder. An echinococcus cyst on the under-surface of the liver, an aneurysm of the hepatic or of the superior mesenteric artery, especially if they press on the main bile-duct and produce persistent jaundice, cause difficult problems in diagnosis.

The greatest difficulty that I have met in interpreting lumps emerging under the right costal arch apparently connected with the liver is in deciding between an enlarged gall-bladder packed with calculi, or thickened with cancer, and cancer of the liver or

the pylorus. It is shown in Chap. X that a discretely enlarged cancerous gall-bladder may be distinguished with a fair amount of certainty; but when a cancerous gall-bladder is sessile on the liver, and there is cancerous infiltration of the adjacent hepatic tissue, it is mere guesswork to decide between an enlarged gall-bladder or cancer of the liver.

On the whole, some of the greatest difficulties in differential diagnosis in this direction have occurred to me in deciding between cancer of the liver or calculous cholecystitis; and in this I am not alone, for in two examples referred to me by a leading physician, who was unable to decide between the two conditions, he wished the patients to have an operation performed to settle the question. In each the gall-bladder was filled with calculi, but the liver contained nodules of cancer.

Hæmorrhage.—Reference was made in the preceding chapter to severe and even fatal bleeding from the gastric mucous membrane sometimes seen in severe jaundice, apart from that associated with cancer in the head of the pancreas (see Chap. XI). Severe gastric hæmorrhages are seen in cases of portal thrombosis (pylephlebitis), and also in those rare instances in which a gall-stone ulcerating into an adjacent viscus will erode a large vessel such as the pancreatico - duodenalis, or even the hepatic artery.

Among the rarer forms of severe hæmorrhage of

this kind should be mentioned rupture of an aneurysm of the hepatic artery, which may take place into the general peritoneal cavity, or, as has happened in some carefully observed instances, into the gall-bladder or the cystic duct, the blood flowing thence into the intestine (p. 38).

The difficulties met with in framing a diagnosis are often very great when there is only one lesion to deal with, but when two or more are combined—and this is not uncommon—the chances for errors are greatly increased. It is unnecessary to enter into the special diagnosis of each condition as they are dealt with in text-books on medicine.

REFERENCE.

Lucy, R. H., "A Case of Ovarian Cyst communicating with the Gall-bladder containing a Solitary Calculus."—*Lancet*, 1900, i, p. 1132.

CHAPTER XIV

TREATMENT OF CHOLELITHIASIS

THE treatment of disease of the gall-bladder and the bile-ducts depends in the first place entirely on diagnosis ; this, as was pointed out in the preceding chapter, consists in unravelling or sorting out cases in which the signs and symptoms are those produced by malignant disease of the excretory apparatus or of organs immediately adjacent, conditions which rarely admit of radical treatment, and those diseases of the gall-bladder and bile-ducts which are due to inflammatory (infective) causes and to gall-stones, for the majority of these are amenable to surgical measures.

Medical measures against these diseases are in the main palliative, for it is certain that in cases of malignant disease medicine can do nothing to cure the patient, although it is able to relieve many of the distressing symptoms associated with it. On the other hand, in many patients affected with gall-stones medical means can do a great deal to keep them fairly comfortable, although, as we shall see later, the best and wisest physicians are those who

point out to their patients that surgical assistance constitutes the best remedy.

It is customary to speak of prophylactic treatment in these diseases, but the methods prescribed are merely those which constitute the rules of health and are embraced under the simple phrase, "moderation in all things," and this certainly includes drugs. When gall-stones are once formed no amount of medicine will influence them; it is true that many remedies have been recommended for this purpose, including benzoic acid, salicylic acid, turpentine, ether, chloroform, olive oil, and soap pills, but they are all useless. In regard to olive oil it should be mentioned that when taken in large doses it is sometimes discharged from the anus in the form of round balls about the size of marbles, and the patients sometimes imagine that they are gall-stones, and this probably explains the origin of the myth that olive oil is of service in cholelithiasis. These round balls are composed of crystals of fatty acids derived from the oil. Massage applied to the hypogastrium has been advocated with the object of promoting the discharge of gall-stones into the duodenum. This is not merely a futile but a very dangerous remedy.

Although a great deal of experimentation has been carried out to find drugs which will promote the flow of bile, many believe that the best cholagogue is a good meal.

Treatment during a "gall-stone attack."—Although

medical means are of little use in preventing the formation of biliary calculi, therapeutic measures may be of the greatest benefit to a patient when suffering from a gall-stone attack. At this time all the remedies are directed towards the relief of pain.

When the attack is of moderate severity the application of a warm fomentation to the hypogastrium and freely drinking hot water will often bring relief, but if there is much vomiting this method of relief is useless.

The specific remedy is the hypodermic injection of morphine, which may vary in strength from one sixth to one third of a grain according to the amount of pain and the habits of the patients, for if liable to frequent attacks they invariably know the amount which is sufficient to insure relief. The addition of one sixtieth of a grain of atropin to the morphia is deemed useful by some physicians of great experience.

Remedies like phenacetin in 10-gr. doses and aspirin in doses of 5 or 10 gr., repeated in three hours if required, are beneficial. In cases where the pain is very severe it may be necessary to administer chloroform.

After the attack of pain has subsided the fever which accompanies usually subsides also : occasionally it persists for a day or two, and in such circumstances antipyretics are sometimes prescribed, but it is rarely necessary, and usually means that some inflammatory complication exists which would be better treated by

some milder remedial measures in the form of a purge and a course of hot Carlsbad water.

When patients suffer so severely as to need such treatment as the hypodermic use of morphine or inhalation of chloroform, especially if the attacks are frequently repeated, it is an indication that assistance should be sought from a surgeon. It should also be pointed out that in some cases the pain associated with a gall-stone attack may be so severe as to need immediate surgical intervention.

There are two conditions associated with diseases of the bile-ducts which require consideration in the palliative treatment, namely jaundice and its disagreeable accompaniment, constipation and offensive stools. For the latter it is useful to administer saline purges taken in a large quantity of water, or the natural purgative waters such as those of Carlsbad and Vichy may be taken early in the morning. An occasional blue pill is very useful.

The pruritus associated with deep jaundice is sometimes very distressing ; for this there are various remedies, such as the use of an alkaline bath. Few remedies give permanent relief, and in some cases of permanent jaundice patients have submitted to cholecystenterostomy, whereby the bile is diverted into the duodenum or colon. In two cases under my own care the comfort which followed this manoeuvre was very satisfactory. In very deep (black) jaundice even this extreme measure is denied them, on

account of the risk of bleeding. The diversion of bile in this way in an unusual mode of treatment, and rarely necessary.

Surgical treatment.—There is much difference of opinion in regard to the surgical treatment of cholelithiasis and inflammatory diseases of the bile-passages. Some writers hold that the recurrence of biliary colic alone should be regarded as sufficient indication of the necessity of surgical intervention; the majority of surgeons do not take this extreme view, but it is quite certain that the result of surgical intervention in cholelithiasis is rapidly improving, and those who are particularly engaged in what is called “gall-stone surgery” insist that the earlier patients with these diseases submit to treatment the better are the opportunities for success; patients also appreciate this, and as the results improve they show increased willingness to place themselves in the hands of surgeons.

There is a class of cases in which the signs are not urgent, and patients prefer medical treatment to a surgical operation. Clinical observations teach clearly that patients with gall-stones do wisely to have them removed, and the gall-bladder with them. Any hour, any day, and without warning gall-stones may produce what are called fulminating symptoms, and the postponement of an operation for a few hours only may be attended with the most disastrous consequences.

Fortunately, there are conditions in which physicians and surgeons agree in the necessity of surgical intervention. Among these may be mentioned :

- (1) Suppuration (empyema) in the gall-bladder.
- (2) Abscess associated with the gall-bladder or bile-ducts : rupture of gall-bladder.
- (3) External biliary fistula.
- (4) Acute cholecystitis of all varieties.
- (5) Intestinal obstruction due to gall-stone.
- (6) Enlargement of the gall-bladder.
- (7) Acute cholangitis.
- (8) In frequently recurring biliary colic, with or without enlargement of the gall-bladder.
- (9) When there is reason to believe that there is chronic pancreatitis associated with a gall-stone in the ampulla.
- (10) Atrophic gall-bladders containing calculi.

The conditions which exercise the judgment of the surgeon most are those associated with deep and persistent jaundice. This is due to the fact that the commonest cause of permanent jaundice is cancer of the head of the pancreas, primary cancer of the main duct or the ampulla, or cancer of the liver (primary or secondary). It is sometimes due to a calculus firmly impacted in the ampulla. The chief reason which makes the surgeon hesitate is that in cancerous conditions his interference may not only be useless, but in jaundice of long standing, operations

are attended with very free and often uncontrollable bleeding.

Lawson Tait many years ago told surgeons that the best results in gall-stone operations were attained in cases unassociated with jaundice. This opinion holds good to-day.

Although there is substantial agreement among surgeons as to the main indications for surgical interference in cholelithiasis, there are certain problems remaining in an unsettled condition. Fortunately, the importance of drainage in these operations and the necessity of taking minute pains to clear the bile-ducts are points now thoroughly appreciated. There is, however, no unanimity as to the expediency of removing the gall-bladder in preference to draining it. My own experience is decidedly in favour of cholecystectomy. In 1890 I published some observations on this matter, and increased experience has convinced me that it has all the safety and none of the drawbacks which were so troublesome after cholecystotomy, such as biliary and mucous fistulæ, suture sinuses, abscess, and the formation of gall-stones on buried sutures. Moreover, when the surgeon decides to remove a gall-bladder he makes the most thorough investigation of the main ducts to satisfy himself that they are free from calculi.

Increasing experience is teaching us in regard to the surgical treatment of gall-stones that the best results follow when diseases of the gall-bladder are

treated on the same lines as diseases of the vermiform appendix.

The Principles of Surgical Treatment.

There are three principles underlying the surgical treatment of gall-stones which must be steadily kept in view :

(1) The thorough removal of the calculi.

(2) The permeability of the bile-ducts must be restored ; and

(3) The inflammation must be suppressed ; this invariably entails drainage.

Contra-indications of operations.—It is difficult to state in mild or chronic cases of cholelithiasis what particular conditions contra-indicate surgical intervention, especially in face of the fact that men and women without the least suspicion that they possess calculi in their gall-bladders, or complain of merely temporary uneasiness, are suddenly seized with severe abdominal pain and die in the course of three days from acute septic peritonitis set up by perforation of a suppurating or sloughing gall-bladder, or intestinal obstruction due to the impaction of a large gall-stone in the ileum.

On the other hand, in some of the more chronic cases there are certain conditions which bar operative interference in cholelithiasis, such as ascites, diabetes, arteriosclerosis, chronic pulmonary disease, and serious cardiac disease, and occasionally extreme

obesity ; advanced cancer of the biliary passages, and as a rule cancer of the gall-bladder, for when this disease is recognisable it rarely admits of successful surgery. Patients with complete jaundice of long standing are bad subjects for operation, especially if there be also bleeding from the mucous membranes.

CHAPTER XV

OPERATIONS ON THE EXCRETORY APPARATUS OF THE LIVER.

SUCCESS in the operative treatment of the diseases of these organs depends in general upon manipulative dexterity, minute attention to the details of asepsis, and particularly on careful drainage.

Surgical dexterity can only be acquired by practice, but the principles underlying what is commonly called "gall-stones operations" should be first acquired by watching, or, what is far better, assisting an experienced surgeon in the performance of such operations. The removal of gall-stones is such a common proceeding in the hospitals of large towns that no one should be so rash as to undertake operations of this character without some such preliminary training.

The preparation of the patient.—It rarely happens that an operation is so urgent as to leave little time for an elaborate preparation of the patient. It is desirable that the preliminary preparation should occupy two days at least. During this time the

patient is kept in bed and the bowels freely evacuated, either by calomel at night, with a saline draught in the morning, or an ounce of castor-oil.

On the morning of the operation the large bowel is thoroughly emptied by a soap and water enema, care being taken to use soft soap, to avoid producing a pimply eruption known as the "enema rash."

It is well known that injuries to the abdominal organs, whether accidental or in the course of a surgical operation, are liable to be followed by septic parotitis. Recent writers attribute this complication to microbic infection of the ducts of the salivary glands; its occurrence may be avoided by including careful cleaning of the teeth among the preliminaries advisable for an abdominal operation. It is such a simple and comfortable ordinance that there is no reason for not following it.

The preparation of the skin needs to be very thoroughly carried out. After a warm bath the hair is shaved from the abdomen and lower part of the thorax, the skin is well washed with warm soap and water and swathed in gauze compresses wrung out of a solution of perchloride of mercury 1 in 5000. These compresses remain for twelve hours. The abdomen is again washed with soap and water, followed by a second compress, which remains on until the operation.

The washing and application of compresses requires care on the part of the nurse, for some patients

have skin so tender that it is easily blistered, and a crop of small pustules is a source of inconvenience, and leads to stitch abscesses. In certain cases over-preparation may be worse than no preparation.

Many gall-stone patients are advanced in years; it is therefore extremely necessary to protect them from being chilled by undue exposure. It is well to clothe their lower limbs in warm flannel garments or by drawers made out of Gamgee tissue. No open doors or windows should be permitted; though this in summer is comfortable to the surgeon it may be disastrous to the patient. In winter the temperature of an operating-room should not be below 65° F. In this way ether pneumonia is best avoided.

Instruments.—An experienced surgeon requires few instruments. The following are necessary: a knife, dissecting forceps, twelve hæmostatic forceps, two scissors, six curved needles of various sizes, a scoop, reels of silk of three different thicknesses, a syringe for emptying the gall-bladder, a probe, six dabs, and rubber tubing.

The instruments are metal throughout to permit of immersion and boiling in the steriliser. Silk should be boiled for an hour immediately before being used.

The instruments are placed in shallow trays filled with sterilised water on a table in a situation convenient for the operator.

Dabs.—These should be made out of Gamgee

tissue, or folds of plain gauze, cut into squares of convenient size and carefully hemmed round the cut edges. These are boiled for an hour immediately before use and during the operation washed in warm sterilised water. When the surgeon always uses a definite number he is spared the risk of leaving one in the abdomen.

In every form of abdominal operation I use six dabs, and vary their size according to the nature of the operation. The dabs should always be counted by the surgeon before beginning an operation, and again before closing the incision, and as a safeguard he should count them a third time before the patient leaves the theatre. The responsibility in regard to the dabs belongs to the surgeon alone, and he is unwise who intrusts this important duty to a nurse, however conscientious and experienced. Moreover, his responsibility in this matter rests upon a decision given in a court of law (1905).

Gloves.—Increasing experience proves that gloves are most valuable in securing freedom from sepsis. It is a very important matter that the surgeon, the assistant, and the nurses who help at the operation should wear rubber gloves boiled immediately before the operation for ten minutes.

The wearing of gloves diminishes the mortality of the operation and minimises its unpleasant and often dangerous sequelæ, such as suppuration around sutures, septic emboli, tympanites, and the like.

Care must be taken to impress upon all who take part in an operation that it is as essential to thoroughly wash and disinfect the hands before inserting them in gloves as when no gloves are worn.

To the operator thorough disinfection of the hands is of the highest importance, for he may puncture or tear the gloves during the operation; or a difficulty may arise in the course of it which will render it advantageous for him to remove one or both gloves to overcome it. It is with me a rule that if in the course of an operation it is necessary to remove the gloves I resume them for the final stages, and particularly for the insertion of the sutures. The use of rubber gloves marks a most important advance in operative surgery.

The anæsthetic.—My own practice in this matter is to employ an experienced anæsthetist and leave the responsibility of the choice of an anæsthetic to his judgment. Otherwise the most comfortable proceeding, from the patient's point of view, is to initiate anæsthesia with nitrous oxide, continue it with ether, and then judiciously maintain it with chloroform.

Gall-stone operations are so common in elderly patients that it is very disappointing to carry through a difficult operation and then to find the patient at the brink of the grave from ether pneumonia.

It is a matter of the first importance that the anæsthetist selected for operations of this kind should suit the anæsthetic to the needs of the patient rather than act upon prejudice. He should keep the patient quiet with the minimum amount either of ether or chloroform, and the surgeon should remember that every minute the patient is unconscious is a minute of grave peril. It is silly to urge that quick surgery is unnecessary; the quick and neat operator shows results far better than his slow and often clumsy colleague.

Position of the patient.—The patient lies on his back, with a sand-bag (measuring 18 in. in circumference and 24 in. in length) under his back about the level of the liver. This allows the intestines to fall towards the pelvis, and causes the liver to project, and brings the gall-bladder and bile-ducts towards the incision. This manœuvre, which we owe to Elliott, of Boston (1895), is as useful in operations upon the excretory apparatus of the liver as Trendelenberg's position facilitates operations on the pelvic organs in women. This sand-bag should be removed before the sutures are inserted, as it, in a measure, tends to make tense the fibres of the rectus muscle.

In arranging the patient for operation, the arms, thorax, and pelvis are protected by sterilised towels, and every hospital worthy of the name and every properly equipped surgical home possesses apparatus

for the sterilisation of towels, sheets, etc., and dressings which come in direct contact with the patients; also the overalls worn by all engaged in the operation, whether surgeons, assistants, onlookers, or nurses. Thus, as instruments, dabs, ligatures, towels, overalls, gloves, bowls, and dressings are sterilised, it may be truly stated that in a modern operation everything is boiled or submitted to superheated steam except the patient.

The incision.—The best access to the gall-bladder and common duct is afforded by a vertical incision in the right rectus muscle near its outer border. This can be extended when necessary by prolonging the incision parallel with the costal border towards the ensiform cartilage. The incision in the first instance should be four inches in length or longer in fat patients and extend to the abdominal aponeurosis. It is rarely necessary to incise the fascia and muscle to the same extent as the skin, but it is far better to freely incise the parietal structures in a patient, where access to a stone impacted in the duodenal section of the duct is difficult on account of fat, than to run the risk of bruising the stomach and intestines. It is when the liver lies well up under the ribs that the oblique median extension of the incision is particularly indicated. In a very exceptional case Fenger found it necessary to excise four inches of two costal cartilages in order to obtain access to the gall-bladder. It is sometimes a dis-

advantage to have the vertical incision too long, because it allows the colon and omentum to hamper the surgeon by escaping from the abdomen.

In the course of the incision numerous arteries are divided, and it is useful to ligature these before proceeding with the subsequent stages of the operation. The edges of the divided peritoneum are then caught on each side of the wound with forceps, and a dab introduced to restrain the viscera within the abdomen; the surgeon then makes a careful inspection to determine the nature of the case with which he has to deal.

His attention is usually directed to the gall-bladder; this may be easily recognised, but it is very often obscured by omentum, or by adhesions to bowel or stomach, which renders it a matter sometimes of anxious difficulty to disentangle the adhesions without damage to colon, stomach, or duodenum in order to expose the gall-bladder, and in some rare cases this structure is atrophied and unrecognisable. It has happened to me on two occasions to remove stones from the gall-bladder and fail to see the liver on account of adhesions. After the operator has satisfied himself as to the condition of the gall-bladder, a careful examination of the cystic, hepatic, and common ducts is then made in order to be sure that they contain no stones or growth. This preliminary inspection should also include the head of the pancreas and the pylorus. When the adhesions

interfere with a thorough inspection of the terminal section of the common duct it is useful to carefully tear through the gastro-hepatic omentum and enter the lesser bag of the peritoneum (the bursa epiploica); this affords convenient access to the retroduodenal segment of the common duct.

After a complete survey of the parts the surgeon determines which particular operation is necessary. For example, the gall-stones may be confined to the cystic duct and gall-bladder, or they may occupy the common duct. It is by no means uncommon to find stones in the gall-bladder, cystic duct, and common duct, and in each situation an incision may be required for their removal. In my own experience it has been necessary to perform cholecystotomy (or even removal of the gall-bladder), choledochotomy, and choleduodochotomy at one operation in order to thoroughly free a patient from gall-stones. On the other hand, when the surgeon opens the abdomen with the hope of removing gall-stones he may find cancer of the head of the pancreas, gall-bladder, liver, the pylorus, or colon. Moreover, gall-stones frequently coexist with the serious diseases just mentioned, and it will require determination and judgment as well as experience to decide the best course to pursue in the circumstances.

The method of suture.—After a trial of many methods, that which has given me the best results is, in thin patients, to secure the wound with silk

sutures traversing the whole thickness of the abdominal wall; these sutures are inserted about 2 cm. apart. In all cases where interrupted sutures are used it is wise to run a continuous suture of thin silk along the skin edges to prevent overlapping. Some of the sutures are removed about the tenth, and the remainder on the twelfth or fourteenth day after the operation.

Drainage.—Many operations for gall-stones are performed for conditions distinctly septic, and apart from this quite a number of them are followed for a time by a free escape of bile. In order to avoid frequent change of dressing and to keep the patient comfortable, it is necessary to make provision for the collection of the bile by passing the drainage-tube through the dressing and adjusting it to a small sterilised bottle by the side of the patient. When this simple apparatus is neatly managed the dressing may not need changing for two or even three days. In some conditions twenty or more ounces of bile will be collected in twenty-four hours. In septic conditions some surgeons introduce a narrow rubber tube with a lateral as well as a terminal hole directly into the common bile-duct through the opening made for the extraction of the gall-stone and carry the free end through the abdominal incision. This tube is left in position three or four days, or a longer time if necessary, so as to allow contiguous viscera to adhere and shut off the drainage-track from the

general peritoneal cavity. After removal of the tube the opening in the abdominal wound may be maintained by a gauze wick. Direct drainage of the duct in this way is only necessary in septic conditions.

REFERENCES.

- Elliot, J. Wheelock**, "Immediate Suture of the Gall-ducts," etc.—*Annals of Surgery*, 1895, xxii, p. 97.
- Fenger, C.**, "Remarks on Surgery of the Bile-ducts."—*Annals of Surgery* 1898, xxvii, p. 697.

CHAPTER XVI

OPERATIONS ON THE EXCRETORY APPARATUS OF THE LIVER (*continued*)

THESE may be arranged in four groups :

(A) **Operations on the gall-bladder and the cystic duct :**

- (1) Cholecystotomy.
- (2) Cholecystectomy.
- (3) Cholecystenterostomy.
- (4) Cholecystendysis.
- (5) Cysticotomy.

(B) **Operations on the common bile-duct :**

- (1) Choledochotomy.
- (2) Duodeno-choledochotomy.
- (3) Choledocho-duodenostomy.
- (4) Choledochectomy.
- (5) Choledocho-enterostomy.

(C) **Operations on the hepatic ducts :**

- (1) Hepaticotomy.
- (2) Hepato-duodenostomy.

(D) **Operations on the intra-hepatic ducts :**

- (1) Hepato-hepaticotomy.
- (2) Hepato-cholangio-jejunosomy.

(A) OPERATIONS ON THE GALL-BLADDER AND CYSTIC
DUCT.

Cholecystotomy.—This signifies opening the gall-bladder for the evacuation of gall-stones or pus. It is the simplest operation that can be performed for gall-stones. The first deliberate cholecystotomy was performed by Lawson Tait in 1876.

After exposing the gall-bladder through the incision the surgeon ascertains that the troubles are localised to the gall-bladder, and that the common duct is free. The field of operation is then restricted by the insertion of dabs so as to protect the intestine and stomach from contamination. In distributing the dabs it is important to insert one in the recess under the ribs known as the kidney pouch (Rutherford Morison). In isolating the gall-bladder or in detaching it from adhesions there are one or two points which require attention.

The gall-bladder lies in a position which brings it in contact with the stomach, first and second portions of the duodenum, and the colon; with these it is very liable to contract adhesions which will require careful separation. It was pointed out in Chapter V that in calculous cholecystitis the wall of the gall-bladder and an adherent piece of gut may become perforated and the pus and one or more gall-stones be discharged into the intestine or

stomach. When the surgeon attempts to detach a gall-bladder with such adhesions he may open the intestine. In such circumstances the wall of the viscus (stomach or gut, as the case may be) requires careful suture. Occasionally the adhesion is infundibuliform. This requires careful treatment, because the stem of the funnel may contain a minute channel which communicates with the interior of the bowel, and if it be divided in the usual way infection from the gut will follow. This is a real danger, and many patients have lost their lives in consequence of a minute unsuspected fistula of this kind, which has led to fatal peritonitis. The surgeon then feels along the neck of the gall-bladder to ascertain if the cystic duct is occupied by a stone; should one be lodged in this situation he endeavours, without undue force, to gently press it upwards into the gall-bladder, a manoeuvre which is not often successful. This accomplished, the fluid in the gall-bladder (which may be mucus or pus) is withdrawn by means of a needle and syringe, or the gall-bladder when large enough to be drawn through the incision may be opened by a scalpel and its contents evacuated into a vessel.

The withdrawal of the gall-bladder through the incision is sometimes facilitated by gently drawing the right lobe of the liver downwards and then turning it out through the wound. The free extrusion of the parts in this way greatly simplifies the

evacuation of the gall-bladder and the removal of a stone in the cystic duct.

It is of the greatest importance to be sure that all the gall-stones are removed from the gall-bladder and cystic duct. I never feel satisfied until my finger has thoroughly searched its interior. The most satisfactory sign that the cystic duct is clear is to see the freshly secreted (golden red) bile entering the gall-bladder.

It has already been mentioned that it is an advantage if the stones impacted in the duct are reduced into the gall-bladder before this receptacle is opened. This is not always possible, and in such conditions it is necessary to incise the wall of the duct (cysticotomy) in order to extract them. Moreover, it should be borne in mind that the gall-bladder is sometimes so constricted, or hour-glass-shaped, that its lower loculus may contain a stone, and give rise to the impression that it is lodged in a dilated cystic duct. In such conditions, if the surgeon is able to satisfy himself that the main bile-ducts are free it is a wise plan to remove the gall-bladder (cholecystectomy).

The simplest condition in which cholecystotomy can be performed is when the gall-bladder communicates with the exterior by a fistula; in such circumstances all that is necessary is to enlarge the fistula and thoroughly remove all the gall-stones with a scoop.

When the gall-bladder is embedded in adhesions

the operation is very simple, and consists in exposing the fundus, incising it, and extracting the stone or stones. Sometimes it is filled with cholesterin paste, which needs a scoop for its removal. In the ordinary operation of cholecystotomy, after the removal of the gall-stones, the margins of the incision in the fundus of the gall-bladder are secured by sutures to the peritoneal and fascial margins of the abdominal incision. If the contents of the gall-bladder are septic, then a rubber drain must be inserted for a few days; if the contents consist of gall-stones and mucus, and the surgeon has satisfied himself that the ducts are free, there is no need for drainage, and the incision can be completely closed.

When from some difficulties or accident in technique the parts involved in the operation have been soiled it is a good plan to introduce a drain for thirty-six or forty-eight hours by the side of the gall-bladder. The immediate results of this operation are admirable.

There are certain *sequelæ* to cholecystotomy. Of these the chief are:

(a) Troublesome sinus, due to the sutures used to retain the gall-bladder to the abdominal incision.

(b) Dragging pain, due to the strain of the gall-bladder on its sutures.

(c) Recurrence of gall-stones (see p. 239).

(d) The occurrence of carcinoma in these septic gall-bladders.

(e) A persistent fistula. This sequel, however, is only likely to arise when inexperienced operators overlook a stone in the cystic or in the common duct.

Cholecystectomy.—This signifies an operation for the removal of the gall-bladder, with or without a portion of the cystic duct.

The indications and advantages of this operation are given on p. 198. It is performed for cholecystitis, calculous or otherwise, injuries to the gall-bladder, primary cancer of the gall-bladder, calculus impacted in the cystic duct, and in cases of contracted gall-bladder containing gall-stones.

The gall-bladder is exposed through the usual incision, and after a thorough examination of the bile-duct to be sure there is no obstruction to the free flow of bile, the peritoneum, which binds the gall-bladder to the under surface of the liver, is divided in the long axis of the gall-bladder and reflected to each side. This enables the surgeon to enucleate the gall-bladder from the recess in which it lies, and follow it towards the portal fissure where it joins the cystic duct. This duct is carefully examined, and any impacted stone is gently squeezed into the gall-bladder, or if tightly impacted it is left in the duct, and this structure is seized with forceps beyond the calculus—that is, nearer the main duct. The detachment of the gall-bladder in this way is accompanied by some oozing from the liver,

but the only vessel of any importance divided in this procedure is the artery of the gall-bladder (cystic branch from the hepatic artery).

In dealing with the neck of the gall-bladder in this operation I have tried three methods :

(1) In cases where the gall-bladder is enlarged secondary to the impaction of a stone in the cystic duct, the neck of the gall-bladder with the vessels may be secured with a silk ligature passed around it by means of an aneurysm needle and then tied; the gall-bladder is then detached above the ligature. The disadvantage of this method is the uncertainty of securing the cystic duct, and if this is dilated the needle may transfix it, and the ligature in these circumstances will be useless.

(2) When the surgeon has freed the gall-bladder from its connection with the liver, then with forceps he picks away the softer tissues around the neck of the gall-bladder and the cystic duct until it is clearly exposed. With forceps he can seize the cystic duct and divide it in such a way as to leave a convenient piece suitable for the application of a thin silk ligature; the cystic artery can then be tied or squeezed with forceps.

(3) The last method consists in detaching the gall-bladder from the liver and dividing its neck near the cystic duct and leaving the duct without a ligature. Any vessel that bleeds freely is ligatured or squeezed in the usual way. This mode is particularly indicated

when the gall-bladder contains pus or is acutely inflamed. A wide drain is inserted, and in the course of twenty-four hours the bile may be drained into a bottle. In the course of ten or twelve days the bile ceases to flow along the tube and the wound quickly

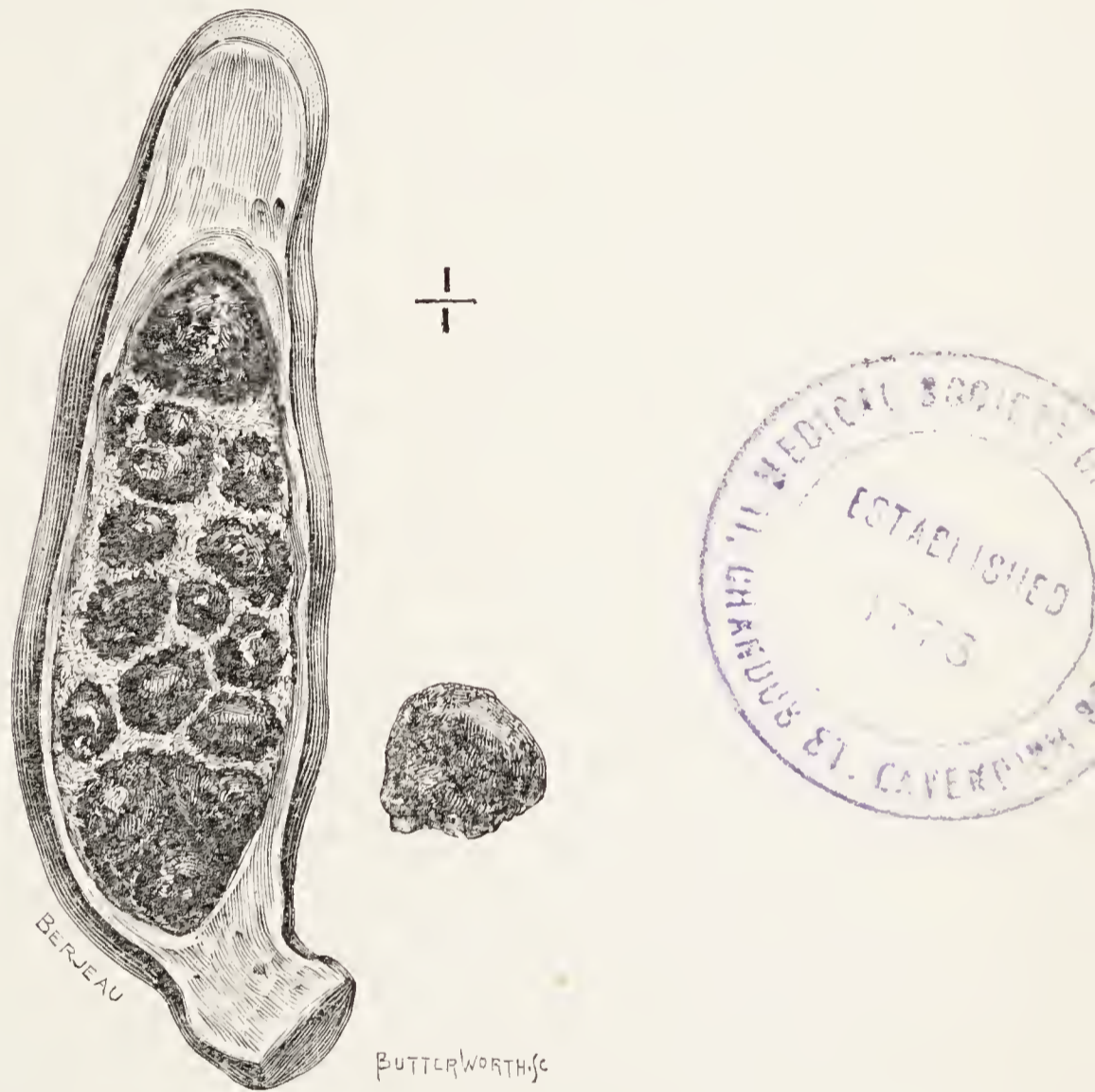

FIG. 53.—A calculous gall-bladder with contracted cystic duct. The large stone was removed from the common duct. The patient had suffered gall stone attacks for seventeen years.

heals. With this method the surgeon has no trouble with a suppurating fistula, and the patient is spared the tedium of daily dressings and watching for the appearance of a ligature.

There is one point worth attention especially in

removing a contracted gall-bladder like the one represented in Fig. 53. On one occasion when removing a gall-bladder, anxious to get well below its neck, I applied a silk ligature too low. Two days after the operation the patient was very jaundiced. On the third after the operation I then felt sure that my ligature had occluded the common duct. On re-opening the wound this proved to be the case. I cut away the ligature; in three days the jaundice disappeared and the patient recovered.

In the operation of cholecystectomy there is usually bleeding from parts of the liver along the line of detachment of the gall-bladder. This may be so free as to need a suture here and there to bring the oozing surfaces into apposition. Commonly, pressure from a dab wrung out of hot water arrests it. I have never had any trouble from this cause.

In the largely distended gall-bladder (hydrops vesicæ felleæ) a thin strip of atrophied liver sometimes spreads over the gall-bladder. This may be excised by means of two converging incisions, leaving a triangular patch of liver substance on the gall-bladder (cholecystectomy and partial hepatectomy), Fig. 23. The cut edges of the liver are drawn together by silk sutures, and the mutual pressure of the cut edges stops the bleeding.

The results of cholecystectomy have been in my hands excellent. In simple cases of mucocele I have had patients up and walking about twelve days after

the operation. In other conditions the convalescence depends on the drainage. Very septic cases may require five weeks, but in an ordinary way patients are out of bed in three weeks.

Cholecystenterostomy.—This operation, as its name implies, consists in effecting an anastomosis between the fundus of the gall-bladder and the intestine, either the duodenum or the colon.

The indication for this operation is permanent obstruction of the common bile-duct, which may be due to cancer of the common duct, or of the duodenum involving the bile-papilla, or of the head of the pancreas; and cicatricial stricture of the bile-duct. It has been performed for a stone firmly impacted in the cystic or in the common duct.

It is an operation which will in the future be rarely performed. It may be taken for granted that with the great improvements in the technique of operations for the removal of gall-stones from the duct there is practically no form of calculous obstruction to which the term "irremovable" is applicable.

In cancerous obstructions there are now and then conditions in which the patient's comfort may be promoted by an operation of this kind (see p. 145), and occasionally in impassable stricture of the main bile-duct, either antenatal or acquired. The operation can only be carried out when the gall-bladder is free.

The anastomosis may be made either to the duodenum or the colon near the hepatic flexure. The junction with the colon is the simplest, and consists in making an opening in the colon in a situation where the fundus of the gall-bladder can be brought in contact with it without undue tension. The opening in the colon and a corresponding opening in the fundus of the gall-bladder are united with thin silk sutures on the plan adopted in an ordinary gastro-jejunostomy or a lateral anastomosis of intestine.

Anastomosis with the duodenum is not satisfactory, because the opening in the gut is of necessity small and tends to contract and close rather quickly.

A free anastomotic opening with the colon is easily made and does not suffer quick obliteration, but some of the patients complain of a biliary diarrhœa, which is annoying as well as inconvenient. It is, however, preferable to a biliary fistula, which this particular operation is designed to obviate.

(4) **Cholecystendysis.**—In this operation the gall-bladder is opened and the calculi extracted. The incision in the gall-bladder is closed with sutures and returned into the abdomen.

(5) **Cysticotomy.**—This term is applied to an operation in which a stone is removed from the cystic duct through an incision in its wall. If the walls of the duct are healthy, some surgeons recommend the closure of the incision by suture; when

the duct is septic drainage should be employed. Cysticotomy I regard as a very unsatisfactory operation, and it is being rapidly replaced by cholecystectomy.

REFERENCES.

- Morison, Rutherford**, "The Anatomy of the Right Hypochondrium, with special reference to Operations for Gall-stones."
—*Brit. Med. Journ.*, 1894, ii, p. 968.
- Tait, Lawson**, "Case of Cholecystotomy performed for Dropsy of the Gall-bladder due to Impaction of a Gall-stone."
—*Med.-Chir. Trans.*, 1880, lxxiii, p. 17.

CHAPTER XVII

OPERATIONS ON THE COMMON BILE-DUCT

Choledochotomy.—This operation consists in localising and extracting gall-stones from the common duct.

(A) *Supraduodenal choledochotomy.*—The operation requires modification according to the position of the stone. When it lies in the supraduodenal portion of the duct—that is, the segment which lies in the free edge of the gastro-hepatic omentum—the proceeding is fairly simple. It is in operations upon the ducts that the “sandbag position” (p. 206) is of greater advantage than in the gall-bladder group.

The parts concerned are exposed in the same manner as for operations on the gall-bladder, and in many instances choledochotomy is performed as an extension of a cholecystotomy. The vertical part of the abdominal incision will need to be longer in order to afford free access to the duct which lies deep in the abdomen. It is also necessary to advise those who attempt these operations to remember that the relative position and size of these ducts look neat and simple in diagrams and coloured drawings,

but when the surgeon is dealing with them in real life they are imbedded in fat which accumulates around the porta hepatica and the margins of the gastro-hepatic omentum in close association with the portal vein, the vena cava, and large arteries.

After a complete exposure of the part the surgeon localises the stone, and, if possible, fixes it with the left thumb and forefinger, and then cautiously incises the duct longitudinally upon the gall-stone. Through this incision he gently squeezes the calculus and any other gall-stones he may detect either in the hepatic or duodenal section of the duct; then with a probe he carefully explores the duct in both directions and assures himself that they are free. Sometimes the duct is so dilated that the index finger may be introduced for the purpose of exploring the duct. The finger is a nature-probe which beats any made in the instrument-maker's workshop. It is important to bear in mind that the rule for success in these operations is to be sure and clear the duct. As soon as the obstruction is removed the bile flows freely into the wound.

After the oozing of blood is checked and any definite bleeding spot compressed or ligatured, a large rubber drain-tube is introduced and the abdominal wound closed.

Some surgeons recommend the closure of the wound in the bile-duct with sutures, taking care that they only traverse the muscular coat of the

duct. Others introduce a rubber-drain directly into the duct and secure it with sutures.

Every surgeon follows the results acquired by experience. My first gall-stone operation was performed in 1891. I found stones in the supraduodenal portion of the common duct, and without any previous experience to guide me I cut through the duct and extracted four gall-stones; there was another, but it slipped into the hepatic duct and could not be recovered. I introduced a large drain-tube and closed the wound. Very little bile escaped, and on the day after the operation the remaining stone came up the tube. This patient was in good health in 1906. The interest of the case is great to me because it was the second successful choledochotomy performed in England; Knowsley Thornton had the first success. When my case was reported to the Society it was urged that I ought to have sutured the duct, but I have performed many choledochotomies since that date with few failures and without suture of the duct. It is remarkable that an incision in the walls of this duct heals so quickly that it may occur without the least escape of bile along the drain-tube.

(B) *Retroduodenal choledochotomy.*—When the calculus is in the segment of the common duct which lies behind the second portion of the duodenum, attempts should be gently made to coax it into the supraduodenal portion of the duct; failing

this, it is necessary to incise the peritoneum a little to the right of the duodenum and then gently strip it up so as to free or mobilise the duodenum in such a way that the surgeon can obtain access to this portion of the duct, which is then incised and the calculus removed. The final stages are the same as in the supraduodenal operation, drainage, of course, being very essential.

(c) *Duodeno-choledochotomy*.—When a calculus is firmly impacted in the duodenal segment of the duct or in the ampulla, it is usual to endeavour to push it gently on into the duodenum or back into the first (supraduodenal) segment of the common duct. Occasionally careful effort of this kind meets with success. When it fails then access to this portion of the duct is obtained by a longitudinal incision through the wall of the duodenum. Care is taken to prevent soiling of the wound.

When the stone is lodged in the ampulla it will be seen protruding through the duodenal ostium when the papilla is exposed; the edges of the orifice are snipped with scissors or a knife sufficiently to allow the calculus to be squeezed out.

When the gall-stone is lodged in the terminal segment of the common duct it will form a bulging on the inner wall of the duodenum; this is incised and the stone squeezed through it. (This is Professor Kocher's *transduodenal choledochotomy*.) After carefully searching the duct with a probe, the

primary incision in the duodenum is closed with suture, but that made to release the stone from the duct or the ampulla will not require sutures.

The incision in the duodenum is closed in the following manner: The mucous membrane is brought into apposition by means of a continuous suture of fine silk. Then the muscular and serous layers are joined by a continuous suture of silk, and, thirdly, it is wise to make the junction more secure by inserting a few interrupted sutures of silk in the serous coat. After the operation a cautious surgeon will drain for forty-eight hours; an over-confident operator will close the abdominal incision without drainage, and he often meets with success.

Duodeno-choledochotomy is an interesting operation because the direct exposure of the papilla sometimes reveals to the surgeon that the obstruction is due to duodenal carcinoma and not to a gall-stone. Very rarely the surgeon finds the obstruction to be due to a pancreatic calculus in the ampullary portion of the pancreatic duct. Incision of the wall of the ampulla to release a calculus is useful as it enlarges the terminal orifices and facilitates the escape of overlooked concretions.

The remaining operations on the common duct are rarely performed. For example, choledodectomy, or excision of an occluded portion of the common duct, is not often required. Also choledoch-enterostomy or the anastomosis of a divided or a dilated

common duct with an adjacent section of the intestinal tract, is not often performed or required.

Segments of the common duct, including the papilla, have been exsected for malignant disease, and the duct above engrafted into the duodenum. In a few instances the patients have recovered from the operation, survived for a few months and died from recurrence (Halsted).

OPERATIONS ON THE HEPATIC DUCTS.

(A) **Hepaticotomy.**—This operation consists in the removal of a gall-stone from the hepatic duct.

It is rare that gall-stones are retained in the hepatic duct; in many instances in which the common duct contains calculi they will also be found in the hepatic duct. In such an event the gall-stones would be extracted through an incision in supraduodenal section of the duct, and those in the hepatic duct would be coaxed forwards and chased through the incision. It is rare that a solitary gall-stone is so impacted in the hepatic duct as to require an incision in this duct for its removal; but it has happened (Elliot).

(B) **Hepaticostomy.**—In some very rare instances the hepatic duct has become obstructed by gall-stones, and so dilated in consequence that it has resembled and been mistaken for a gall-bladder. Under such conditions it has been exposed, the

fluid evacuated, the gall-stones removed, and the opening in the dilated duct secured to the abdominal walls, the operator being under the impression that he was dealing with an enlarged gall-bladder.

OPERATIONS ON THE INTRAHEPATIC DUCTS.

(A) **Hepato-hepaticotomy.**—This cumbrous term signifies the removal of gall-stones from the intra-hepatic ducts through an incision in the liver-substance. Forbes Hawkes has recorded an operation of this kind (see p. 104). The liver was exposed by means of the usual incision, and on passing the hand over the dome of the right lobe of the liver the calculi were felt. As there were no adhesions gauze was packed between the liver and the diaphragm to promote their formation. Four days later the gauze was removed and the liver-tissue incised and three masses of gall-stones extracted. Drainage was employed on account of free bleeding; the patient recovered.

(B) **Hepato-cholangio-enterostomy.**—This is an operation first successfully performed by Kehr, and its employment is restricted to cases in which the common or the hepatic ducts are strictured or obliterated, and the gall-bladder is shrunken or in such a condition that it will not permit of an anastomosis with intestine (cholecystenterostomy). In such circumstances, in order to relieve the jaun-

dice, an incision, or a raw surface is made in the liver so as to expose bile-ducts, and a piece of jejunum is opened and sutured to the raw surface of the liver, or to the edge of the incision. This permits bile to drain into the jejunum or the first part of the duodenum.

Maylard, in reporting a case of this operation, corroborates the experience of Kehr that the exposure of the raw surface of the liver to the interior of the intestinal canal is not followed by fever or any indication of septic disturbance (see also Michels).

REFERENCES.

- Bland-Sutton, J.**, "A Case of Cholelithiasis ; Removal of Impacted Gall-stones through an Incision in the Common Duct ; Recovery."—*Clin. Soc. Trans.*, 1892, xxv, p. 161.
- Fullerton, A.**, "Anastomosis between the Common Bile-duct and the Duodenum for Obstructive Jaundice."—*Brit. Med. Journ.*, 1907, ii, p. 1118.
- Kocher, Dr. Th.**—*Text-book of Operative Surgery*, translated by Harold J. Stiles, 1903, p. 230.
- Maylard, A. E.**, "Hepato-cholangio-jejunostomy for Complete Cicatricial Obstruction to the Hepatic and Common Ducts."—*Annals of Surgery*, 1905, xli, p. 56.
- Thornton, J. Knowsley**, "Observations on additional Cases illustrating Hepatic Surgery."—*Med. Soc. Trans.*, 1891, xiv, p. 295.

CHAPTER XVIII

AFTER-TREATMENT, RISKS, AND SEQUELÆ OF GALL-STONE OPERATIONS

After-treatment.—This is conducted on the same lines as after other forms of abdominal operations. The patient is returned to bed with gentleness and a pillow placed under the knees. No hot-water bottles should be allowed in bed until the complete return of consciousness.

At the end of an hour it is useful to administer half a pint of normal saline solution (1 dr. of salt to one pint of water) by the rectum, and if there be much shock $\frac{1}{2}$ oz. of brandy may be added. The saline solution without brandy may be repeated every two or three hours, according to the condition of the patient. Morphia is, as a rule, strongly contra-indicated unless there is much restlessness and excitement; then the hypodermic use of a quarter of a grain is extremely useful, and may require to be repeated.

During the eighteen hours following the operation nothing is given by the mouth, but the patient is

allowed to wash the mouth out frequently with hot or cold water according to fancy. At the end of this time small quantities of hot water may be taken, but if vomiting occurs the administration of fluids by the mouth should be stopped and the saline enemata resumed. As soon as vomiting ceases then beef-tea and similar things may be taken by the mouth. It is a rule with me never to allow solids to be taken until the bowels have been freely opened: this usually occurs on the third or fourth day, as the result of an enema or an ounce of castor-oil. When flatulent distension of the colon is troublesome it may be relieved by a turpentine enema early on the second day after an operation. It is useful to encourage the patient to be propped up in bed a few days after operation to avoid engorgement of the lungs.

In cases where drainage is employed and there is free escape of bile, the careful management of the tube and receiving bottle will do much to keep the patient comfortable and prevent the dressings and the bed from being soaked with bile.

Risks and sequelæ.—As in all abdominal operations, those performed for the relief of gall-stones are attended with certain risks. The chief of these are shock, sepsis, hæmorrhage, injury to viscera, foreign bodies left in the abdomen, parotitis, thrombosis and embolism, and pulmonary complications. Each will be briefly considered.

Shock.—All abdominal operations of any magnitude are liable to be followed by the peculiar physical disturbance known as shock; but operations on the bile-ducts, especially if prolonged, are often followed by severe shock, and I think this may in a measure result from injury to the cœliac plexus as well as to the rich nerve-plexus which surrounds the blood-vessels and ducts lying in the gastro-hepatic omentum.

As a rule the symptoms pass away in a few hours under the influence of saline solution administered by the bowel, but if it persists and deepens it may end fatally in thirty-six hours. A careful perusal of published records of gall-stone operations will serve to show that dangerous and fatal shock occurs frequently. In many operations the degree of shock stands in direct relation to the loss of blood, but gall-stone operations are rarely attended with profuse bleeding such as is sometimes seen in pelvic operations.

Sepsis.—A very large proportion of the operations performed on the gall-bladder and ducts are for conditions the outcome of septic infection, and it follows that in dealing with them every precaution must be taken to prevent soiling of the parts around the field of operation, and, as has so frequently been stated in this work, drainage is particularly necessary. In spite, however, of every care general infection of the peritoneum is a definite risk in this class of operation.

Another source of sepsis is unrecognised injury to adjacent intestine.

Subphrenic abscess.—An intraperitoneal collection of pus may be associated with perforative cholecystitis and cholangitis; when the pus is evacuated and sufficient drainage is not provided, or not maintained long enough, the pus reaccumulates and gives rise to the signs and symptoms of a subphrenic abscess. The appropriate treatment depends mainly on the recognition of the disease and the establishment of free drainage.

Hepatic abscess.—Gall-stones in the main duct, especially the hepatic and intrahepatic duct, are often associated with an abscess in the liver. It has happened that the surgeon, after removing stones from the main ducts, finds that his operation has not been followed by an improvement in the patient's condition, but the fever and pain continue. In some of these cases an hepatic abscess has been overlooked.

Foreign bodies.—In operations on the abdomen there is always great risk of dabs, gauze, or forceps being left in the abdomen. It should be borne in mind that the responsibility for this rests with the operator. When things of this kind are left in the abdomen the risk is not so great now as in pre-antiseptic days, when such accidents usually had a fatal termination; but even in aseptic operations such oversights have very unsatisfactory sequences

and necessitate the reopening of the wound for their removal, the formation of pus and sinuses, not to mention additional anxiety to the patient's relations and the possibility of an action at law.

The only way to avoid these things is to always work with a definite number of dabs and instruments, which the surgeon should himself count immediately before and after the operation (p. 204).

Hæmorrhage.—Operations on patients with obstructive jaundice, especially if it be of long standing, are liable to be complicated with troublesome oozing or free bleeding. I have rarely had trouble from this cause except in cases of obstructive jaundice due to primary cancer of the head of the pancreas; in this disease the oozing may be uncontrollable, and the patient bleeds to death in the same manner as after splenectomy performed for leukæmic spleen.

Lung complications.—Many patients who are submitted to operations for gall-stones and their complications have passed the meridian of life, and suffer from bronchitis and emphysema as well as chronic renal conditions. Such patients are liable to suffer from bronchitis or pneumonia as a direct consequence of the administration of an anæsthetic. In some cases these gravely imperil life and require skilful nursing to bring the patient safely along the road to convalescence.

Parotitis.—Septic parotitis, or, as it is sometimes called, symptomatic or secondary parotitis, to dis-

tinguish it from mumps, is an occasional sequel of operations, and although it sometimes occurs after operations which run an afebrile course, the conditions underlying it are mainly septic in character. Septic parotitis is distinguished from mumps by the following points :

It occurs as a complication of some other infection in itself non-contagious and occasionally suppurates. There are two views held in regard to its ætiology : some hold that it is due to direct infection of the duct (Stenson's) of the parotid by microorganisms from the mouth, while others maintain that the path of infection is mainly by the blood-stream.

Two able investigations have recently been published in regard to this condition, in which one writer (Bucknall) supports the view that it is an ascending infection from the mouth ; and the other (Tebbs) brings forward evidence that the elements of infection reach it by the blood-stream.

Both writers agree that this disease, when it complicates post-operative convalescence, is almost entirely confined to septic cases.

Many of the operations performed on the gall-bladder and its ducts are required for the results of septic infection, and septic parotitis is an occasional sequel ; it may occur within two days of the operation or as late as the thirtieth day. It is more common between the sixth and tenth days, and its

advent is accompanied by much disturbance. The parotid swells and becomes painful and tender; the skin over it is red and often brawny. These signs are accompanied by fever, malaise, and depression of spirits. In mild cases they subside in a few days, but in severe cases rigors occur, with high fever and suppuration.

The mild cases are best treated with warm fomentations, frequently changed. If suppuration occurs, the pus will need to be evacuated by a scalpel, but incisions in a suppurating parotid gland need to be carried out with careful regard to the branches of the facial nerve (*pes anserinus*) and the large vessels intimately associated with it.

The surgeon need not be in a great hurry to use the scalpel in these cases, for it seems occasionally as if the skin would ulcerate, and yet when it is incised no pus escapes. This septic parotitis is very deceptive in this respect both in the red and brawny appearance of the skin covering the swollen gland and the misleading sense of fluctuation. In many instances the inflammatory products escape by way of the parotid ducts.

Septic parotitis is an unpleasant and painful complication of an abdominal operation, but it is rarely dangerous, and has only had a fatal termination in very exceptional cases.

Vascular complications.—These are not common, but they occasionally arise in the form of thrombosis of

the vein in the lower limb, especially when varicose.

Pulmonary embolism is a rare sequel. I have met with it once in fifteen years, and other writers who have published contributions to this class of surgery mention it. Such a complication is very alarming and not necessarily fatal. My solitary case recovered. Death may arise from causes which complicate other operations, especially when their existence is unsuspected either from latency in the symptoms or from lack of foresight on the part of the surgeon. Occasionally urgent operations have been performed in spite of the existence of a serious complicating disease—such, for example, as cirrhosis of the liver, granular kidneys, diabetes, chronic cardiac disease, or valvular incompetency, chronic pancreatitis, and even acute yellow atrophy of the liver.

Sinus.—The persistence of a fistula after operation on the gall-bladder and its ducts may signify that a stone has been left in the cystic or common duct; or it may be due to a ligature or a suture.

Sinuses after these operations are less frequent than formerly, especially as routine cholecystotomy is being supplanted by cholecystectomy (see p. 216).

Recrudescence of gall-stones.—Recurrence of gall-stones after operation has been reported on several occasions, but when the facts are critically examined it would appear that in most cases the stones were overlooked at the primary operation. In my own

experience there has been one case of recrudescence after operation. It has also been clearly proved that gall-stones may form around sutures used to secure the gall-bladder to the parietal wound (p. 60).

Yielding cicatrix.—Hernia of the scar is not so common, nor so troublesome in scars made in the rectus abdominis muscle as those made in the abdominal wall below the level of the navel. Yielding of the scar is much more common when the wound is infected in the course of an operation than in those which heal aseptically.

Tetanus.—This dread sequel to a gall-stone operation occurred as late as 1905 ; it was traced to catgut ligatures.

Cancer of the gall-bladder after cholecystotomy.—It was pointed out in discussing primary cancer of the gall-bladder that this disease is in 95 per cent. of cases complicated with gall-stones ; it would, therefore, be expected that in some instances cancer might be expected to arise in the damaged and infected gall-bladders left after cholecystotomy.

Lawford Knaggs performed cholecystotomy on a woman aged sixty-nine years. She died fifteen months later with cancer of the gall-bladder (Moynihan).

In 1906 Mr. Jonathan Hutchinson performed cholecystotomy for gall-stones on a woman aged thirty-seven years. She came under observation again in 1908, twenty-one months after the primary

operation, with columnar-celled carcinoma of the gall-bladder (Lett).

REFERENCES.

- Bucknall, R.**, "The Pathology and Prevention of Secondary Parotitis (with Literature)."—*Med.-Chir. Trans.*, 1905, lxxxviii, p. 1.
- Tebbs, B. N.**, "Symptomatic Parotitis."—*Med.-Chir. Trans.*, lxxxviii, p. 35.
- Moynihan, B. G. A.**—*Gall-stones and their Surgical Treatment*, 2nd edit., 1905.
- Robson, A. W. Mayo, and Dobson, J. F.**—*Diseases of the Gall-bladder and Bile-ducts*, London, 1904.
- Kehr, H.**—*Technik der Gallensteinoperationen*, München, 1905.
- Kehr, H.**, "Die Hepato-cholangio-enterostomie."—*Zentralblatt für Chirurgie*, 1904, xxxi, p. 185.
- Lett, H.**, "Two Unusual Conditions of the Gall-bladder."—*Lancet*, 1909, i, 1099.

CHAPTER XIX

INJURIES OF THE GALL-BLADDER AND BILE-DUCTS

INJURIES of the gall-bladder and the main bile-ducts apart from severe injuries of the liver are uncommon. Like injuries of the liver, they are caused by severe abdominal contusions or localised injuries, such as a blow from the pole of a van, or the buffer of a railway carriage. Blows from a fist, or the foot of a man or a horse, crushes such as result from being run over by wheeled vehicles are also common causes. Falls from a height, especially if in falling the body strikes on a prominent object like a beam, or the top of a wall, lead to injury of the gall-bladder or the common bile-duct. Other important causes of injury are bullets and cutting instruments, such as a knife, dagger, stiletto and the like.

It is rare to get an uncomplicated wound of the gall-bladder, or the great ducts, for these structures are closely hemmed in by adjacent viscera such as the stomach, duodenum and colon, which lie in

intimate relation with the liver. The "excretory apparatus of the liver" is often damaged in association with gross injuries of the body, many of which are quickly fatal, but it does happen from time to time in dealing with a serious abdominal injury the surgeon will find, among other grave injuries, that he has to deal with a lesion of the gall-bladder or the bile-ducts, accompanied by an escape of bile into the belly. Moreover, some of the cases furnish a clinical picture of some interest.

When the bile-ducts or the gall-bladder are injured without any gross injury of the neighbouring organs, there is shock, vomiting, tenderness of the abdomen, and a rapid pulse. In the course of a few days the patient may be jaundiced, the stools colourless, and the abdomen becomes distended with fluid.

If there be no co-existent infection of the bile-ducts, the mere accumulation of bile in the abdomen will not set up peritonitis. Should there be any injury to the intestine then acute peritonitis would be quickly established.

In order to show how the peritoneum tolerates bile, reference may be made to a case reported by Arbuthnot Lane: A lad, aged eighteen years, received a blow in the abdomen from the pole of a van; he suffered pain for a fortnight, and then seemed in a fair way to recover. Four weeks later the patient's abdomen was greatly distended, and he appeared to be very ill. The abdomen was opened

by a median subumbilical incision and three gallons of bile drained away. Subsequently it was necessary to open and drain a collection of bile in the right hypochondrium. The boy eventually recovered.

On two occasions I have removed a gallon of bile from the peritoneal cavity. One was a case in which a gall-bladder contained nearly a hundred calculi, and was burst by a fall. The bile was evacuated, the gall-stones were picked off the omentum; there were no signs of peritonitis. The patient, an elderly fat woman, succumbed to broncho-pneumonia six weeks after the operation.

The second patient was a girl, aged seventeen years, who had been submitted to choledochotomy; the bile which leaked from the hole in the duct did not freely escape through the drainage-tube. Three weeks after the operation I evacuated four pints of inspissated bile, which had accumulated in the right hypochondrium. The girl recovered. In these instances the bile which had been slowly accumulating did not give rise to peritonitis, and satisfied me that the peritoneum tolerates healthy bile.

The mode of treating injuries to the gall-bladder can scarcely be doubtful when it is the result of a penetrating wound, because it is a recognised practice among surgeons to-day that wounds of this kind demand prompt treatment by cœliotomy. If, in the course of the investigations made during the operation, the surgeon finds a damaged gall-bladder, he

acts in the patient's best interests by removing it, and if there be other viscera damaged, the removal of the gall-bladder will only be regarded as an incident.

The difficult cases are those in which a patient has sustained severe internal injuries by a fall, or from being run over, badly crushed, or some similar injury, and comes under observation when he is in such a serious condition of shock that immediate operative interference is inadvisable. When the shock passes off the patient sometimes rallies so well that there is nothing to cause the surgeon to suspect that any particular viscus has been injured. Later an effusion gradually manifests itself in the belly, and the fæces are colourless. In these circumstances an operation becomes necessary, and on opening the abdomen, if the effusion be found to consist of bile, a careful exploration of the excretory apparatus of the liver is made and the nature of the lesion determined. On the character of the injury must depend the form of treatment; thus a hole in the gall-bladder has been sutured with success, but cholecystectomy would be safer. A hole in the common bile-duct may be sutured, but it could be treated with drainage and allowed to close without suture. If the common duct be completely divided an attempt might be made to join the cut ends by suture, or even to secure the proximal end of the duct into the duodenum. This is an important matter; otherwise

the patient would have the discomfort of a persistent biliary fistula.

Experience teaches that in the treatment of injuries of the gall-bladder or the main bile-ducts, simple measures are followed by better results than elaborate attempts to restore the continuity of injured ducts.

REFERENCES.

- Battle, W. H.**, "Traumatic Rupture of the Common Bile-duct."—*Clin. Soc. Trans.*, 1894, xxvii, 144.
- Cotte, G.**, "Traitement Chirurgical des Traumatismes des Voies biliaires."—*Revue de Gynecol. et de Chir.*, Ab. 1908, xii, 425.
- Coukand**, "Plaies de la Vésicule biliaire."—*Revue de Chirurgie*, 1907, 294.
- Lane, W. A.**, "Rupture of a Gall-bladder."—*Lancet*, 1891, i, 1091.
- Terrier, F., and Auvray, M.**—*Chirurgie du foie et des Voies biliares* Paris, 1901.

CHAPTER XX

THE MORTALITY OF OPERATIONS PERFORMED FOR THE RELIEF OF GALL-STONE DISEASE

THE risk to life involved in these operations varies enormously with the conditions which require relief and the experience of the surgeon who performs them.

Operation for the relief of gall-stone disease is a new thing, dating from 1876, when Lawson Tait removed gall-stones with success from the gall-bladder (cholecystotomy) of a woman aged thirty-seven years.

The latest contribution to this important matter we owe to Dr. William J. Mayo, who with his brother at Rochester, Minnesota, has performed fifteen hundred operations for cholelithiasis (*Annals of Surgery*, August, 1906).

Among these operations there were—

	Number.	Died.
Cholecystotomies .	845	19
Cholecystectomies .	319	10
Choledochotomies .	195	23

These are the results of very experienced surgeons and, of course, represent the consequences at their very best. They serve to show that these operations

are attended, even on these figures, with a serious risk to life. The risk in less experienced hands is, of course, much greater, for it may be compared with the results of a crack rifleman shooting at the target and those of an average soldier.

In order to obtain some notion of the average risk among surgeons generally, I issued a circular to the surgical registrars of the chief hospitals in London and obtained from them a statistical account of the gall-stone operations performed during the year 1905. The results are valuable, for they give some idea of the number of operations of this kind performed in London and the relative liability of the various parts of the excretory apparatus of the liver to disease as well as the mortality.

As these operations were performed by many surgeons we are able to form some idea of the results of inexperience as well as experience in this difficult class of surgery, performed upon all sorts and conditions of men and women. From this we are also able to strike a mean risk without that disturbing and deceptive factor "personal bias" when individual surgeons publish their own statistics.

As a result of my circular letter I received replies from the following hospitals relating exclusively to the year 1905: St. Bartholomew's, Guy's, London, Middlesex, University College, Great Northern, Charing Cross, Westminster, St. Thomas's, St. George's, King's College, and St. Mary's.

THE MORTALITY OF OPERATIONS 249

For comparison with these I obtained a similar report from the General Infirmary, Leeds, and the Royal Victoria Infirmary, Newcastle-on-Tyne. The greatest number of operations performed in any of the above-mentioned institutions during 1905 for cholelithiasis was at the London Hospital (fifty-four in all).

OPERATIONS PERFORMED IN THE CHIEF HOSPITALS IN LONDON FOR THE RELIEF OF GALL-STONES DURING 1905.

	Number.	Died.
Cholecystotomy . . .	105	16
Cholecystectomy . . .	51	9
Cholecystendysis*	3	0
Choledochotomy . . .	20	6
Cholecystenterostomy . . .	4	2
Intestinal obstruction from gall-stones . . .	2	1

OPERATIONS PERFORMED IN THE GENERAL INFIRMARY, LEEDS, FOR THE RELIEF OF GALL-STONES DURING 1905.

	Number.	Died.
Cholecystotomy . . .	19	1
Cholecystectomy . . .	20	4
Choledochotomy . . .	7	2
Intestinal obstruction from gall-stone . . .	1	1

* St. Mary's Hospital.

250 DISEASES OF THE BILE-DUCTS

OPERATIONS PERFORMED AT THE ROYAL VICTORIA
INFIRMARY, NEWCASTLE-ON-TYNE, FOR THE RELIEF
of GALL-STONES DURING 1905.

	Number.	Died.
Cholecystotomy . . .	26	4*
Cholecystectomy . . .	4	0
Choledochotomy . . .	8	2

* One died from tetanus.

THIS TABLE REPRESENTS THE CHARACTER AND RESULTS
OF THE LAST FIFTY-ONE CONSECUTIVE OPERATIONS
FOR GALL-STONES PERFORMED BY THE AUTHOR.

	Number.	Died
Cholecystotomy . . .	17	2
Cholecystectomy . . .	24	2
Cysticotomy . . .	3	2
Choledochotomy . . .	5	0
Cholecystenterostomy . . .	1	0
Gall-stone ileus . . .	1	0

INDEX.

Abscess—

- biliary, 99
- hepatic, 100, 104
- subphrenic, 101, 218
- actinomycosis of gall-bladder, 36

Adenoma—

- hepatic, 131

Ampulla—

- anatomy of, 8
- cancer of, 143
- operations on, 227
- gall-stones in, 97
- variations in, 9

Aneurysm—

- intrahepatic, 38
- of hepatic artery, 37
- operations on, 38
- symptoms of, 39

Appendix—

- gall-stones in, 87

Bile—

- characters of, 12
- composition of, 13
- discharge of, 14
- functions of, 14
- infection of, 23
- secretion of, 14
- tests for, 14

Bile canaliculi, 2

Bile canals, 2

Biliary colic, 166, 183

Bile-duct—

- common, 7
- cystic, 7
- hepatic, 3
- intrahepatic, 2

Bile-ducts—

- anatomy of, 3
- cancer of, 141
- casts of, 54
- dilatation of, 48
- infection of (see *Cholangitis*)
- intrahepatic, 2, 102
- obliteration of (congenital), 41
- obstruction of, 96
- operations on, 224
- rupture of echinococcus cysts into, 126
- stricture of, 25

Biliary fistulæ—

- cholecysto-duodenal, 113
- cysto-colic, 80, 109
- cysto-duodenal, 80, 108
- cysto-gastric, 80
- external, 85
- formation of, 80
- internal, 82

Bilirubin, characters and tests,
13

Bilirubin-calcium, 52

Cancer—

- of ampulla, 143
- of bile-ducts, 130, 141
- of common duct, 141
- of duodenum, 144
- of gall-bladder (primary), 131,
240
- of gall-bladder (secondary), 132
- of hepatic duct, 141
- of intrahepatic ducts, 130
- of pancreas, 154

Chalk—

- in gall-stones, 54

Cholangitis—

- acute, 24
- calculus, 90
- subacute, 24
- suppurative, 27
- tuberculous, 28

Cholecystitis—

- actinomycotic, 36
- acute, 174
- calculous, 67
- gangrenous, 32, 34
- membranous, 34
- obliterans, 36
- pathology of, 29
- suppurative, 31
- tuberculous, 37
- typhoid, 21, 57
- ulcerative, 34

Choledocho-duodenal fistula, 94

Cholelithiasis—

- (see *Gall-stones*)
- irregular, 181

Cholelithiasis (*continued*)—
regular, 180

Cholesterin—

- characters of, 13
- in gall-stones, 50
- tests for, 13

Common bile-duct—

- anatomy of, 7
- cancer of, 141
- dilatation of, 46
- obliteration of, 26, 41
- occlusion of, 25
- operations on, 224
- stones in, 91
- stricture of, 26, 43

Congenital obliteration of bile-
ducts, 41

Courvoisier's law, 96

Cystic duct—

- anatomy of, 7
- fistulæ, 80
- obliteration of, 27, 41
- occlusion of, 77
- operation on, 222
- stones in, 77
- valves of, 5

Cysts—

- multiple, of liver, 121
- solitary, of liver, 122
- echinococcus, of liver, 126

Diverticulum—

- of gall-bladder, 74
- of Vater (see *Ampulla*)

Duodenum—

- cancer of, 144
- fistulæ, 94, 107
- imperforate, 45

Empyema of gall-bladder, 31

Gall-bladder—

- actinomycosis of, 36
- anatomy of, 6
- absence of, 11
- anomalies of, 11
- axial rotation of, 75
- calcification of, 36
- cancer of, 131
- diverticula of, 74
- empyema of, 31
- fistulæ, 80
- gangrene of, 34
- hour-glass, 12, 72
- hydrops of, 69
- infections of (see *Cholecystitis*)
- in hernia, 175
- injuries of, 242
- operations on, 213
- perforation, 28, 83
- papilloma of, 136
- sclerosis of, 36, 177
- sloughing of, 34
- typhoid infection of, 17
- ulceration of, 34

Gmelin's test, 14

Gall-stone ileus—

- causes of, 108
- clinical characters of, 115
- treatment, 118

Gall-stones—

- ball-valve action of, 92
- cancer and, 133
- changes in, 64
- classification of, 50
- composition of, 50
- diagnosis of, 182
- diagnostic localisation, 178
- encapsulation of, 73
- experimental production, 57
- facetting of, 61

Gall-stones (continued)—

- formation of, 64
- fracture of, 76
- in ampulla, 97, 153
- in appendix, 87
- in colon, 109
- in common duct, 90
- in cystic duct, 77
- in diverticula, 74
- in fæces, 172
- in gall-bladder, 67
- in hepatic duct, 101
- in infants, 48
- in intestine, 107
- in intrahepatic ducts, 102
- in Meckelian diverticulum, 86
- in peritoneal cavity, 81
- in stomach, 82
- in urinary tract, 87
- in vermiform appendix, 87
- micro-organisms in, 56
- nucleus of, 34
- origin of, 55
- recrudescence, 60, 239
- results of, 67
- skiagraphy of, 180
- symptoms, 165
- treatment of, 192

General cystic disease of liver,
121

Hepatic abscess, 235

Hepatic artery—

- aneurysm of, 37
- erosion, 38

Hepatic duct—

- anatomy of, 4
- cancer of, 141
- dilatation of, 101

Hepatic duct (*continued*)—

- operations on, 229
- stones in, 101
- stricture of, 26
- suppuration in, 102
- ulceration of, 102

Hydrops vesicæ felleæ, 31, 69

Intermitting hydrops, 71

Intestinal obstruction—

(see *Gall-stone ileus*) 107

Intra-hepatic ducts—

- anatomy of, 2
- cancer of, 141
- casts of, 105
- dilatation of, 122
- stones in, 102

Islands (of Langerhans), 155

Jaundice (*icterus*)—

- and wandering spleen, 162
- black, 159
- catarrhal, 24
- causes of, 186
- fæces in, 171
- hæmorrhage, 173
- obstructive, 186, 187
- of pancreatic cancer, 158
- of hepatic cancer, 159
- pruritus, 170, 195
- toxæmic, 157
- unobstructive, 187
- urine in, 171
- with cholethiasis, 168
- yellow vision in, 186

Liver—

- abscess of, 235
- adenoma of, 131

Liver (*continued*)—

- cancer of, 131
- cysts of, 121
- hydatids of, 126
- linguiform lobe, 175
- Riedel's lobe, 173, 176

Micro-organisms—

- in bile, 23
- in biliary abscess, 100
- in cholangitis, 23
 - B. typhosus*, 17
 - tubercle bacillus, 28
- in cholecystitis, 32, 54
 - B. coli communis*, 32
 - B. typhosus*, 17
 - pneumococcus, 32
 - streptococcus, 32
- in gall-stones 56
 - B. coli communis*, 57
 - B. typhosus*, 57
- in pancreatitis, 151
- in parotitis, 237

Mucocœle, 31, 61

Obliteration of excretory apparatus of liver, 41

Operations—

- cholangiostomy, intra-hepatic, 145, 230
- cholecystectomy, 217
- cholecystendysis, 222
- cholecystenterostomy, 221
- cholecystotomy, 213
- choledochoduodenostomy, 212
- choledochotomy, 224
- cysticotomy, 222
- duodeno-choledochotomy, 227
- hepaticostomy, 229
- hepaticotomy, 229

Operations (*continued*)—

- hepato-cholangio-enterostomy, 230
- hepato-hepaticotomy, 230
- retroduodenal-choledochotomy, 226
- supra-duodenal-choledochotomy, 224
- transduodenal-choledochotomy, 227
- after-treatment, 232
- anæsthesia, 205
- cancer, 240
- contra-indications, 199
- dabs, 203
- drainage, 210
- foreign bodies, 235
- gloves, 204
- hæmorrhage, 236
- hepatic abscess, 235
- hernia, 240
- incision, 207
- instruments, 203
- lung complications, 236
- mortality, 247
- parotitis, 236
- position of patient, 206
- preparation of patient, 201
- recrudescence, 60, 239
- risks, 233
- sepsis, 234
- sequelæ, 233
- shock, 234
- sinus, 239
- subphrenic abscess, 235
- suture, 209
- tetanus, 240
- thrombosis, 238
- vascular complications, 238
- yielding cicatrix, 240

Pancreas—

- anatomy of, 149
- calculi in, 152
- cancer of, 154
- cysts of, 152
- duct of, 151
- histology, 155
- infections (see *Pancreatitis*)
- tumours of, 154

Pancreatitis—

- causes, 151
- chronic, 152
- effects, 154
- pathology, 151
- Pancreatic lithiasis, 152
- Papilloma of gall-bladder, 136
- Pericholecystitis, 185
- Porta hepatica, 10
- Pylephlebitis, 28
- Pyloric obstruction from gall-stones, 114

Riedel's lobe, 175, 176

Skiagraphy in cholelithiasis, 180

Spleen, wandering, 162

Stomach—

- fistula of, 80
- Subphrenic abscess, 235

Typhoid—

- carriers, 19
- cholecystitis, 21
- infection of gall-bladder, 17
- ulceration of gall-bladder, 18

Ulceration of Gall-bladder—

- from gall-stones, 34
- in typhoid fever, 17

Valves (of Heister), 7

Yater (diverticulum of), 8

cancer of, 143

stones in, 97, 153

Vermiform appendix—

gall-stones in, 87

Wandering gall-bladder, 76

Wandering spleen, 162

Xanthopsia (in jaundice), 186

X rays in diagnosis of gall-stones
180



